



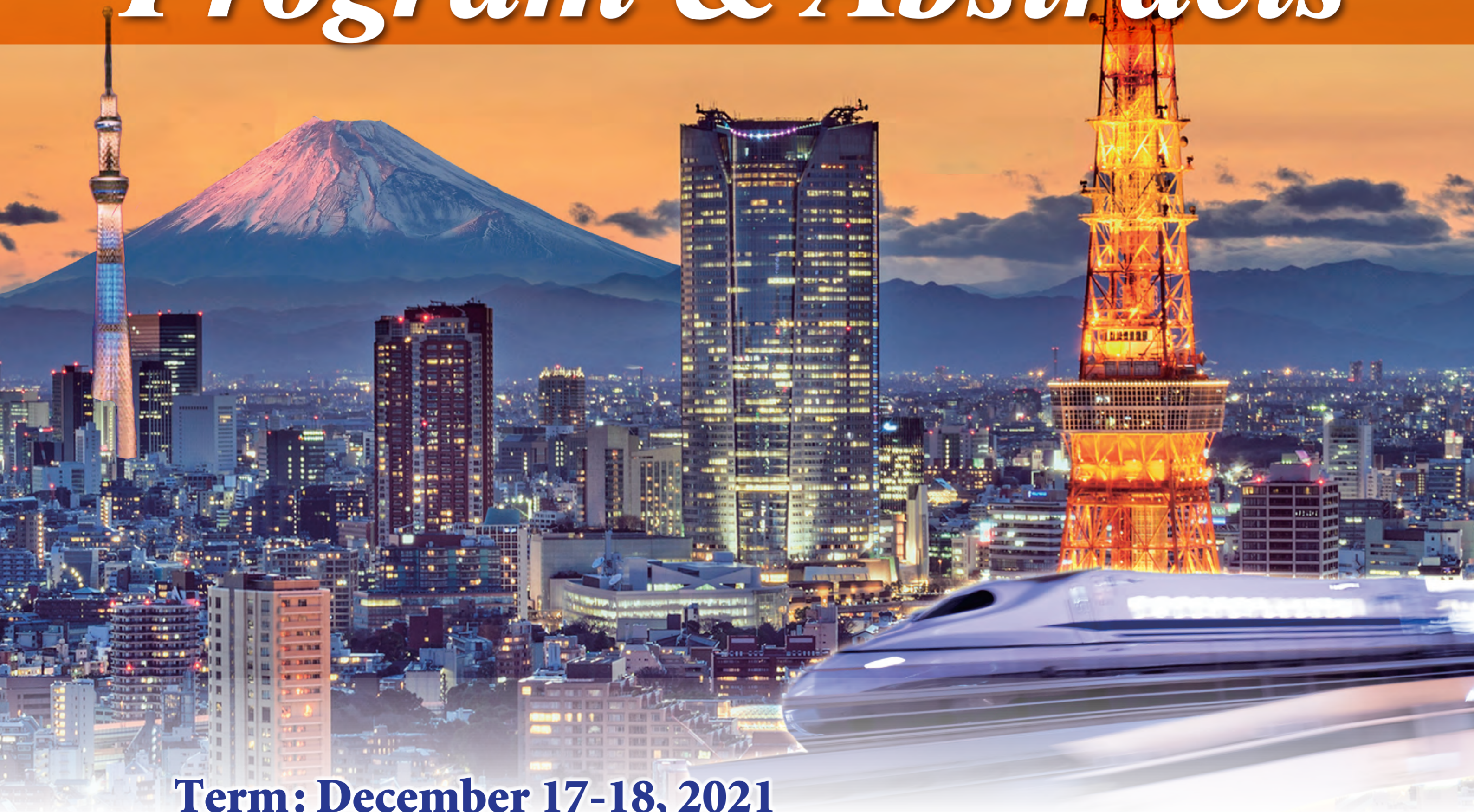The Asian Pacific Association for the Study of the Liver



APASL Oncology 2021

*“Your Gateway to Oncology
in Asia-Pacific Region”*

Program & Abstracts



Term: December 17-18, 2021

City: Tokyo, Japan (Hybrid Meeting)

Onsite-Venue: The Prince Park Tower Tokyo

President: Mitsuhiko Moriyama, M.D.

Professor and Chairman,
Division of Gastroenterology and Hepatology,
Department of Internal Medicine,
Nihon University School of Medicine



APASL Oncology 2021 in Tokyo

“Your Gateway to Oncology in Asia-Pacific Region”

Hybrid Meeting (Onsite-Venue: The Prince Park Tower Tokyo)

December 17-18, 2021

Table of Contents

Welcome Message

Invited Guest Speakers / Chairs

Organizing Committee

Conference Information

On-Site Venue

Instruction for Oral Presentation

Instruction for Chairs

Instruction for Poster Presentation

Awards / Contact

Sponsors and Support Organization

Program at a Glance

Scientific Program

Abstracts: General Sessions

Abstracts: Sponsored Seminars

Abstracts: Oral Free Papers

Abstracts: Poster Free Papers

Welcome Message



Dear Colleagues,

It gives us great pleasure to welcome you to the Asian Pacific Association for the Study of the Liver APASL Oncology 2021.

Never in the history of humankind should we now be more united in our efforts to confront a common deadly enemy - COVID-19. To win this war for the human race, we need knowledge from all fronts, to be united in our critical thinking and experiences. So far, tremendous effort has been exercised to control new human transmission.

To this end, we APASL have organized frequent APASL Hepatology Webinars since last year and are webcasting those high-quality educational webinars through our official “APASL Cast” with a large number of registrants.

On the other side, as the new series of the APASL official meeting; Annual meeting and Single topic conferences with a variety of topics, the “APASL Oncology” meeting has been launched from this year, and this event marks the memorable 1st conference of “APASL Oncology” in Tokyo (hybrid-style meeting) focusing particularly on the study of “Hepatic Oncology”. We anticipate active discussion with experts in various field to enlighten us on the most recent Asia-Pacific data in epidemiology, diagnostics, treatment, and all of “Oncology”.

We look forward to your participation!

Yours sincerely,

A handwritten signature in black ink that reads "M. Omata".

Masao Omata M.D.
Honorary President, APASL Oncology 2021 Tokyo
Steering Committee of APASL
Professor Emeritus, The University of Tokyo
President, Yamanashi Central and Kita Hospitals

Welcome Message



Dear Colleagues,

On behalf of the Organizing Committee, we would like to welcome you to the Asian Pacific Association for the Study of the Liver APASL Oncology 2021, which will be held on December 17-18 2021 in Tokyo, Japan as a hybrid-style meeting.

This conference had originally been scheduled for December 2020; however, it was rescheduled because of the COVID-19 pandemic. We deeply appreciate your understanding and cooperation.

The scientific program will consist of invited lectures, plenary sessions, symposia, and free papers on significant developments on the theme of “Your Gateway to Oncology in the Asia-Pacific Region”. The program will also provide the latest information and fresh ideas for hepatologists and oncologists in this area.

We have accepted all categories of Hepatology and Oncology abstracts, including case reports.

We appreciate your submission of abstracts and anticipate a large number of attendants, which will stimulate active discussions.

APASL Oncology 2021 will combine the physical event at The Prince Park Tower Tokyo, Japan in the Centre of Tokyo, with a Virtual Meeting platform for a unique experience bringing both the in-person and virtual community together. Webcast video presentations will be connected with physical presentations and sessions including virtual interactions, live commentary, online chat and discussion.

A delegation of experts from all over the world is expected to attend this conference. We are sure that this will provide an excellent opportunity for those of us in the Asian Pacific region to share the latest views, values, experience, and practice, and greatly contribute to this field.

We are looking forward to seeing you soon in Tokyo or through the online webinar.

With warmest regards,

A handwritten signature in black ink that reads "Mitsuhiko Moriyama". The signature is written in a cursive, flowing style.

Mitsuhiko Moriyama, M.D.

President, APASL Oncology 2021 Tokyo

Professor and Chairman, Division of Gastroenterology and Hepatology
Department of Internal Medicine, Nihon University School of Medicine

Invited Guest Speakers/Chairs/Scientific Committee

Invited Guest Speakers/Chairs/Scientific Committee from Overseas

Dr. Oidov Baatarkhuu (Mongolia)	Dr. Seth J. Karp (USA)	Dr. Gamal Shiha (Egypt)
Dr. Pei Jer Chen (Taiwan)	Dr. Do Young Kim (Korea)	Dr. Simone Strasser (Australia)
Dr. Ann-Lii Cheng (Taiwan)	Dr. George Lau (China)	Dr. Pil Soo Sung (Korea)
Dr. Wan Long Chuang (Taiwan)	Dr. Cosmas R.A. Lesmana (Indonesia)	Dr. Tung-Hung Su (Taiwan)
Dr. Massimo Colombo (Italy)	Dr. Chun-Jen Liu (Taiwan)	Dr. Tawesak Tanwandee (Thailand)
Dr. Levent Doğanay (Turkey)	Dr. Mamun-AlMahtab (Bangladesh)	Dr. Arndt Vogel (Germany)
Dr. A. Kadir Dokmeci (Turkey)	Dr. Rakhi Maiwall (India)	Dr. Lai Wei (China)
Dr. Rino Gani (Indonesia)	Dr. Necati Örmeci (Turkey)	Dr. Jin Mo Yang (Korea)
Dr. Hasmik Ghazinyan (Armenia)	Dr. Young Nyun Park (Korea)	Dr. Thomas Yau (China)
Dr. Saeed Hamid (Pakistan)	Dr. Diana A. Payawal (Philippines)	Dr. Wei-Peng Yong (Singapore)
Dr. Jee-Fu Huang (Taiwan)	Dr. Teerha Piratvisuth (Thailand)	Dr. Changhoon Yoo (Korea)
Dr. Chiun Hsu (Taiwan)	Dr. Ranjit Ray (USA)	Dr. Hong You (China)
Dr. Washim Jafri (Pakistan)	Dr. Ratna B. Ray (USA)	Dr. Min-Lung Yu (Taiwan)
Dr. Ji Dong Jia (China)	Dr. Shiv Kumar Sarin (India)	Dr. Man-Fung Yuen (China)
Dr. Jia-Horng Kao (Taiwan)	Dr. Manoj K. Sharma (India)	

In alphabetical order

Invited Guest Speakers/Chairs/ Scientific Committee from Japan

Dr. Hiroyuki Aburatani	Dr. Tatsuya Kanto	Dr. Kazunari Murakami
Dr. Shinichi Aishima	Dr. Hiroaki Kanzaki	Dr. Takamichi Murakami
Dr. Norio Akuta	Dr. Mureo Kasahara	Dr. Akihito Nagahara
Dr. Jun Arai	Dr. Naoya Kato	Dr. Hidenari Nagai
Dr. Yoshinari Asaoka	Dr. Norifumi Kawada	Dr. Yuko Nagaoki
Dr. Kazuaki Chayama	Dr. Takumi Kawaguchi	Dr. Sumiko Nagoshi
Dr. Tetsuhiro Chiba	Dr. Yusuke Kawamura	Dr. Hidewaki Nakagawa
Dr. Hirayuki Enomoto	Dr. Kazufumi Kobayashi	Dr. Nobuhiro Nakamoto
Dr. Kenichi Harada	Dr. Takahiro Kodama	Dr. Naoshi Nishida
Dr. Kiyoshi Hasegawa	Dr. Atsumasa Komori	Dr. Shuhei Nishiguchi
Dr. Etsuro Hatano	Dr. Mina Komuta	Dr. Takuto Nosaka
Dr. Yoichi Hiasa	Dr. Yasuteru Kondo	Dr. Kazuhiro Nouse
Dr. Hayato Hikita	Dr. Keisuke Koroki	Dr. Shuntaro Obi
Dr. Atsushi Hiraoka	Dr. Masatoshi Kudo	Dr. Sadahisa Ogasawara
Dr. Yosuke Hirotsu	Dr. Masayuki Kurosaki	Dr. Masahiro Ogawa
Dr. Masao Honda	Dr. Shinya Maekawa	Dr. Takamasa Ohki
Dr. Hiroko Iijima	Dr. Hitoshi Maruyama	Dr. Masayuki Ohtsuka
Dr. Yuji Iimuro	Dr. Tsutomu Masaki	Dr. Yukiyasu Okamura
Dr. Masafumi Ikeda	Dr. Ryota Masuzaki	Dr. Hironao Okubo
Dr. Sadakatsu Ikeda	Dr. Naoki Matsumoto	Dr. Masao Omata
Dr. Fumio Imazeki	Dr. Yutaka Midorikawa	Dr. Motoyuki Otsuka
Dr. Hiroo Imazu	Dr. Toshio Miki	Dr. Issei Saeki
Dr. Hideki Iwamoto	Dr. Masashi Mizokami	Dr. Michiie Sakamoto
Dr. Namiki Izumi	Dr. Eishiro Mizukoshi	Dr. Naoya Sakamoto
Dr. Kenya Kamimura	Dr. Satoshi Mochida	Dr. Reina Sasaki
Dr. Tatsuo Kanda	Dr. Naoki Morimoto	Dr. Shinpei Sato
Dr. Shuichi Kaneko	Dr. Mitsuhiko Moriyama	Dr. Shuichiro Shiina

Dr. Masahito Shimizu	Dr. Ryosuke Tateishi	Dr. Tatsuya Yamashita
Dr. Masaya Sugiyama	Dr. Katsutoshi Tokushige	Dr. Shintaro Yamazaki
Dr. Fumitaka Suzuki	Dr. Takuji Torimura	Dr. Yutaka Yasui
Dr. Shinichi Takahashi	Dr. Hidenori Toyoda	Dr. Hiroshi Yatsuhashi
Dr. Tadatoshi Takayama	Dr. Kaoru Tuchiya	Dr. Osamu Yokosuka
Dr. Haruhiko Takeda	Dr. Yoshiyuki Ueno	Dr. Hideo Yoshida
Dr. Tetsuo Takehara	Dr. Kazuomi Ueshima	Dr. Hitoshi Yoshiji
Dr. Junko Tanaka	Dr. Takeji Umemura	Dr. Sachiyo Yoshio
Dr. Shinji Tanaka	Dr. Yoshiyuki Wada	Dr. Hiroshi Yotsuyanagi
Dr. Yasuhito Tanaka	Dr. Takuya Yamagishi	
Dr. Makiko Taniai	Dr. Taro Yamashita	

In alphabetical order

Organizing Committee

Local Organizing Committee

Honorary President: Dr. Masao Omata	Treasurer: Dr. Fumio Imazeki
President: Dr. Mitsuhiro Moriyama	Vice-Treasurer: Dr. Shunichi Matsuoka
Vice-President: Dr. Tadatoshi Takayama	Vice-Treasurer: Dr. Masahiro Ogawa
Secretary General: Dr. Tatsuo Kanda	Vice-Secretary General: Dr. Ryota Masuzaki

APASL Steering Committee

Chairman of Steering Committee:	Dr. Shiv Kumar Sarin (India)
President:	Dr. Jin Mo Yang (Korea)
Immediate Past President:	Dr. Tawesak Tanwandee (Thailand)
President Elect:	Dr. Han-Chieh Lin (Taiwan)
Secretary General-cum-Treasurer:	Dr. Manoj K Sharma (India)
Past Presidents:	
Dr. Laurentius A. Lesmana (Indonesia)	Dr. Darrell Crawford (Australia)
Dr. Jose Sollano (Philippines)	Dr. A. Kadir Dokmeci (Turkey)
Dr. Masao Omata (Japan)	Dr. Osamu Yokosuka (Japan)
Dr. Dong Jin Suh (Korea)	Dr. Jinlin Hou (China)
Dr. George Lau (China)	Dr. Barjesh Chander Sharma (India)
Dr. Ji Dong Jia (China)	Dr. Diana A. Payawal (Philippines)
Dr. Teerha Piratvisuth (Thailand)	Dr. Rino Gani (Indonesia)
Dr. Jia-Horng Kao (Taiwan)	

APASL Executive Council

Assistant Secretary:	Dr. Hong You (China)
Executive Councils:	
Dr. Gulnara Aghayeva (Azerbaijan)	Dr. Simone Strasser (Australia)
Dr. Chun-Jen Liu (Taiwan)	Dr. Yaman Tokat (Turkey)
Dr. Mamun-Al-Mahtab (Bangladesh)	Dr. Yoshiyuki Ueno (Japan)
Dr. Rakhi Maiwall (India)	

Conference Information

Registration Fee and Category

	Pre-Registration until Dec. 10, 2021	On Site
APASL Member*	JPY 25,000	JPY 30,000
	Online: JPY 15,000	Online: JPY 15,000
Non-Member	JPY 35,000	JPY 40,000
	Online: JPY 15,000	Online: JPY 15,000
Trainee / Resident**	JPY 20,000	JPY 20,000
	Online: JPY 15,000	Online: JPY 15,000
Accepted Abstract Submitter	JPY 10,000	JPY 10,000
	Online: JPY 10,000	Online: JPY 10,000
Accompanying Person	JPY 5,000	JPY 5,000

JPY=Japanese Yen

*APASL Members who have paid 2021 Membership Fee can apply for discounted registration fee.

*Registration for viewing of On-demand Presentation is available until January 20th 2022.

Online Participation (Style: Zoom Webinar)

- The conference program will be presented as a hybrid style meeting.
- Attendants are able to enter the webinar through Zoom <https://zoom.us/join> with the ID and Password of which they have been informed by the conference secretariat. * For Speakers/Chairs, the secretariat sends an individual invitation link to enter the webinar.
- The lectures will be delivered live or by recorded video. After the presentation, the discussion (Q&A) time will be held according to the moderator's instructions. Online viewers are able to send textual questions to the Q&A column, and the onsite participants may ask questions using the microphone in the conference room. We anticipate your active discussions.
- After the conference term, the recorded lectures and discussion will be distributed on-demand from the presentation page of APASL Oncology 2021 Website <http://www.apasl-oncology2021.org/>
The viewing period of the on-demand presentation is scheduled to be from December 20, 2021 through January 20, 2022. The secretariat will receive the questions by e-mail during the on-demand delivery period and will forward them to each speaker.

[Precautions]

- The organizer cannot handle problems such as computer operation, internet connection, video and audio connection. Please solve such problems by yourself. We recommend the following environment.
 - We would appreciate it if you could use a PC with as much memory as possible (CPU i5 or more, memory 8 Giga or more).
 - Please connect to the Internet via a wired LAN line as much as possible.
- To transfer or share the ID and password, recording of screens and images is strictly prohibited.
- The internet fee at this online conference will be borne by each attendant.
We cordially solicit your understanding and cooperation.

Onsite Registration/PC Pre-view Hours

December 17 (Friday) 7:30-19:30 (JST)

December 18 (Saturday) 7:30-16:00 (JST)

Onsite-Venue

The Prince Park Tower Tokyo

Address: 4-8-1 Shibakoen Minato, Tokyo 105-8563 Japan

Tel: +81-(0)3-5400-1111

URL: <http://www.princehotels.com/parktower/>



Location: [From Haneda Airport]

By Train: About 35 minutes to Daimon Station of Toei Subway Asakusa Line (via Keikyu Airport Line and Keikyu Line, Toei Subway Asakusa Line)

By Monorail: About 20 minutes by Tokyo Monorail to Hamamatsucho Station

By Car: About 15 minutes by taxi during normal hours (taking toll road, via Shibakoen Ramp)

[From Nearest Stations]

From Akabanebashi Station of Toei Subway Oedo Line: about 2 minutes on foot

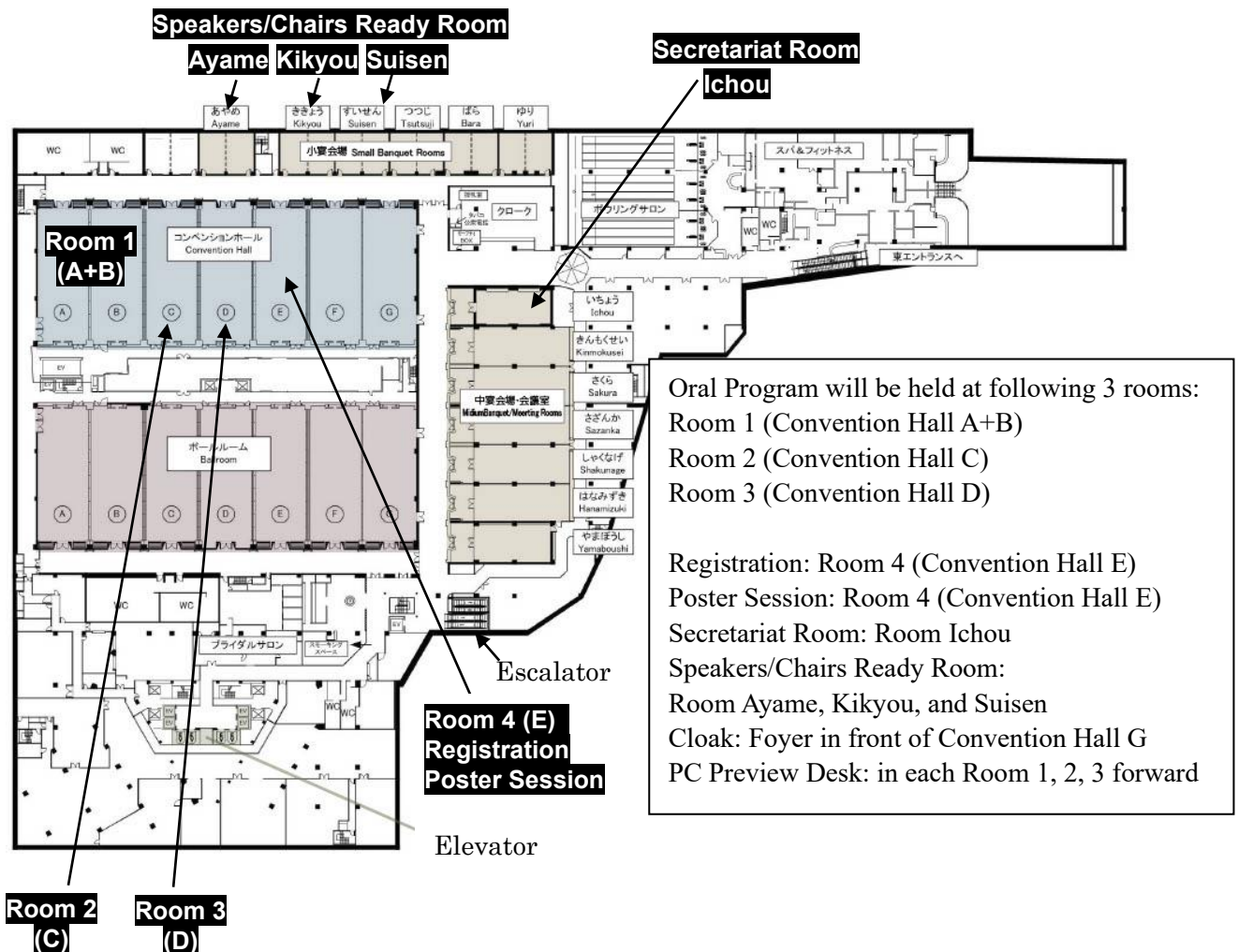
From Shibakoen Station of Toei Subway Mita Line: about 3 minutes on foot

From Daimon Station of Toei Subway Asakusa Line/ Toei Subway Oedo Line: about 9 minutes on foot

From Hamamatsucho Station of JR Line/Tokyo Monorail: about 12 minutes on foot

From Kamiyacho Station of Tokyo Metro Subway Hibiya Line: about 12 minutes on foot

Floor Plan: B2F, The Prince Park Tower Tokyo



Instruction for Oral Presentation

The conference program will be presented as a hybrid style meeting.

- An invitation email containing information about the login will be sent to the presenters/moderators through the Zoom system. The login URL will be included in the invitation email.
- We would appreciate it if you could conduct a test connection ahead of the conference.
- The general sessions' presentation time is 15 minutes. The Oral Free Paper is 7 minutes (5 minutes presentation, 2 minutes discussion).
- After presentation, the discussion time (a question-and-answer session) will be held according to the moderator's instructions.

[For those who will participate at the onsite venue]

- Please complete your registration of presentation data at the Data Pre-View Desk until 1 hour before your presentation time.
- Please be seated at the "next speaker's seat" at least 10 minutes before your presentation. The seat will be located forward near the podium.
- The slides which you have submitted in advance for the presentation are prepared on the computer of the podium. Please operate the slides by yourself. Please note that the presenter tool is not available.
-

[For those who will attend online]

- Please join Zoom at least 20 minutes before your session begins.
- Please turn on the microphone and the camera only when you are speaking.
- The moderator will introduce the presenter at the beginning of each presentation.
- Then, the secretariat will start the presentation video. (In principle, you do not have to share your presentation by yourself.)
- After finishing the presentation, online viewers will send textual questions to the Q & A column, so please follow the moderator's instructions and answer those questions.
- The following environment is recommended.
 - Create the image resolution in XGA (1024 x 768).
 - Microsoft PowerPoint (2010-2016) can be used as the application software.
 - The fonts that come standard with Microsoft PowerPoint, Times, Arial are recommended.

[Precautions]

- Do not post, modify, distribute or reproduce copyrighted material, trademarks, portrait rights or other property rights in any way without the prior written consent of the owners of these property rights.
- Regarding citations, please specify the source of the citation.
- Please exert caution regarding the protection of personal information such as name, age, surgery date, etc. This could lead to the identification of an individual.

Instruction for Chairs

The conference program will be presented as a hybrid style meeting.

- An invitation email that contains information about the login will be sent to the presenters/moderators through the Zoom system. The login URL will be included in the invitation email.
- At the real time webinar, the recorded lecture will be presented, and speakers/chairs are requested to join the discussion time. The presentation and Q & A session will be delivered live.
- The general oral presentation time is 15 minutes. The Oral Free Paper is 7 minutes (5 minutes presentation, 2 minutes discussion).
- After presentation, the discussion time (a question-and-answer session) will be held according to the moderator's instructions. The online viewer will send questions in the Q & A column. The onsite participants will ask questions using the microphone at the conference hall.
- After the conference, the recorded video will be posted on the on-demand presentation page.

[For Chairs who will participate at the onsite conference venue]

Please be seated at the "next chair's seat" at least 10 minutes before the session will start. The seat will be located forward near the stage.

[For Chairs who will attend online]

- Please join Zoom at least 20 minutes before your session begins.
- Please turn on the microphone and the camera only when you are speaking. Please mute the microphone otherwise.
- Please introduce the presenter at the beginning of each presentation. Then, the secretariat will start the presentation video, or the speaker will start his/her presentation on-site.
- After finishing the presentation, please turn on the microphone and camera again. Online viewers will send textual questions to the Q&A column, and the onsite participants will ask questions using the microphone in the conference room. So please convey those questions and moderate the discussion.
- The following environment is recommended.
 - Create the image resolution in XGA (1024 x 768).
 - Microsoft PowerPoint (2010-2016) can be used as the application software.
 - The fonts that come standard with Microsoft PowerPoint, Times, Arial are recommended.

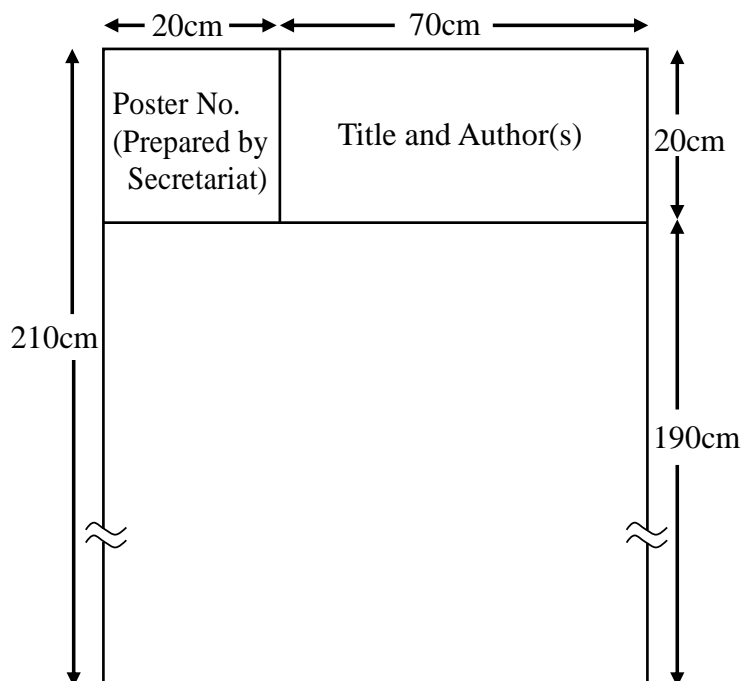
Instruction for On-Site Poster Presentation

[About presentation style]

- A panel width 90cm×length 210cm will be provided for each poster as following sample.
- Poster number will be prepared by secretariat.
- Title and author's name are required to be prepared by each presenter.
- Pins for display will be provided at each poster panel.
- Location: Poster Session will be located in (or foyer of) the Room 4, B2 Floor, The Prince Park Tower Tokyo.
- Schedule: On-site Poster Presentation is scheduled as follows.

Poster Attachment:	7:30-11:00 on December 17 (Friday)
Poster Presentation:	13:40-14:20 on December 18 (Saturday)
Poster Removal:	16:00-17:30 on December 18 (Saturday)
- Presentation Time: 5 minutes (3 minutes presentation; 2 minutes discussion) for each presentation.
- For those who have not removed posters until above removal time, please accept that the secretariat will discard any posters that have remained.
- Awarding Ceremony: The Awardees will be presented at the Closing Ceremony during 17:40-17:50 on December 18 (Saturday).

Poster Panel



Instruction for E-Poster Presentation

[About presentation style]

The conference program will be presented as a hybrid style meeting.

The poster presenters who are not able to attend physically to the conference venue, are requested to present as the E-Poster.

- The E-Poster session will be available through APASL Oncology 2021 Website from the conference term at <http://www.apasl-oncology2021.org>
- After the conference, the presentation will be posted on the on-demand presentation page.
- Please send your presentation (PowerPoint File 4:3) in advance to the secretariat as follows.
- Microsoft PowerPoint (2010-2016) can be used as the application software.
- File size is limited to 20 MB.
- The number of PPT slides is limited to 15 slides including the title and COI slides.
- Requested PowerPoint size is 4: 3.
- Awarding Ceremony: The Awardees will be presented at the Closing Ceremony during 17:40-17:50 on December 18 (Saturday).

[Precautions]

- Do not post, modify, distribute, or reproduce copyrighted material, trademarks, portrait rights, or other property rights in any way without the prior written consent of the owners of these property rights.
- Regarding citations, please specify the source of the citation.
- Please exert caution regarding the protection of personal information such as name, age, surgery date, etc. This could lead to the identification of an individual.
- Please pay particular attention to images that may be considered problematic when viewed by the public at this conference.

If you have any questions, please contact the secretariat below.

Contact: APASL Oncology 2021 Tokyo Congress Secretariat
c/o Academia Support Japan

Email: info@apasl-oncology2021.org

Tel: +81-3-6380-0102 Fax: +81-3-6380-0103

URL <http://www.apasl-oncology2021.org>

Awards

Excellent papers will be awarded as “Presidential Award” or “Young Investigator Award”.

Awarding Ceremony: The Awardees of Free Papers will be presented at the Closing Ceremony during 17:40-17:50 (Japan Standard Time) on December 18 (Saturday).

Presidential Award

“APASL Oncology 2021 Presidential Award” will be awarded to whom performed the most excellent presentation in APASL Oncology 2021 to encourage to further their research and progress.

Young Investigator Award (Under 40 years old)

The purpose of the “APASL Oncology 2021 Young Investigator Award” is to praise outstanding examples of excellence amongst those involved in research training in the early stages of their career.

Contact

APASL Oncology 2021 Scientific Secretariat

Division of Gastroenterology and Hepatology

Department of Internal Medicine, Nihon University School of Medicine

APASL Oncology 2021 Congress Secretariat

c/o Academia Support Japan

Email: info@apasl-oncology2021.org

Tel: +81-3-6380-0102 Fax: +81-3-6380-0103

APASL Central Office (APASL Secretariat-Tokyo)

Asian Pacific Association for the Study of the Liver [APASL]

1-24-7-920, Shinjuku, Shinjuku-ku, Tokyo, 160-0022 Japan


Email: apasl_secretariat@apasl.info

Tel: +81-3-5312-7686 Fax: +81-3-5312-7687

Sponsors and Support Organization

The Organizing Committee of the APASL Oncology 2021 Tokyo would like to express sincere gratitude to the following sponsors and organizations for supporting this conference.

Diamond Sponsor



Chugai Pharmaceutical Co., Ltd.

Platinum Sponsor



AbbVie GK

Gold Sponsors



Eisai Co., Ltd.



Incyte Biosciences Japan GK



Miyarisan Pharmaceutical Co., Ltd.



MSD K.K.



Sysmex Corporation

Silver Sponsors

AstraZeneca	Otsuka Pharmaceutical Co., Ltd.
Gilead Sciences K.K.	Takeda Pharmaceutical Co., Ltd.
Mitsubishi Tanabe Pharma Corporation	Towa Pharmaceutical Co., Ltd.

Mitsuwadai General Hospital

In alphabetical order

Bronze Sponsors

Akiru Municipal Medical Center	Mikuni Naika-Ganka Clinic
Ando Hospital Medical Corporation	Mochida Pharmaceutical Co., Ltd.
Asahi Kasei Pharma Corporation	Mylan EPD G.K.
ASKA Pharmaceutical Co., Ltd.	NexusAgent.inc
Astellas Pharma Inc.	Niiza Shiki Central General Hospital
Bayer Yakuhin, Ltd.	Nippon Boehringer Ingelheim Co., Ltd.
Canon Medical Systems	Nobelpharma Co., Ltd.
Chikuma Central Hospital	Nonakatokokai Seifuso Hospital
Cytori Therapeutics Inc.	Philips Japan, Ltd.
Daiichi Sankyo Co., Ltd.	Shino-Test Corporation
Dainippon Sumitomo Pharma Co., Ltd.	Stryker Japan K.K.
Eli Lilly Japan K.K.	Syoutokukai Sekishindo Hospital
Honda R&D Co., Ltd.	Terumo Corporation
Inogashira Corporation	TKP Medicalink Corporation
Janssen Pharmaceutical K.K.	Tokyo Health Service Association
Medikit Co., Ltd.	ZERIA Pharmaceutical Co., Ltd.

In alphabetical order

Support Organizations

Alumni Association, Nihon University School of Medicine

The Japan Society of Hepatology

Tokyo Convention & Visitors Bureau

The Uehara Memorial Foundation

In alphabetical order

Program at a Glance

Day 1: December 17 (Friday) 2021

Day 1 (December 17 Friday) 2021					
Time (JST)	Room 1 (A+B)	Room 2 (C)	Room 3 (D)	Room 4 (E)	Web
7:50	Opening Ceremony				
8:00	8:00-9:00 Morning Seminar (1) (Chugai Pharmaceutical Co., Ltd.)	8:00-9:00 Morning Seminar (2) (Otsuka Pharmaceutical Co., Ltd.)		Poster Set up	E-Poster Presentation
9:00					
10:00	9:10-10:40 Session 1 Molecular Mechanism of HCC (1)	9:05-10:50 Session 6 Surgery and Transplantation	9:10-10:06 Oral Free Papers (1)	Poster Viewing	
11:00					
12:00	10:50-12:20 Session 2 Intermediate-stage HCC (1)	11:00-12:30 Session 7 HCC in Asia, Epidemiology (1)			
13:00	12:30-13:30 Luncheon Seminar (1) (Chugai Pharmaceutical Co., Ltd.)	12:40-13:40 Luncheon Seminar (2) (Sysmex Co., Ltd.)	12:30-13:30 Luncheon Seminar (3) (Eisai Co., Ltd. / MSD K.K.)		
14:00	13:40-14:20 President Lecture (Towa Pharmaceutical Co., Ltd.)				
15:00	14:30-16:00 Session 3 Intermediate-stage HCC (2)	14:30-16:00 Session 8 HCC in Asia, Epidemiology (2)	14:30-15:30 Educational Seminar (1) (Miyarisan Pharmaceutical Co., Ltd.)		
16:00			15:40-16:50 Oral Free Papers (2)		
17:00	16:10-17:40 Session 4 Pathology of HCC	16:10-17:40 Session 9 Management of HCC and Complications during TKI Treatment			
18:00	17:50-19:20 Session 5 Oncoimmunotherapy for HCC	17:50-19:20 Session 10 HCC after SVR			
19:00					
20:00	19:30-20:30 Evening Seminar (Incyte Biosciences Japan GK)				
22:30		20:00-22:30 APASL Hepatology Webinar "Editor's Choice" collaborated with AASLD			

Program at a Glance

Day 2: December 18 (Saturday) 2021

Time (JST)	Day 2 (December 18 Saturday) 2021					
	Room 1 (A+B)	Room 2 (C)	Room 3 (D)	Room 4 (E)	Web	
8:00	8:00-9:00 Morning Seminar (3) (Mitsubishi Tanabe Pharma Corporation)	8:00-9:00 Morning Seminar (4) (Takeda Pharmaceutical Co., Ltd.)	8:00-9:00 Morning Seminar (5) (AstraZeneca)	Poster Viewing	E-Poster Presentation	
9:00						
10:00	9:10-10:40 Session 11 Molecular Mechanism of HCC (2)	9:10-10:40 Session 15 COVID-19 in Japan	9:10-10:40 Oral Free Papers (3)			
11:00						
12:00	10:50-12:20 Session 12 HAIC, TACE, RFA, Radiation	10:50-12:20 Session 16 Diagnosis of HCC	11:00-12:00 Educational Seminar (2) (AbbVie GK)			
13:00	12:30-13:30 Luncheon Seminar (4) (AbbVie GK)	12:30-13:30 Luncheon Seminar (5) (Gilead Sciences K.K.)				
14:00						
15:00	14:30-16:00 Session 13 Intermediate-stage HCC (3)	14:30-16:00 Session 17 Intermediate-stage HCC (4)				13:40-14:20 Poster Presentation
16:00						Poster Viewing
17:00	16:10-17:40 Session 14 Intermediate-stage HCC (5)	16:10-17:40 Session 18 Intermediate-stage HCC (6)				Poster Removal
18:00	17:40-17:50 Awarding Ceremony					
	17:50-18:00 Closing Ceremony					

Scientific Program

Day 1: December 17 (Friday) 2021

Room 1

7:50-8:00 Opening Ceremony

Dr. Mitsuhiro Moriyama (President of APASL Oncology 2021)

8:00-9:00 Morning Seminar (1) (Sponsored by Chugai Pharmaceutical Co., Ltd.)

Chair: Dr. Masao Omata (Japan)

Toward Further Advancement of Molecular Targeted Therapy Using Liquid Biopsy in HCC

Dr. Sadakatsu Ikeda (Japan)

9:10-10:40 Session 1: Molecular Mechanism of HCC (1)

Chairs: Dr. Ranjit Ray (USA)/Dr. Naoshi Nishida (Japan)

9:10-9:25 1-1 **Risk Assessment of Hepatocellular Carcinoma Development-clinical and Molecular Perspective**

Dr. Ryota Masuzaki (Japan)

9:25-9:40 1-2 **Role of FGF19/FGFR4 Signaling and Potential of Serum FGF19 as a Biomarker in Hepatocellular Carcinoma**

Dr. Tetsuhiro Chiba (Japan)

9:40-9:55 1-3 **Accumulation of Molecular Aberrations Distinctive to Hepatocellular Carcinoma Progression**

Dr. Yutaka Midorikawa (Japan)

9:55-10:10 1-4 **Linking lncRNA Linc-Pint with Liver Disease**

Dr. Ratna B. Ray (USA)

10:10-10:25 1-5 **Genetic and Epigenetic Basis of Pediatric Liver Tumors**

Dr. Hiroyuki Aburatani (Japan)

10:25-10:40 Discussion Time

10:50-12:20 Session 2: Intermediate-stage HCC (1) (TKI, Lenvatinib)

Chairs: Dr. Tawesak Tanwandee (Thailand)/Dr. Masafumi Ikeda (Japan)

10:50-11:05 2-1 **Analysis for Transition of Molecular Target Agent Therapy and Prognosis in Advanced Hepatocellular Carcinoma**

Dr. Kazufumi Kobayashi (Japan)

11:05-11:20 2-2 **HCC Following Hepatitis C Virus Eradication**

Dr. Massimo Colombo (Italy)

11:20-11:35 2-3 **Integrating Systemic Therapy into Multidisciplinary Treatment of HCC**

Dr. Ann-Lii Cheng (Taiwan)

- 11:35-11:50 **2-4 Systemic Treatment Including Lenvatinib in Patients with BCLC-B Stage Hepatocellular Carcinoma**
Dr. Atsushi Hiraoka (Japan)
- 11:50-12:05 **2-5 Identification of Tumor Factors of Hepatocellular Carcinoma that Decrease the Efficacy of Immune Checkpoint Inhibitors**
Dr. Masao Honda (Japan)
- 12:05-12:20 Discussion Time

12:30-13:30 Luncheon Seminar (1) (Sponsored by Chugai Pharmaceutical Co., Ltd.)

Chair: Dr. Masatoshi Kudo (Japan)

Novel Cancer Immunotherapy for Hepatocellular Carcinoma: Evidence and Management

Dr. Masafumi Ikeda (Japan)

Exploring Next-Gen Systemic Therapy for HCC: What Have We Learned?

Dr. Ann-Lii Cheng (Taiwan)

13:40-14:20 President Lecture (Sponsored by Towa Pharmaceutical Co., Ltd.)

Chair: Dr. Masao Omata (Japan)

Considering the Occurrence of Liver Cancer from Chronic Hepatitis C / Cirrhosis in Japan

Dr. Mitsuhiko Moriyama (President of APASL Oncology 2021)

14:30-16:00 Session 3: Intermediate-stage HCC (2)

Chairs: Dr. George Lau (China)/Dr. Atsumasa Komori (Japan)/Dr. Tsutomu Masaki (Japan)

- 14:30-14:45 **3-1 Treatment Strategy for Intermediate Stage HCC**
Dr. Masafumi Ikeda (Japan)
- 14:45-15:00 **3-2 Paradigm Shift with Drug Therapy in the Treatment of Intermediate-Stage Hepatocellular Carcinoma**
Dr. Tatsuya Yamashita (Japan)
- 15:00-15:15 **3-3 Treatment Strategy for Intermediate Stage HCC with Consideration of Maintaining Liver Function**
Dr. Naoya Kato (Japan)
- 15:15-15:30 **3-4 Systemic Therapy in the Intermediate Stage HCC: Current Evidence and Future Perspective**
Dr. Changhoon Yoo (Korea)
- 15:30-15:45 **3-5 Treatment Strategy of Intermediate-stage HCC: ABC Conversion Therapy**
Dr. Masatoshi Kudo (Japan)
- 15:45-16:00 Discussion Time

16:10-17:40 Session 4: Pathology of HCC

Chairs: Dr. Shinichi Aishima (Japan)/Dr. Kenichi Harada (Japan)/Dr. Michiie Sakamoto (Japan)

- 16:10-16:25 **4-1 Tumour Heterogeneity of HCC and Its Clinical Relevance**
Dr. Mina Komuta (Japan)

16:25-16:40	4-2 Pathological Features of Tumor Microenvironment of HCC Dr. Michiie Sakamoto (Japan)
16:40-16:55	4-3 Genomic Structures and Carcinogenesis of HBV Integrations in Liver Cancer Dr. Hidewaki Nakagawa (Japan)
16:55-17:10	4-4 Update in HCC Pathology Dr. Young Nyun Park (Korea)
17:10-17:25	4-5 Morphological Subtypes of Hepatocellular Carcinoma Dr. Shinichi Aishima (Japan)
17:25-17:40	Discussion Time

17:50-19:20 Session 5: Oncoimmunotherapy for HCC

Chairs: Dr. Shiv K. Sarin (India)/Dr. Masao Omata (Japan)

17:50-18:05	5-1 Mechanism of Resistance to Immunotherapy for Hepatocellular Carcinoma Dr. Kazuomi Ueshima (Japan)
18:05-18:20	5-2 Dramatic Transformation of Treatments in Patients with Advanced Hepatocellular Carcinoma Dr. Sadahisa Ogasawara (Japan)
18:20-18:35	5-3 Oncoimmunotherapy for HCC (Tentative) Dr. Thomas Yau (China)
18:35-18:50	5-4 Leukotrienes Derived from Tumor-Infiltrating M2 Macrophages Promote the Progression of Hepatocellular Carcinoma Dr. Takuto Nosaka (Japan)
18:50-19:05	5-5 Multiomics Profiling Identifies the Link between Intra-tumor Steatosis and Immune-exhaustion in Non-viral HCC Dr. Takahiro Kodama (Japan)
19:05-19:20	Discussion Time

19:30-20:30 Evening Seminar (Sponsored by Incyte Biosciences Japan GK)

Chair: Dr. Yukiyasu Okamura (Japan)

New Personalized Approach for Intrahepatic Cholangiocarcinoma Based on Cancer Genomic Diagnosis in Japan
Dr. Naoya Kato (Japan)

Pemigatinib in Cholangiocarcinoma: Targeting FGFR2 Fusions
Dr. Arndt Vogel (Germany)

Day 1: December 17 (Friday) 2021

Room 2

8:00-9:00 Morning Seminar (2) (Sponsored by Otsuka Pharmaceutical Co., Ltd.)

Chair: Dr. Naoya Kato (Japan)

The Usefulness of Tolvaptan as a Treatment of Hepatic Edema among Advanced HCC Patients

Dr. Takamasa Ohki (Japan)

Clinical Symptoms of Liver Diseases: Pathogenesis and Treatment

Dr. Tatsuo Kanda (Japan)

9:05-10:50 Session 6: Surgery and Transplantation

Chairs: Dr. Seth J. Karp (USA)/Dr. Tadatoshi Takayama (Japan)

- 9:05-9:20 **6-1 Placental Stem Cell Transplantation Prevented Disease Development in Ornithine Transcarbamylase Deficiency Model Mice**
Dr. Toshio Miki (Japan)
- 9:20-9:35 **6-2 Minimal Invasive Hepatectomy in the Post-SVR Era**
Dr. Yuji Iimuro (Japan)
- 9:35-9:50 **6-3 Surgery for Perihilar Cholangiocarcinoma: Resection and Transplantation**
Dr. Masayuki Ohtsuka (Japan)
- 9:50-10:05 **6-4 Management of Hepatocellular Carcinoma “Current Therapeutic Options”**
Dr. Washim Jafri (Pakistan)
- 10:05-10:20 **6-5 Proposal of Resectability for Hepatocellular Carcinoma for Future Clinical Trial**
Dr. Etsuro Hatano (Japan)
- 10:20-10:35 **6-6 Hepatoblastoma Management: From Resection To Transplantation**
Dr. Mureo Kasahara (Japan)
- 10:35-10:50 Discussion Time

11:00-12:30 Session 7: HCC in Asia, Epidemiology (1)

Chairs: Dr. Wan Long Chuang (Taiwan)/ Dr. Necati Örmeci (Turkey)/ Dr. Fumio Imazeki (Japan)

- 11:00-11:15 **7-1 HCC in China, Epidemiology (Tentative)**
Dr. Lai Wei (China)
- 11:15-11:30 **7-2 Epidemiological Aspects of HCC Prevention in Asia-Pacific**
Dr. Manoj K Sharma (India)
- 11:30-11:45 **7-3 Changing Epidemiology of Hepatocellular Carcinoma in Taiwan**
Dr. Wan-Long Chuang (Taiwan)
- 11:45-12:00 **7-4 The Magnified Challenge of HCC in Bangladesh in the Context of COVID-19 Pandemic**
Dr. Mamun-Al Mahtab (Bangladesh)
- 12:00-12:15 **7-5 HCC Caused by Hepatitis Delta Virus Infection in Asia-Pacific**
Dr. Saeed Hamid (Pakistan)
- 12:15-12:30 Discussion Time

12:40-13:40 Luncheon Seminar (2) (Sponsored by Sysmex Co., Ltd.)

Chair: *Dr. Jia-Horng Kao (Taiwan)*

M2BPGi for Liver Fibrosis and Outcome Prediction

Dr. Tung-Hung Su (Taiwan)

14:30-16:00 Session 8: HCC in Asia, Epidemiology (2)

Chairs: *Dr. Hasmik Ghazinyan (Armenia) /Dr. Tatsuya Kanto (Japan)/Dr. Osamu Yokosuka (Japan)*

- 14:30-14:45 8-1 **Epidemiology Hepatocellular Carcinoma (HCC) in Thailand**
Dr. Teerha Piratvisuth (Thailand)
- 14:45-15:00 8-2 **Hepatocellular Carcinoma in Indonesia: Immunology View**
Dr. Rino Gani (Indonesia)
- 15:00-15:15 8-3 **Global Epidemiology & Risk Factors of Hepatocellular Carcinoma**
Dr. Man-Fung Yuen (China)
- 15:15-15:30 8-4 **Epidemiology of HCC in Mongolia**
Dr. Oidov Baatarxuu (Mongolia)
- 15:30-15:45 8-5 **Epidemiology of Viral Hepatitis and HCC in Japan**
Dr. Junko Tanaka (Japan)
- 15:45-16:00 Discussion Time

16:10-17:40 Session 9: Management of HCC and Complications during TKI Treatment

Chairs: *Dr. A. Kadir Dokmeci (Turkey)/Dr. Diana A. Payawal (Philippines)/ Dr. Tetsuo Takehara (Japan)*

- 16:10-16:25 9-1 **HCC Treatment in JRCMC (Japanese Red Cross Medical Center)**
Dr. Hideo Yoshida (Japan)
- 16:25-16:40 9-2 **Management of Adverse Event from the Pharmacological Perspective in Patients with Hepatocellular Carcinoma Using Tyrosine Kinase Inhibitor**
Dr. Hironao Okubo (Japan)
- 16:40-16:55 9-3 **Management of HCC Patient with Portal Vein Thrombosis**
Dr. Shiv Kumar Sarin (India)
- 16:55-17:10 9-4 **Contrast-enhanced US-based Assessment of HCC Hemodynamics Related to Systemic Treatment**
Dr. Hitoshi Maruyama (Japan)
- 17:10-17:25 9-5 **Effective Prevention of TKI-related Vascular Damage induced Adverse Events and Maintenance of Hepatic Function by Dried Bonito Broth and Histidine**
Dr. Kenya Kamimura (Japan)
- 17:25-17:40 Discussion Time

17:50-19:20 Session 10: HCC after SVR

Chairs: *Dr. Shuhei Nishiguchi (Japan) /Dr. Yasuhito Tanaka (Japan)/ Dr. Hiroshi Yatsushashi (Japan)*

- 17:50-18:05 10-1 **Rapid Hepatitis C Virus Clearance by Antivirals Correlates with Immune Status of Infected Patients and Decreased Immune Related Cytokines and Chemokines**
Dr. Reina Sasaki (Japan)

- 18:05-18:20 10-2 **The Clinical and Pathogenic Significance of HCC after Viral Eradication**
Dr. Min-Lung Yu (Taiwan)
- 18:20-18:35 10-3 **Risk of Hepatocellular Carcinoma After Sustained Virological Response in
Hepatitis C Virus Infection**
Dr. Yoichi Hiasa (Japan)
- 18:35-18:50 10-4 **Development of HCC in Treated HBV Patients**
Dr. Jia-Hornng Kao (Taiwan)
- 18:50-19:05 10-5 **Gene Expression Signature Associated with HCC Development after HCV
Eradication**
Dr. Yasuhito Tanaka (Japan)
- 19:05-19:20 Discussion Time

20:00-22:30 APASL Hepatology Webinar “Editor’s Choice” Collaborated with AASLD

Day 1: December 17 (Friday) 2021

Room 3

9:10-10:06 Oral Free Papers (1)

Chairs: Dr. Jun Arai (Japan)/Dr. Takumi Kawaguchi (Japan)/Dr. Naoya Sakamoto (Japan)

- 9:10-9:17 #10046 **Surgical Treatment for Multinodular HCC with Right Hepatic Vein Tumor Thrombosis: A Case Report**
Dr. Giang Nguyen (Viet Nam)
- 9:17-9:24 #10006 **A Case with HCC Successfully Treated with Prednisone for Atezolizumab-Associated Grade 3 Colitis**
Dr. Takahiro Fuji (Japan)
- 9:24-9:31 #10045 **New Research Trends in Onco-carcinogenesis and Nutritional Background Linked with Chronic Inflammation, Iron (Fe) Deposition, and Metabolic Changes**
Dr. Kenichi Furuya (Japan)
- 9:31-9:38 #10061 **Case reports of HCC with IVC and Rt. Atrium Tumor Thrombus and Extension into Left Renal Vein**
Dr. Parimita Barua (India)
- 9:38-9:45 #10005 **Novel Immuno-Oncotherapy against HCC by Targeting MICA**
Dr. Yumi Otoyama (Japan)
- 9:45-9:52 #10066 **Synergistic Nanoassemblies with Enhanced Cancer Chemo-Immunotherapy**
Dr. Xiaowei Shi (China)
- 9:52-9:59 #10012 **Various Uses of Ramucirumab in Real World Practice for Patients with Hepatocellular Carcinoma**
Dr. Naoya Kanogawa (Japan)
- 9:59-10:06 #10049 **Regorafenib and its metabolites could induce NK cell-mediated cytotoxicity in HCC by targeting ADAM9**
Dr. Jun Arai (Japan)

12:30-13:30 Luncheon Seminar (3) (Sponsored by Eisai Co., Ltd./MSD K.K.)

Chair: Dr. Shuntaro Obi (Japan)

LEN-TACE Sequential Therapy as a Therapeutic Strategy for Intermediate-stage Hepatocellular Carcinoma Dr. Yoshiyuki Wada (Japan)

Positioning of Hepatic Arterial Infusion Chemotherapy and Lenvatinib for Advanced Hepatocellular Carcinoma Dr. Tatsuya Yamashita (Japan)

14:30-15:30 Educational Seminar (1) (Sponsored by Miyarisan Pharmaceutical Co., Ltd.)

Chair: Dr. Tadatoshi Takayama (Japan)

Role of Gut Microbiota in Liver Disease and Carcinogenesis

Dr. Nobuhiro Nakamoto (Japan)

15:40-16:50 Oral Free Papers (2)

Chairs: Dr. Hidenari Nagai (Japan)/Dr. Yuko Nagaoki (Japan)

- 15:40-15:47 #10004 **Particle Radiotherapy for Hepatocellular Carcinoma with Portal Vein Tumor Thrombosis**
Dr. Yoshiro Matsuo (Japan)
- 15:47-15:54 #10024 **Efficacy and Safety of Lenvatinib for Patients with Advanced Hepatocellular Carcinoma in Japan**
Dr. Tadashi Namisaki (Japan)
- 15:54-16:01 #10020 **HCC Surveillance Remains Cost-effective Long after Hepatitis B Surface Antigen Loss: A 12-year Study**
Dr. Terry Cheuk-Fung Yip (Japan)
- 16:01-16:08 #10064 **Hepatocellular Carcinoma Emergence in Armenia: Outcome of Multiple Risk Factors, 2019-2020**
Dr. Hasmik Levon Ghazinyan (Armenia)
- 16:08-16:15 #10058 **Nucleic Acid Analog Therapy and Liver Carcinogenesis in Patients with Chronic Hepatitis B**
Dr. Makoto Moriyama (Japan)
- 16:15-16:22 #10029 **Impact of Viral Eradication by DAA on Clinical Outcome after Treatment for HCV Associated HCC**
Dr. Yuko Nagaoki (Japan)
- 16:22-16:29 #10047 **The Comprehensive Prognosis of Chronic Hepatitis C after DAA Therapy for Chronic Hepatitis C**
Dr. Yuki Kanayama (Japan)
- 16:29-16:36 #10023 **Comparison of HBV Reactivation in HCC Patients Who Received TKI and TKI with PD-1 Inhibitor**
Dr. Jin Lei (China)
- 16:36-16:43 #10067 **Occult Hepatitis B Virus Infection in Patients with HCV-Related Hepatocellular Carcinoma**
Dr. Muhammad Abdel-Gawad (Egypt)
- 16:43-16:50 #10069 **Bone Mineral Density in Patients with Non-Alcoholic Fatty Liver Disease**
Dr. Muhammad Abdel-Gawad (Egypt)

Day 2: December 18 (Saturday) 2021

Room 1

8:00-9:00 Morning Seminar (3) (Sponsored by Mitsubishi Tanabe Pharma Corporation)

Chair: Dr. Katsutoshi Tokushige (Japan)

New Findings and Future Prospects, Based on Japanese Patients of Histological Proven NAFLD in Toranomon Hospital Dr. Norio Akuta (Japan)

9:10-10:40 Session 11: Molecular Mechanism of HCC (2)

Chairs: Dr. Lai Wei (China)/Dr. Shuichi Kaneko (Japan)/Dr. Shinji Tanaka (Japan)

- 9:10-9:25 11-1 **The Interaction of Hepatoma Cells and Stromal Cells Via IL-6 Family Cytokines**
Dr. Hayato Hikita (Japan)
- 9:25-9:40 11-2 **Impairment of Homologous Recombination by HBx as the Mechanism for HBV-Related Hepatocarcinogenesis**
Dr. Motoyuki Otsuka (Japan)
- 9:40-9:55 11-3 **Recent Progress in Basic and Clinical Research of Liver Cancer Stem Cells**
Dr. Taro Yamashita (Japan)
- 9:55-10:10 11-4 **Genetic Alterations during Multistep Hepatocarcinogenesis Revealed by Whole Genome Sequencing**
Dr. Haruhiko Takeda (Japan)
- 10:10-10:25 11-5 **Predictive Scores for Hepatocellular Carcinoma Risk Stratification after Achieving SVR Following DAAS**
Dr. Gamal Shiha (Egypt)
- 10:25-10:40 Discussion Time

10:50-12:20 Session 12: HAIC, TACE, RFA, Radiation

Chairs: Dr. Ji Dong Jia (China)/Dr. Satoshi Mochida (Japan)/Dr. Hitoshi Yoshiji (Japan)

- 10:50-11:05 12-1 **Radiofrequency Ablation for Hepatocellular Carcinoma**
Dr. Ryosuke Tateishi (Japan)
- 11:05-11:20 12-2 **Hepatic Arterial Infusion Chemotherapy (HAIC) in 2021**
Dr. Shuntaro Obi (Japan)
- 11:20-11:35 12-3 **Effective Use of Local Ablation Therapy for the Treatment of Early to Intermediate HCC**
Dr. Kazuhiro Nouso (Japan)
- 11:35-11:50 12-4 **The Key Recommendations by APASL PBC Guidance 2021**
Dr. Ji Dong Jia (China)
- 11:50-12:05 12-5 **Laparoscopic Radiofrequency Ablation in the Era of Non-viral Hepatitis**
Dr. Naoki Morimoto (Japan)
- 12:05-12:20 Discussion Time

12:30-13:30 Luncheon Seminar (4) (Sponsored by AbbVie GK)

Chair: Dr. Masayuki Kurosaki (Japan)

Ultra-FP Treatment could be Affordable Treatment Option for Advanced Stage of HCC

Dr. Yasuteru Kondo (Japan)

Antiviral Therapy for Hepatocellular Carcinoma: Primary and tertiary Prevention

Dr. Ryosuke Tateishi (Japan)

14:30-16:00 Session 13: Intermediate-stage HCC (3) (TKI, Sorafenib, Regorafenib)

Chairs: Dr. Manoj K Sharma (India)/Dr. Norifumi Kawada (Japan)

14:30-14:45 13-1 **Exploring Tumor Microenvironment in Patients with Advanced Hepatocellular Carcinoma**

Dr. Hiroaki Kanzaki (Japan)

14:45-15:00 13-2 **Management Challenges for Intermediate Stage Hepatocellular Carcinoma (HCC) in the Era of Systemic Therapy**

Dr. Cosmas Rinaldi A. Lesmana (Indonesia)

15:00-15:15 13-3 **Impact of Skeletal Muscle Volume in Patients with Intermediate-stage Hepatocellular Carcinoma (HCC) Receiving Sorafenib: A Comparison with Advanced HCC patients**

Dr. Issei Saeki (Japan)

15:15-15:30 13-4 **Mechanisms and Management of Sorafenib Resistance in Hepatocellular Carcinoma**

Dr. Rakhi Maiwall (India)

15:30-15:45 13-5 **Optimal Sequencing of TKI after Atezolizumab and Bevacizumab in HCC**

Dr. Wei-Peng Yong (Singapore)

15:45-16:00 Discussion Time

16:10-17:40 Session 14: Intermediate-stage HCC (5) (Ramucirumab, etc.)

Chairs: Dr. Pei Jer Chen (Taiwan)/ Simone Strasser (Australia)/Dr. Namiki Izumi (Japan)

16:10-16:25 14-1 **Systemic Therapy for Intermediate-stage Hepatocellular Carcinoma Including Real-world Data of Ramucirumab Treatment as Second or Later Line**

Dr. Yutaka Yasui (Japan)

16:25-16:40 14-2 **Analyses of Intermediate-stage Hepatocellular Carcinoma Patients Receiving TACE Prior to Designing Clinical Trials**

Dr. Keisuke Koroki (Japan)

16:40-16:55 14-3 **Hepatocellular Carcinoma Emergence in Armenia: Outcome of Multiple Risk Factors, January 2019 to March 2020 Nork Clinical Hospital of Infectious Diseases**

Dr. Hasmik Ghazinyan (Armenia)

16:55-17:10 14-4 **Management of Intermediate Hepatocellular Carcinoma - Past, Present and Future**

Dr. George Lau (China)

17:10-17:25 14-5 **Treatment Strategy of Intermediate-stage HCC: LEN-TACE Sequential Therapy**
Dr. Masatoshi Kudo (Japan)

17:25-17:40 Discussion Time

17:40-17:50 Awarding Ceremony

17:50-18:00 Closing Ceremony

Dr. Mitsuhiro Moriyama (President of APASL Oncology 2021)

Day 2: December 18 (Saturday) 2021

Room 2

8:00-9:00 Morning Seminar (4) (Sponsored by Takeda Pharmaceutical Co., Ltd.)

Chair: Dr. Shinichi Takahashi (Japan)

Gastric Cancer Risk with H. Pylori Infection and Gastric Cancer Management in Japan

Dr. Kazunari Murakami (Japan)

9:10-10:40 Session 15: COVID-19 in Japan

Chairs: Dr. Masashi Mizokami (Japan)/Dr. Mitsuhiro Moriyama (Japan)

- 9:10-9:25 15-1 **Diagnosis, Genome Surveillance and Immune Response of COVID-19**
Dr. Yosuke Hirotsu (Japan)
- 9:25-9:40 15-2 **Serum Predictive Factors for Severe Symptoms of COVID-19**
Dr. Masaya Sugiyama (Japan)
- 9:40-9:55 15-3 **Management of Hepatocellular Carcinoma in the Era of COVID-19**
Dr. Shuichiro Shiina (Japan)
- 9:55-10:10 15-4 **Responses to COVID-19 Outbreaks in Healthcare Setting in Japan, January 2020 -
September 2021**
Dr. Takuya Yamagishi (Japan)
- 10:10-10:25 15-5 **COVID-19 in Japan**
Dr. Hiroshi Yotsuyanagi (Japan)
- 10:25-10:40 Discussion Time

10:50-12:20 Session 16: Diagnosis of HCC

Chairs: Dr. Jee-Fu Huang (Taiwan)/Dr. Kiyoshi Hasegawa (Japan)/Dr. Masahiro Ogawa (Japan)

- 10:50-11:05 16-1 **Imaging Evaluation of HCC in the Systemic Treatment Era**
Dr. Takamichi Murakami (Japan)
- 11:05-11:20 16-2 **Tumor Marker Profiles in Patients with Viral and Non-viral Hepatocellular
Carcinoma**
Dr. Hidenori Toyoda (Japan)
- 11:20-11:35 16-3 **Diagnosis of HCC (Tentative)**
Dr. Do Young Kim (Korea)
- 11:35-11:50 16-4 **Diagnosis of Hepatocellular Carcinoma by Contrast-enhanced Ultrasound –
Focusing on Early Hepatocellular Carcinoma**
Dr. Hiroko Iijima (Japan)
- 11:50-12:05 16-5 **aMAP Score Prediction of Hepatocellular Carcinoma Development in Patients with
Chronic Liver Disease**
Dr. Takeji Umemura (Japan)
- 12:05-12:20 Discussion Time

12:30-13:30 Luncheon Seminar (5) (Sponsored by Gilead Sciences K.K.)

Chair: Dr. Yoshiyuki Ueno (Japan)

Current Status of HBV Prevalence and Efforts for Eradicating Hepatic Failure by HBV Reactivation in Patients with Cancer Dr. Sachiyo Yoshio (Japan)

Recent Advances in Systemic Therapy for Hepatocellular Carcinoma and Management of Hepatitis B Infection Dr. Kaoru Tsuchiya (Japan)

14:30-16:00 Session 17: Intermediate-stage HCC (4) (TKI, Lenvatinib)

Chairs: Dr. Jin Mo Yang (Korea)/Dr. Kazuaki Chayama (Japan)/Dr. Takuji Torimura (Japan)

- 14:30-14:45 17-1 **Treatment Strategy of Intermediate Stage HCC using Lenvatinib “Lenvatinib TACE Sequential Therapy”**
Dr. Yusuke Kawamura (Japan)
- 14:45-15:00 17-2 **Lenvatinib for Intermediate Stage HCC**
Dr. Yoshinari Asaoka (Japan)
- 15:00-15:15 17-3 **The Dawn of a New Era in Hepatocellular Carcinoma Treatment with Molecular Targeted Therapy and Local Therapy**
Dr. Eishiro Mizukoshi (Japan)
- 15:15-15:30 17-4 **Adjuvant Systemic Therapies in Intermediate HCC**
Dr. Levent Doğanay (Turkey)
- 15:30-15:45 17-5 **Value of Lenvatinib in the Treatment of Intermediate Stage HCC**
Dr. Chun-Jen Liu (Taiwan)
- 15:45-16:00 Discussion Time

16:10-17:40 Session 18: Intermediate-stage HCC (6) (TKI, Lenvatinib)

Chairs: Dr. Sumiko Nagoshi (Japan)/Dr. Yoshiyuki Ueno (Japan)

- 16:10-16:25 18-1 **Contrast-enhanced Ultrasonography for Blood Flow Detection in Hepatocellular Carcinoma During Lenvatinib Therapy**
Dr. Naoki Matsumoto (Japan)
- 16:25-16:40 18-2 **Guidelines in Evolution: Systemic Therapy for Intermediate-stage HCC**
Dr. Chiun Hsu (Taiwan)
- 16:40-16:55 18-3 **Importance of Keeping Balance Between Therapeutic Effects and Adverse Events in Lenvatinib for Hepatocellular Carcinoma~Refinement of Administration Schedule and Combination with Transarterial Therapy~**
Dr. Hideki Iwamoto (Japan)
- 16:55-17:10 18-4 **Role of Tumor Immunogenicity and Tumor-associated Macrophages in Multi-kinase Inhibitor Responses for Hepatocellular Carcinoma**
Dr. Pil Soo Sung (Korea)
- 17:10-17:25 18-5 **The Prediction Model of HBV-HCC During Anti-viral Therapy**
Dr. Hong You (China)
- 17:25-17:40 Discussion Time

Day 2: December 18 (Saturday) 2021

Room 3

8:00-9:00 Morning Seminar (5) (Sponsored by AstraZeneca)

Chair: Dr. Hiroo Imazu (Japan)

Treatment Strategies for Acid Related Disease in Primary Care-Based on Clinical Practice Guidelines for GERD 2021 Dr. Akihito Nagahara (Japan)

9:10-10:34 Oral Free Papers (3)

Chairs: Dr. Shinya Maekawa (Japan)/Dr. Masahito Shimizu (Japan)/Dr. Katsutoshi Tokushige (Japan)

- 9:10-9:17 #10008 **Contribution of dMMR to Accumulation of Somatic Mutations at Different Stages of HCC Development**
Dr. Masayuki Ueno (Japan)
- 9:17-9:24 #10033 **Genetic Discrimination between Multicentric Occurrence and Intrahepatic Metastasis in Multifocal HCC**
Dr. Yuji Iimuro (Japan)
- 9:24-9:31 #10015 **An Assistive Computational Tool for Defining the Segmental Anatomy of the Liver**
Dr. Harvey Ho (New Zealand)
- 9:31-9:38 #10035 **The Protective Role of DNA Methyltransferase 3B Against Inflammatory Hepatocarcinogenesis**
Dr. Eriko Iguchi (Japan)
- 9:38-9:45 #10060 **Utility of AFP, AFP-L3, and PIVKA-II for Hepatocellular Carcinoma Surveillance**
Dr. Supot Nimanong (Thailand)
- 9:45-9:52 #10062 **Natural Killer Cells Putative Role in Patients with HCV-Related Hepatocellular Carcinoma**
Dr. Mohamed Abdel-Samiee (Egypt)
- 9:52-9:59 #10076 **Let-7a and Let-7i as Biomarkers for CHC Patients with HCC Risk after Anti-viral Treatment**
Dr. Ming-Lung Yu (Taiwan)
- 9:59-10:06 #10009 **Post-treatment Cell-free DNA as a Predictive Biomarker in Systemic Therapy for HCC**
Dr. Takuma Nakatsuka (Japan)
- 10:06-10:13 #10026 **The Combination of ALBI and PT Predict Liver Dysfunction after TACE for HCC within Up-to-7 Criteria**
Dr. Hiroaki Takaya (Japan)
- 10:13-10:20 #10063 **MicroRNA Gene Polymorphisms and Development of Hepatocellular Carcinoma in Egyptian Patients**
Dr. Mohamed Abdel-Samiee (Egypt)

10:20-10:27 #10079 **Analysis of Sarcopenia in Patients with BCLC Stage B HCC who Received Atezolizumab Plus Bevacizumab**

Dr. Hiroaki Matsumoto (Japan)

10:27-10:34 #10080 **The Simple Product of Albumin and Platelets Indicates the Stage of Liver Fibrosis and Prognosis**

Dr. Koji Fujita (Japan)

11:00-12:00 Educational Seminar (2) (Sponsored by AbbVie GK)

Chair: Dr. Junko Tanaka (Japan)

SVR & HCV-related HCC

Dr. Yoshinari Asaoka (Japan)

HCV Eradication in the SDGs Era

Dr. Hironao Okubo (Japan)

On-site Poster Session Program

Day 2: December 18 (Saturday) 2021 at 13:40-14:20

Room 4

On-Site Poster Session Group 1

Chair: Dr. Hirayuki Enomoto (Japan)

13:40-13:45

#10027 Hepatoma-derived Growth Factor as a Potential Therapeutic Target for Hepatocellular Carcinoma

Dr. Hirayuki Enomoto (Japan)

13:45-13:50

#10034 Iron Chelator Deferasirox Alters Sorafenib-induced Programmed Cell Deaths of Hepatoma Cells

Dr. Wataru Jomen (Japan)

13:50-13:55

#10088 Examination of the Detectability of Spoke Wheel Pattern by Contrast Ultrasonography in FNH

Dr. Masahiro Ogawa (Japan)

13:55-14:00

#10011 Bezafibrate Treatment is Associated with Reduced Risk for Development of HCC in Patients with PBC

Dr. Atsushi Tanaka (Japan)

14:00-14:05

#10031 Safety of Atezolizumab plus Bevacizumab in Hepatocellular Carcinoma

Dr. Hiroshi Numao (Japan)

On-site Poster Session Group 2

Chair: Dr. Fumitaka Suzuki (Japan)

13:40-13:45

#10054 Circulating IGFBP-1 Provides Resistance to Molecular Targeted Agent in Hepatocellular Carcinoma

Dr. Hiroyuki Suzuki (Japan)

13:45-13:50

#10081 Relationship between Serum Kynurenine Level and Prognosis of Patients with Hepatocellular Carcinoma

Dr. Shigemune Bekki (Japan)

13:50-13:55

#10082 Measurement of Renal Vein and IVC in Patients with Cirrhotic Ascites and Congestive Liver

Dr. Masahiro Kaneko (Japan)

13:55-14:00

#10017 Immune Checkpoint Inhibitor as a Therapeutic Choice for Double Cancer: A Case Series

Dr. Naoki Matsumoto (Japan)

14:00-14:05

#10078 An Autopsy Case of Ruptured Hepatocellular Carcinoma Following Administration of Lenvatinib

Dr. Kumichika Uchida (Japan)

On-site Poster Session Group 3

Chair: Dr. Ryota Masuzaki (Japan)

13:40-13:45

#10083 **A Case of Mortality from an Incidental Intrahepatic Cholangiocarcinoma with Severe Cholecystitis**
Dr. Yoshie Kadota (Japan)

13:45-13:50

#10041 **Laparoscopic Surgery could be Most Frequently Employ as a Treatment for HCC in SVR era**
Dr. Shuntaro Obi (Japan)

13:50-13:55

#10044 **ATZ+BEV Therapy can Control Disease Activity in Patients Who Do Not Respond to Lenvatinib**
Dr. Shuntaro Obi (Japan)

13:55-14:00

#10038 **Incidence of HCC is Quite Different Depending on the History of HCC; A Prospective Study by 600 SVRs**
Dr. Shuntaro Obi (Japan)

14:00-14:05

#10039 **Beware of Carcinogenesis Other Than HCC; A Prospective Study by 600 SVRs**
Dr. Shuntaro Obi (Japan)

14:05-14:10

#10040 **Risk Factors for Occurrence of HCC after DAA Therapy; A Prospective Study by 600 SVRs**
Dr. Shuntaro Obi (Japan)

14:10-14:15

#10043 **Is Liver Carcinogenesis after SVR IM or MC? By Analysis of Gene Profiles**
Dr. Shuntaro Obi (Japan)

On-site Poster Session Group 4

Chair: Dr. Makiko Taniai (Japan)

13:40-13:45

#10021 **Major Signaling Pathway in Hepatocellular Carcinoma and Drug-matched Variants**
Dr. Kenji Amemiya (Japan)

13:45-13:50

#10065 **Phenotypic and Genetic Features of Multiple Nodules in HCC Based on Tumor Evolutionary Trait**
Dr. Yosuke Hirotsu (Japan)

13:50-13:55

#10019 **Impact of Hepatectomy for Advanced Hepatocellular Carcinoma with Major Portal Vein Tumor Thrombus**
Dr. Shohei Komatsu (Japan)

13:55-14:00

#10084 **Conversion Surgery for Advanced Hepatocellular Carcinoma after Lenvatinib, a Case Report**
Dr. Kazuki Kato (Japan)

14:00-14:05

#10007 **TACE with Cisplatin Versus Epirubicin for Hepatocellular Carcinoma, a Randomised Controlled Trial**
Dr. Osamu Aramaki (Japan)

14:05-14:10

#10070 **Examination of the Effect of Embolization of Corona Enhancement Area on Local Tumor Recurrence**
Dr. Yukinobu Watanabe (Japan)

On-site Poster Session Group 5

Chair: Dr. Shinpei Sato (Japan)

13:40-13:45

#10085 **Experience of Antiviral Therapy in Patients Co-infected with HIV and Hepatitis Virus**
Dr. Yuki Haga (Japan)

13:45-13:50

#10036 **Levocarnitine Suppresses Lenvatinib-related Sarcopenia in Hepatocellular Carcinoma Patients**
Dr. Hironao Okubo (Japan)

13:50-13:55

#10025 **Clinical Features of Systemic Treatment in Japan**
Dr. Takaaki Tanaka (Japan)

13:55-14:00

#10022 **Clinical Trend of Japanese Patients with HCC in Progression of Aging Society: Clinical Role of RFA**
Dr. Shota Izumi (Japan)

14:00-14:05

#10037 **Two Cases of RFA for HCC in the Caudate Lobe; an Emerging Technique with Using Guided Needle Under CT**
Dr. Sae Yumita (Japan)

14:05-14:10

#10030 **The Cancer Risk in PSC and Ulcerative Colitis from 26 Years Retrospective Cohort Study in Japan**
Dr. Takashi Taida (Japan)

On-site Poster Session Group 6

Chair: Dr. Shintaro Yamazaki (Japan)

13:40-13:45

#10053 **Stereotactic Body Radiotherapy for Early-stage Hepatocellular Carcinoma: A Single-Center Experience**
Dr. Shunsuke Okuyama (Japan)

13:45-13:50

#10014 **Impact of Postoperative Complications on Survival of Hepatocellular Carcinoma Patients**
Dr. Hisashi Nakayama (Japan)

13:50-13:55

#10028 **Surgical Resection for Hepatocellular Carcinoma with Major Vascular Invasion**
Dr. Shintaro Yamazaki (Japan)

13:55-14:00

#10032 **Impact of Patient Age on Outcome after Resection for Hepatocellular carcinoma**
Dr. Masaharu Harada (Japan)

14:00-14:05

#10056 **Transient High Transaminase Elevation Does Not Affect on Short Term Outcomes after Liver Resection**
Dr. Yusuke Mitsuka (Japan)

14:05-14:10

#10003 **Sex-related Differences in Predictors of HCC Incidence after DAA Therapy in Patients with HCV**

Dr. Takao Watanabe (Japan)

E-Poster Session Program

E-Poster Presentation will be available through Website of APASL Oncology 2021 at <http://www.apasl-oncology2021.org/>

- #10001 **FBL is the Hub Gene of Pulmonary Metastasis in Hepatocellular Carcinoma**
Dr. Wen-Rui Wu (China)
- #10002 **Everolimus Protect IRI Through the Effect of Treg**
Dr. Li Zhu (China)
- #10010 **Real Impact of Tumor Marker AFP and PIVKA-II in Detecting Very Small Hepatocellular Carcinoma**
Dr. Akito Nozaki (Japan)
- #10013 **Durability of SVR in GT3 and GT6 Patients Treated with SOF/VEL with/without RBV from China**
Dr. Huagang Xiong (China)
- #10016 **Clinical Characteristics and Survival Analysis of Patients with HCC after HBV Negative**
Dr. Hong Li (China)
- #10018 **Characteristics of Genomic Profile of Hepatocellular Carcinoma after Sustained Virologic Response**
Dr. Hiroshi Ohyama (Japan)
- #10042 **A Case of Primary Biliary Cholangitis Undergoing RFA for Liver Metastasis of Cervical Cancer**
Dr. Ken Nogami (Japan)
- #10048 **Development of Novel Therapeutic Agents for HCC by Suppressing Soluble MICA through ADAM9 Inhibition**
Dr. Keita Ogawa (Japan)
- #10050 **Impacts of EZH2 Inhibitor UNC1999 on Tumor and Tumor Microenvironment in Hepatocellular Carcinoma**
Dr. Junjie Ao (Japan)
- #10051 **Efficacy of Sorafenib and Radiotherapy vs Sorafenib/Radiotherapy Monotherapy: A Systematic Review**
Dr. Rivaldo S. Heriyanto (Indonesia)
- #10052 **Combination Therapy with Lenvatinib and RFA for CPA Patients with HCC Exceeding up-to-7 Criteria**
Dr. Kazushi Numata (Japan)
- #10055 **The Effect of Glucosylceramide Synthase Inhibitor on Liver Fibrosis Regression**
Dr. Terunao Iwanaga (Japan)
- #10057 **Stereotactic Body Radiation Therapy for Early-stage Hepatocellular Carcinoma**
Dr. Shigeki Yano (Japan)
- #10059 **Combination Therapy for Multiple HCC with Tyrosine Kinase Inhibitor and Radiofrequency Ablation**
Dr. Keita Maki (Japan)
- #10068 **Macrotrabecular Massive Feature in Tumor is Associated with a Higher Risk of the Recurrence of HCC**
Dr. Hyun Woong Lee (Korea)
- #10071 **Acidic Microenvironment Aggravates HIRI by Modulating M1-Polarization by PPAR-gama Signal**
Dr. Wei Ding (China)
- #10072 **Protection Mechanism of DDIT4 S-Nitrosylation in ROS**
Dr. Yunfei Duan (China)
- #10074 **Molecular Mechanism of CCL7 by BRG1 in Liver Injury**
Dr. Yunjie Lu (China)
- #10075 **Dynamic Gut Microbiome Affects the Efficacy of PD-1-based Immunotherapy in Hepatocellular Carcinoma**
Dr. Chan Xie (China)
- #10086 **Regorafenib for Taiwanese Patients with Unresectable HCC after Sorafenib Failure**
Dr. Ming-Lung Yu (Taiwan)
- #10087 **Education and information sharing method for the coming era in ablation**
Dr. Maki Tobarai (Japan)
- #10089 **MWA vs. RFA in Intermediate Stage Hepatocellular Carcinoma: A Retro-prospective Study**
Dr. Diana Alcantara Babaran (Philippines)

APASL Oncology 2021 Tokyo

“Your Gateway to Oncology in Asia-Pacific Region”

Abstracts

General Sessions





Dr. Ryota Masuzaki

Division of Gastroenterology and Hepatology,
Department of Medicine,
Nihon University School of Medicine, Japan

Risk Assessment of Hepatocellular Carcinoma Development-Clinical and Molecular Perspective

Hepatocellular carcinoma (HCC) is one of the major causes of death worldwide. Curative treatments are limited in the early stages of cancer with well-reserved liver function. High-risk populations are chronic hepatitis patients, and their fibrosis stages are the strongest risk factor for the development of HCC. The degree of liver fibrosis is classified by fibrosis staging from F0 (no fibrosis) to F4 (cirrhosis), which has been found to be well correlated with the risk of HCC.

Although liver biopsy is the gold standard for the assessment of liver fibrosis, it is an invasive procedure with the possibility of serious complications. Transient elastography provides completely noninvasive measurement of liver stiffness, and the correlation between the stiffness and the liver fibrosis stage has been validated. We previously reported that liver stiffness obtained by transient elastography was a significant risk factor for HCC in chronic hepatitis C patients. The controlled attenuation parameter (CAP), measured by transient elastography, provides a standardized noninvasive measure of liver steatosis. The mechanism of fibrogenesis and fibrolysis has been studied since the findings can be noninvasive markers and therapeutic targets of chronic liver diseases. We focused on interactions between extracellular matrix and hepatocyte and found hepatic deletion of integrin beta1 caused liver fibrosis through activation of hepatic stellate cell in the murine model. Advances in sequencing technologies enable the identification of genetic variants, and several studies combining clinical parameters with single-nucleotide polymorphisms (SNPs) for risk assessment of HCC are recently reported. Establishments of possible biomarkers as a guide to therapeutic interventions are still unmet needs in this field. This presentation will summarize recent findings in risk assessment of HCC development through clinical and molecular perspectives.



Dr. Tetsuhiro Chiba

Department of Gastroenterology,
Graduate School of Medicine,
Chiba University, Japan

Role of FGF19/FGFR4 Signaling and Potential of Serum FGF19 as a Biomarker in Hepatocellular Carcinoma

FGF19 is normally secreted by the small intestinal epithelium and acts on hepatocytes in a paracrine manner to inhibit bile acid synthesis. On the other hand, FGF19 forms an autocrine loop by autocrine secretion in hepatocellular carcinoma (HCC) cells and has effects such as cell proliferation and anti-apoptosis through activation of MAPK signaling. In vitro and in vivo assays showed that inhibition of FGFR4, a receptor of FGF19, strongly suppressed proliferation of HCC cells and tumor growth. In addition, based on the results of FGF19/FGFR4 immunostaining in HCC tissues and measurement of serum FGF19 levels, we found that FGF19/FGFR4 signaling may be activated in about one-third of HCC cases, and serum FGF19 levels could be its surrogate marker. Enzyme-linked Immunosorbent Assay (ELISA) of pretreatment sera from TKI-treated patients showed that progression-free survival (PFS) of FGF19^{low} patients was significantly longer than that of FGF19^{high} patients in sorafenib treatment, but not lenvatinib treatment.

It has been reported that FGFs are also involved in angiogenesis and polarization of tumor-associated macrophages, and play an important role in the tumor microenvironment of HCC. In fact, in vivo experiments using a syngeneic mouse model demonstrated that administration of lenvatinib, a potent FGFR inhibitor, reduced the induction of Treg and M2 macrophages, which suppress the tumor immune response. The combination of atezolizumab/bevacizumab (ATZ/BV) highly effective in at least some cases. However, ELISA of pretreatment sera from ATZ/BV-treated patients demonstrated that the therapeutic effect in FGF19^{high} cases might be lower than that in FGF19^{low} cases.



Dr. Yutaka Midorikawa

Department of General Surgery,
National Center of Neurology and Psychiatry, Japan

Accumulation of Molecular Aberrations Distinctive to Hepatocellular Carcinoma Progression

Cancer develops through the accumulation of genetic and epigenetic aberrations. Liver tumors at early stage such as early hepatocellular carcinoma (HCC) arising from chronic liver disease and hepatocellular adenoma (HCA) in young women in association with use of estrogen-containing medications progress with accumulated mutations to overt HCC in a stepwise manner. Using such samples, we and others have characterized genetic and epigenetic alterations associated with early versus late molecular events of hepatocarcinogenesis, and TERT promoter mutation is the most frequent molecular aberration in early HCC and HCA. Similar to APC mutations in the multistep genetic model for the formation of colorectal cancer, the formation of overt HCC requires the sequential genetic aberrations in addition to the driver gene mutations.

With recent advances in biological technologies, high-throughput genome sequencing has been used to elucidate the genetic basis of many diseases. To date, several researchers have used next generation sequencing (NGS) technologies to identify molecular aberrations in HCC specimens, and a large number of mutations in genes involved in the p53 and β -catenin pathways and somatic mutations of genes involved in chromatin remodeling, histone methylation, AKT/PI3K signaling, and JAK/STAT signaling were common in HCC. Furthermore, it was attempted to classify overt HCC into subtypes mainly with respect to etiological background of the underlying liver disease and pathological aspects of HCC.

Unlike the gene expression or copy number aberrations, simple gene mutations were relatively frequent in the early stage of HCC. Previous reports based on NGS data have demonstrated that mutations in the WNT and p53/RB pathways are common in HCC and these driver mutations are also common in early HCC. However, downstream genes in these pathways were not activated, suggesting that additional molecular events apparently cooperate for transcriptional activation of corresponding downstream targets during HCC progression

Besides the gene expression profile and mutational signature, landscape of aberrant methylation of epidrivers has been elucidated by genome-wide methylation profiling. In these reports, utility of panel of methylated genes for early biomarkers of HCC using plasma DNA were determined, and predictive biomarkers based on promoter DNA methylation of several epidrivers were identified for patients with HCC.

Here, the genetic and epigenetic driver aberrations responsible for initiation and progression of liver cancer is described and the pathways that were frequently responsible for liver cancer progression will be identified.



Dr. Ratna B. Ray

Department of Pathology,
Saint Louis University, USA

Linking lncRNA Linc-Pint with Liver Disease

Hepatitis C virus often causes chronic infection in liver, cirrhosis, and, in some instances, HCC. HCV encodes several factors' those impair host genes for establishment of chronic infection. The long noncoding RNAs (lncRNAs) display diverse effects on biological regulations. However, their role in virus replication and underlying diseases is poorly understood. In this study, we have shown that HCV exploits lncRNA long intergenic nonprotein-coding RNA, p53 induced transcript (Linc-Pint) in hepatocytes for enhancement of lipogenesis. We identified a lncRNA, Linc-Pint, which is significantly down-regulated in HCV-replicating hepatocytes and liver specimens from HCV infected patients. Using RNA pull-down proteomics, we identified serine/arginine protein specific kinase 2 (SRPK2) as an interacting partner of Linc-Pint. A subsequent study demonstrated that overexpression of Linc-Pint inhibits the expression of lipogenesis-related genes, such as fatty acid synthase and ATP-citrate lyase. Together, our results suggested that down-regulation of Linc-Pint enhances lipogenesis favoring virus replication and liver disease progression. In conclusions, we found that SRPK2 is a direct target of Linc-Pint and that depletion of SRPK2 inhibits lipogenesis. Our study contributes to the mechanistic understanding of the role of Linc-Pint in liver pathogenesis.



Dr. Hiroyuki Aburatani

Genome Science & Medicine laboratory

Research Center for Advanced Science and Technology,

The University of Tokyo, Japan

Genetic and Epigenetic Basis of Pediatric Liver Tumors

Hepatoblastoma (HB) is the most common pediatric liver malignancy; however, hereditary predisposition and acquired molecular aberrations related to HB clinicopathological diversity are not well understood. We performed an integrative genomic profiling of 163 pediatric liver tumors (154 HBs and nine hepatocellular carcinomas) based on the data acquired from a cohort study (JPLT-2). The total number of somatic mutations is extremely low, 0.52/Megabase on exonic regions, but increased with age at diagnosis. Telomerase reverse transcriptase (TERT) promoter mutations, which is the most frequent driver event in adult hepatocellular carcinoma, are prevalent in the tween HBs, particularly in the transitional liver cell tumor (TLCT, > 8 years old). On the other hand, in classical HBs a certain set of transcriptional enhancers is hypomethylated and enriched with binding sites for ASCL2, a regulatory transcription factor for definitive endoderm in Wnt-pathway. Prolonged upregulation of ASCL2, as well as fetal-liver-like methylation patterns of IGF2 promoters, suggests their “cell of origin” derived from the premature hepatoblast, similar to intestinal epithelial cells, which are highly proliferative. Systematic molecular profiling of HB will accelerate our understanding on the epigenetic basis of hepatoblast carcinogenesis and risk stratification of heterogeneous pediatric liver tumors.



Dr. Kazufumi Kobayashi

Translational Research and Development Center, Chiba University Hospital.
Department of Gastroenterology, Graduate School of Medicine, Chiba
University, Japan

Analysis for Transition of Molecular Target Agent Therapy and Prognosis in Advanced Hepatocellular Carcinoma

Background: Sequential therapy using multiple molecular target agents (MTAs) is increasingly becoming a mainstream treatment strategy for hepatocellular carcinoma (HCC). However, the effectiveness of the treatment strategy transition remains unclear. The present study aimed to clarify the current practical use of MTAs and its effectiveness in HCC treatment.

Methods: In this multicenter, retrospective study, we collected and analyzed the clinical data of 877 patients who underwent MTA therapy for HCC from June 2009 to March 2019 at several institutes in Japan. The patients were classified into 3 groups as per the period of initial MTA treatment beginning (period 1: 2009–2012, n = 267; period 2: 2013–2016, n = 352; period 3: 2017–2019, n = 258). We assessed the patient characteristics, MTA use, and prognosis of the 3 groups.

Results: The proportion of patients with advanced-stage HCC, defined as the identification of either extrahepatic metastasis and/or macrovascular invasion, in each period was 70.1%, 66.5%, and 62.0% in period 1, 2, and 3, respectively. MTA use for non-advanced-stage HCC increased with the passage of time ($p = 0.052$). The proportion of multiple MTAs use was remarkably increased in the 3 groups (1.1%, 10.2%, and 42.6%, respectively, $p < 0.0001$). The median overall survival (OS) was 11.9 months for the entire cohort and 10.4, 11.3, and 15.2 months, for period 1, 2, and 3, respectively. It is noteworthy that the prognosis of patients with HCC improved over time ($p = 0.016$). The treatment duration was also prolonged with time (2.7, 3.2, and 6.6 months for period 1, 2, and 3, respectively; $p < 0.0001$). The correlation between OS and MTA treatment duration was strengthened (period 1: 0.395, period 2: 0.505, and period 3: 0.667). These trends were confirmed in both advanced- and non-advanced-stage HCC patients. However, the OS of the patients with non-advanced-stage HCC was not significantly different between the 3 groups (15.0, 13.1, and 16.1 months, respectively). The survival time after the MTA treatment discontinuation was highly shortened in patients with non-advanced-stage HCC (9.2, 6.5, and 3.3 months, for period 1, 2, and 3, respectively; $p = 0.003$).

Conclusions: The availability of multiple MTAs had steadily improved the prognosis of patients with advanced-stage HCC. However, the impact of the prognostic improvement in patients with non-advanced-stage HCC was not as remarkable as expected. The development of innovative treatment strategies is required for this patient group.



Dr. Massimo Giuseppe Colombo

Liver Center San Raffaele Hospital, Milan, Italy

HCC Following Hepatitis C Virus Eradication

Federica Invernizzi, Marta Cilla and Massimo Giuseppe Colombo

Liver Center San Raffaele Hospital, Milan, Italy

The excess risk of hepatocellular carcinoma (HCC) that remains in hepatitis C virus (HCV) patients following virus eradication (SVR) with antivirals, caused biannual surveillance with abdominal ultrasound (US) to be recommended by all scientific societies with the aim to improve early detection of HCC and reduce cancer related mortality. There are, however, nuances among the recommendations of the three major liver societies with respect to strategies of screening, namely the need of adding on serum alpha-fetoprotein, using second level imaging with CT scan or MRI in difficult to screen populations and screening beyond the classical target of cirrhosis. While a simplified approach of screening aims to optimize management of patients at risk during an emergency like the Covid pandemic, it is unclear how safe a relaxed screening in low risk patients may be considering that SVR is associated with a 80% reduction of HCC risk (Beng 2017), the annual risk of HCC after SVR spanning from 0.24 in non cirrhotics to 1.22 in cirrhotics classified by non invasive tests (NIT) (Ioannou 2019). However, anecdotal reports indicate that the former patients may still experience an acceleration of disease progression due to metabolic and life style factors (alcohol and tobacco), which in turn may exacerbate HCC risk. Onset of de-novo HCC after SVR has long been matter of dispute, now it is clearly associated to predictors like advanced age, male sex, diabetes and, again, disease severity (Degasperi 2020; Auderau 2020). It should be outlined that beyond a reduction of cancer risk, SVR patients experience additional clinical benefits that translate into a reduction of all cause mortality in comparison with viremic patients (Cabibbo 2017; Toyoda 2021). The threat that highly effective antiviral therapy with direct acting antivirals could enhance the risk of rapidly developing aggressive HCC appears now to be confined to patients with pre-treatment unmeasured non malignant nodules at CT or MR (Sangiovanni 2020). Also the risk of enhanced recurrence of HCC following SVR is no longer a matter of concern as such a risk was not enhanced in SVR patients according to a single study data meta-analysis in the US (Singal 2019) and in a single patient data meta-analysis in EU and Asia (Sabena 2021). By modelling, surveillance appears to be cost effective in patients with cirrhosis, bridging fibrosis (Metavir F3) or FIB-4 >3.24 (Zangneh 2019), thus guiding EASL to choose these patients as target of screening. Instead, AASLD recommends screening in patients with cirrhosis diagnosed by either histology or NIT only, whereas APASL recommends surveillance in older patients, those with cirrhosis (even if regressed) or with diabetes.



Dr. Ann-Lii Cheng

NTU Chair Professor, National Taiwan University
President Emeritus, NTU Cancer Center, Taiwan

Integrating Systemic Therapy into Multidisciplinary Treatment of HCC

Awareness of systemic therapy has been increasing in Asia in the past ten years. As reflected in the sorafenib arm of prospective phase III studies, median survival of the Asian population increased from 6.5 months (AP study, 2008) to 13.1 months (IMbrave 150 study, 2019). Willingness of adopting systemic therapy earlier in the disease courses has been exemplified in the recent proposal for intermediated-stage diseases with lesions unsuitable for TACE. For the latter, curative conversion with effective systemic therapy, such as lenvatinib or atezo-bev, is estimated to be around 20-25%. Similarly, curative conversion is also possible in 10-15% of advanced-stage diseases. A harmonized treatment policy for intermediate- and advanced-stage diseases is emerging, in which systemic therapy is used to downstage the tumor to a status that locoregional treatment with curative attempt is possible.



Dr. Atsushi Hiraoka

Gastroenterology Center,

Ehime Prefectural Central Hospital, Japan

Systemic Treatment Including Lenvatinib in Patients with BCLC-B Stage Hepatocellular Carcinoma

Multiple regimens of systemic treatments including immune-combination treatment have been available in clinical practice. These developments have improved the prognosis of patients with unresectable hepatocellular carcinoma (HCC) BCLC stage B and a Child-Pugh score of A (range, 13 to 19 months in reported trials). These results have given hope to affected patients as well as clinicians. Although the guidelines presented by the Japanese Society of Hepatology (JSH) recognize trans-arterial chemoembolization (TACE) as the conventional first-line treatment method for BCLC-B HCC cases, establishment of effective systemic therapies have resulted in revised therapeutic strategies. For obtaining better prognosis, optimal timing for introducing systemic treatments for BCLC stage B has been discussed, with the TACE concepts “refractoriness” and “unsuitable” recently proposed for responding to related clinical issues. Moreover, it has been reported that treatment with lenvatinib in combination with TACE might be more effective than use of lenvatinib alone. The present study was conducted to investigate factors related to clinical practice for HCC patients with BCLC stage B, especially those with Child-Pugh A, regarding the optimal timing for introduction of systemic treatments with the goal of improved prognosis.



Dr. Masao Honda

Department of Clinical Laboratory Medicine
Kanazawa University Graduate School of Medical Science
Department of Gastroenterology
Kanazawa University Graduate School of Medicine, Japan

Identification of Tumor Factors of Hepatocellular Carcinoma that Decrease the Efficacy of Immune Checkpoint Inhibitors

The recently developed combination therapy of atezolizumab (anti-PD-L1 antibody) and bevacizumab (anti-VEGF antibody) resulted in better overall survival for unresectable HCC. However, the efficacy is not satisfactory, therefore, it is now important to develop an effective combination therapy with ICIs and chemotherapy including biological drugs.

Based on GeneChip data analysis using surgically operated HCC tissue samples from 150 patients, we identified Gene X, a family member of forkhead box related protein, as a candidate gene in tumors that regulated intra-tumor TILs infiltration.

To examine the molecular functions of Gene X *in vivo*, we established liver tumor cell lines (MHCF1 and MHCF5) from hepatitis C virus transgenic mice (Gastroenterology 2002) fed an atherogenic high-fat diet. MHCF1 and MHCF5 efficiently developed orthotopic tumors in the liver of syngeneic C57BL/6 mice (Sci Rep. 2021).

We established the Gene X knock-out (KO) MHCF1 and MHCF5 tumor cells and analyzed the subcutaneous and/or orthotopic liver metastatic tumors in C57BL/B6 mice. Gene X-KO cells reduced tumor formation with increased immune cells and subsequently improved the mouse survival rates. We established ovalbumin (OVA) over expressed MHCF1 and MHCF5 (OVA-MHCF1 and OVA-MHCF5) as mimicking tumor antigen expressing cells. Adoptive T cell transfer obtained from OT-1 mice (Tg mice that express specific TCR against OVA) demonstrated that Gene X-KO OVA-MHCF1 or MHCF5 cells promoted the infiltration of OVA antigen-specific T-cells by approximately 10-fold than the WT OVA-MHCF1 or MHCF5 cells. Interestingly, OT-1 T cells did not increase the killing of Gene X-KO OVA-MHCF1 or MHCF5 cells *in vitro*, suggesting Gene X did not change the sensitivity of tumor cells to tumor antigen specific CTL *in vitro* but potentially modified tumor microenvironments and subsequently, reduced CTL infiltration into the tumors. In addition, we found Gene X-KO markedly improved the treatment efficacy by anti-PD-1 and anti-CTLA4 antibodies treatments.

Since Gene X is a transcriptional factor, we examined the Gene X target genes by combined analysis of ChIP-seq. and RNA-seq. We identified 4 candidate genes directly regulated by Gene X. Interestingly, one of 4 candidate genes was the receptor of growth factor. Interestingly, overexpression of the receptor in MHCF1 and MHCF5 formed gigantic tumor in mice, while suppression of the receptor decreased tumors substantially. Therefore, the growth factor could be an interest target for increasing anti-tumor efficacy of ICIs.



Dr. Masafumi Ikeda

Department of Hepatobiliary and Pancreatic Oncology,
National Cancer Center Hospital East, Japan

Treatment Strategy for Intermediate-stage HCC

Intermediate-stage hepatocellular carcinoma (HCC) is a very heterogeneous disease in terms of the number and size of tumors in the liver. Some guidelines recommend transarterial chemoembolization (TACE) alone as the standard of care for patients with intermediate-stage HCC. However, these patients often receive various treatments, including TACE, TACE combined with systemic therapy, or systemic therapy alone. The treatment strategy varies from country to country and from institution to institution, and no consensus has been reached yet. In my opinion, intermediate-stage HCC should be divided into the following 3 stages according to the best-applicable treatment strategy: curative-intent TACE stage, palliative-intent TACE stage, and systemic-therapy stage.

Curative-intent TACE stage is the stage at which patients can be treated by selective TACE; patients with ≤ 5 tumors and with tumor sizes of ≤ 5 cm are good candidates. Selective conventional TACE (cTACE) is recommended for these patients, and the estimated complete response (CR) rate at 3 months is 75%. cTACE alone may be sufficient for patients at this stage.

Palliative-TACE stage is the stage at which CR is difficult to achieve by TACE alone. Patients with ≥ 5 tumors and/or tumor diameters of ≥ 5 cm are good candidates. The goal is not to cure, but to prolong survival, and the estimated median survival of around 3 years. The treatment outcomes are not entirely satisfactory and further development of treatment is required, and new strategies, such as combined TACE plus systemic therapy are expected to be examined. In terms of the method of TACE, either cTACE or TACE with drug-eluting beads could be selected.

Systemic-therapy stage is the stage at which TACE is ineffective (so-called TACE-refractory stage). It is still controversial if patients who are unsuitable candidates for TACE should be included in this group. TACE is not recommended in these patients as it impairs the liver function and could be harmful, and systemic therapy, such as atezolizumab plus bevacizumab, is selected. Also, some promising investigational treatments, such as combined treatment with a multi-kinase inhibitor plus immune-oncologic (I-O) agent or a combination of two I-O agents could be good options.

Thus, intermediate-stage HCC can be divided into three stages depending on the best-applicable treatment strategy. In future, the boundary between the curative-intent TACE stage and palliative-TACE stage, and between the palliative-TACE stage and systemic-therapy stage should be clarified further.




Dr. Tatsuya Yamashita

Advanced preventive medical sciences research center, Kanazawa University
Department of Gastroenterology, Kanazawa University Hospital, Japan

Paradigm Shift with Drug Therapy in the Treatment of Intermediate-stage Hepatocellular Carcinoma

Transcatheter arterial chemoembolization (TACE) is the standard treatment for intermediate-stage hepatocellular carcinoma, but a paradigm shift is occurring due to recent advances in drug therapy. Many cases repeat recurrence even after TACE, the standard treatment for intermediate stage hepatocellular carcinoma, progresses to the advanced stage with vascular invasion and extrahepatic lesions, or the hepatic reserve gradually decreases. In the clinical course of such hepatocellular carcinoma, it is being discussed at what timing drug therapy should be introduced. Since the intermediate stage includes various pathological conditions in terms of tumor conditions and hepatic reserve, it has been proposed to consider drug therapy in cases where the effect of TACE cannot be expected by subclassing the intermediate stage. Up-to-7 criteria as tumor conditions and Child-Pugh score 7 as hepatic reserve are critical criteria in intermediate-stage subclassification. The criteria are also used in some clinical trials to develop TACE-drug combination therapy for intermediate-stage HCC. In addition, regarding the switch from TACE to drug therapy, the concept of TACE refractory/impossible TACE has been proposed and is gradually spreading. With the advent of drug therapies with higher antitumor effects such as lenvatinib and atezolizumab + bevacizumab combination therapy, the concept of TACE unsuitable has been proposed, and drug therapy without TACE is introduced to Intermediate stage hepatocellular carcinoma where the effect of TACE cannot be expected. However, there is no high-level evidence regarding the switch from TACE to drug therapy or the earlier introduction of drug therapy. Under these circumstances, several prognostic scoring models have been proposed overseas to select cases for which the therapeutic effect of TACE cannot be expected when starting TACE or re-treating TACE. A combination treatment of TACE and drug therapy is being developed in the intermediate stage, and some positive results have been reported. In addition, clinical trials have begun to develop a combination therapy of cancer immunotherapy and TACE using immune checkpoint inhibitors. Thus, due to the influence of advances in drug therapy for advanced hepatocellular carcinoma, a paradigm shift in the treatment of intermediate-stage hepatocellular carcinoma has occurred.



Dr. Naoya Kato

Professor and Chair at Department of Gastroenterology,
Graduate School of Medicine,
Chiba University, Japan


Treatment Strategy for Intermediate Stage HCC with Consideration of Maintaining Liver Function

In the BCLC staging system the 2022 update, not only TACE but also liver transplantation and systemic therapy were included as treatment options for the intermediate stage HCC¹). In fact, the standard treatment for HCC of well defined nodules, preserved portal flow, and selective access is TACE, while the standard treatment for HCC of diffuse, infiltrative, and extensive bilobar liver involvement becomes systemic therapy. In Japanese clinical practice manual for HCC recommends switching to systemic therapy rather than repeating TACE for HCC patients who are TACE refractory or TACE unsuitable. Repeated TACE in TACE-refractory or unsuitable situations is more likely to reduce liver function and shorten overall survival than systemic therapy²). Sequential therapy has clearly improved overall survival of the patients in advanced stage³). In multivariate analysis, the most influential factor on prognosis was liver function rather than sequential therapy. Similarly, in patients with HCC types B and C, control of HBV or eradication of HCV has improved liver function and clearly prolonged overall survival. Even in the intermediate stage, maintaining liver function is very important to maximize prognosis of the patients with HCC.

1) Reig M, et al. BCLC strategy for prognosis prediction and treatment recommendation Barcelona Clinic Liver Cancer (BCLC) staging system. The 2022 update. *J Hepatol.* 2021; S0168-8278(21)02223-6.

2) Ogasawara S, et al. Efficacy of sorafenib in intermediate-stage hepatocellular carcinoma patients refractory to transarterial chemoembolization. *Oncology.* 2014;87(6):330-41.

3) Kobayashi K, et al. Evolution of survival impact of molecular targeted agents in patients with advanced hepatocellular carcinoma. *Liver Cancer* 2021 (pub ahead of print).



Dr. Changhoon Yoo

Department of Oncology, Asan Medical Center,
University of Ulsan College of Medicine,
Seoul, South Korea

Systemic Therapy in the Intermediate Stage HCC: Current Evidence and Future Perspective

Current global guidelines recommend systemic therapy for the management of advanced stage or TACE-refractory or unfeasible intermediate stage HCC. As recently approved systemic therapeutic agents such as lenvatinib or atezolizumab plus bevacizumab showed higher response rates compared to sorafenib, systemic therapy may be used as a primary therapy in the intermediate stage HCC. Although there are the results based on the randomized clinical trials, recent evidence suggests the potential role of systemic therapy as a primary therapy of intermediate stage HCC. In this presentation, I will summarize the current evidence and future perspective of systemic therapy for the management of intermediate stage HCC.



Dr. Masatoshi Kudo

Department of Gastroenterology and Hepatology

Kindai University Faculty of Medicine

Osaka, Japan

Treatment Strategy of Intermediate-stage HCC: ABC Conversion Therapy

Atezo/Bev combination therapy was approved worldwide in 2020 following the positive results of the Phase 3 IMbrave150 trial. This therapy produces a high response rate in intermediate-stage HCC (i.e., ORR of 44% by RECIST 1.1).

Figure 1 shows the results of 73 patients who were followed-up for at least 12 weeks out of 92 patients and who received ABC conversion therapy (data cut-off date: July 31, 2021). Of 32 patients who received the Atezo/Bev therapy as first-line treatment, three (9%) underwent ABC conversion (surgical resection, RFA, and curative TACE in one patient each), and the three patients achieved cancer-free drug-free status. After including two cases of scheduled surgical resection and one case of scheduled curative TACE, the curative conversion rate becomes relatively high (19%). Moreover, if the analysis is limited to 17 intermediate-stage cases, the curative conversion rate is much higher (24%, Figure 1). Unlike molecular targeted agents, Atezo/Bev combination therapy produces marked tumor shrinkage in responders, even in those with highly malignant PET-positive HCC such as confluent multinodular type or poorly differentiated HCC. Consequently, surgical resection, ablation, or curative TACE become feasible, and pathological CR and drug-free status can be achieved in 20–30% of cases.

In the oncology field, once a systemic therapy is initiated, it will be continued if the systemic agent achieves a response of stable disease (SD) or better. This is particularly true when a partial response (PR) is achieved; in these cases, the therapy is not changed as long as PR continues. However, in HCC, especially in intermediate-stage HCC cases that remain locally advanced without vascular invasion or extrahepatic spread, other curative treatments are available, such as ablation or curative TACE in addition to resection, once marked tumor shrinkage is achieved. Thus, continuing the systemic therapy is not a good strategy. When a deep tumor response (marked tumor shrinkage) is achieved using Atezo/Bev combination therapy, curative conversion, rather than continuing sequential systemic therapy, must therefore be implemented without missing the best possible timing (i.e., while the deep response is maintained). The marked survival benefit in patients who are eligible for curative treatment is well known. Thus, for intermediate-stage HCC, the use of systemic therapy is based on a concept that is completely different from that of conventional sequential therapies in cases of advanced-stage HCC. In other words, systemic therapy should be introduced to achieve tumor shrinkage as induction therapy for curative conversion therapy.

An ORR of 44% per RECIST v1.1 was achieved using Atezo/Bev combination therapy in patients with intermediate-stage HCC. This means that nearly one in two of these patients can potentially achieve curative conversion. Thus, in patients with intermediate-stage HCC receiving Atezo/Bev combination therapy, curative conversion must be implemented as soon as possible without hesitation upon achieving a sufficiently deep response instead of continuing the systemic therapy until progressive disease (PD); real cure is not expected at this point. A pathological CR is rarely achieved with systemic treatment alone (e.g., lenvatinib or atezolizumab plus bevacizumab); residual viable cancer is often found when resection is performed in patients who seemed to achieve CR according to mRECIST. In such cases, recurrence is most likely to occur when the systemic therapy is discontinued; to prevent this, curative conversion must be implemented whenever possible even if imaging findings indicate CR or deep response. Of note, in patients who undergo resection as conversion surgery, bevacizumab needs to be discontinued at least 4–6 weeks before the procedure to prevent bleeding event, whereas a 3 week interval is sufficient when performing ablation or curative TACE. In either case, Atezo/Bev curative conversion can be achieved in approximately 20–30% of patients with intermediate-stage HCC.



Dr. Mina Komuta

Department of Pathology,

International University of Health and Welfare, School of Medicine, Narita
Hospital, Japan

Tumour Heterogeneity of HCC and its Clinical Relevance

Primary liver tumour is mainly composed of three types of tumours; hepatocellular carcinoma (HCC), intrahepatic cholangiocarcinoma (iCCA), and combined HCC-CCA. The latest 5th WHO classification subcategorizes iCCA into two groups, namely the large duct type and the small duct type. These tumours are completely different in terms of their clinical aspects, macroscopic findings, and patho-molecular features. In particular, recognition of small duct type iCCA is important as this tumour subtype harbours actionable mutations, such as IDH mutations and FGFR2 fusions. In fact, the result of clinical trials of IDH- and FGFR inhibitors is promising, therefore, this will certainly change the strategy of iCCA treatment. More importantly, pathologists can recognize the small duct type iCCA by using a microscope. The pathological investigation plays an important role in diagnosing tumours as well as identifying those patients who may benefit from the targeted therapy as described above. Another point is that liver transplantation is currently available for HCC, but not for iCCA or cHCC-CCA. This indicates that a distinction between HCC and non-HCC is essential.

Given that context, it is quite understandable that the pathological diagnosis should be done cautiously and properly; however, accurate diagnosis is not always straight forward. This is largely due to the fact that primary liver tumours show tumour heterogeneity. For instance, ductular configuration is one of the common aspects of the small duct type iCCA, however, this tumour structure can also be seen in cHCC-CCA, which makes it difficult to distinguish between them especially by using a needle biopsy. Another example is that K19 positive HCC can be misdiagnosed as cHCC-CCA or even iCCA because of overestimation of K19 expression.

Based on these aspects, I will focus my talk on the pathological features of HCC, iCCA and cHCC-CCA, including their diagnostic pitfalls and clinical relevance. My lecture could be useful for those who are dealing with liver tumour diagnosis and treatment on a daily basis or those who have a general interest in liver tumour pathology.



Dr. Michiie Sakamoto

Department of Pathology,
Keio University School of Medicine, Japan

Pathological Features of Tumor Microenvironment of HCC

The precise pathology diagnosis of HCC is crucial to achieve improvements in prognosis of HCC. It is becoming clear that not only tumor itself but also tumor microenvironment in HCC seems quite heterogeneous. Vascular stroma changes during progression from early to advanced HCC corresponding to transition from hypo-vascular to hyper-vascular on imaging have been shown. Fibrous stroma is rather rare in HCC, while scirrhous HCC is recognized as a subtype of HCC. Immune cell profile in HCC is also getting more attention due to the rapid progress of immunotherapy in many types of cancer. Immune hot tumors seem relatively rare in HCC, while they have better prognosis than cold tumor. Interestingly these stromal features seem to have an additional impact as well as some association with molecular subclass of HCC. Accumulating evidences indicate CTNB1 mutation is strongly associated with lower lymphocytic infiltration and less response to immunotherapy. Moreover, recent clinical data have shown that targeting both anti-tumor immunity and tumor angiogenesis achieves favorable outcome, suggesting close interaction between them. I will overview these pathological features of tumor and tumor microenvironment and discuss how they can be applied in pathology diagnosis of HCC.



Dr. Hidewaki Nakagawa

RIKEN Center for Integrative Medical Sciences,
Laboratory for Cancer Genomics, Japan

Genomic Structures and Carcinogenesis of HBV Integrations in Liver Cancer

Integrations of Hepatitis B virus (HBV) in human genome can cause genetic damage and chromosomal instability, leading to selective advantage on HBV-induced liver cancer. We conducted ultra-deep sequencing targeting HBV integrations in human liver cancers, hepatitis tissues, and human-hepatocyte chimeric mice. HBV infection model suggested that HBV integration could occur between 23-49 days after HBV infection, mediated by microhomology-mediated end joining, and predominant in mitochondrial DNA (Furuta, et al. *Oncotarget* 9: 25075, 2018). Overall HBV integration sites in clinical samples were significantly enriched in regions annotated as exhibiting open chromatin, a high level of gene expression, and/or early replication timing in liver cells, indicating that HBV integration maintained in liver tissue was biased according to chromatin accessibility with additional selection pressure in gene promoters such as TERT gene (Fujimoto et al. *Nat. Genet.* 48: 500, 2016). Furthermore, whole genome sequencing analysis by long-read Oxford Nanopore technologies (ONT) on liver cancer genome demonstrated that HBV genome integration caused dramatic changes in its configuration, such as chromosomal rearrangements and megabase-size telomeric deletions including cancer driver genes such as TP53 and ARID1A (Alvarez, et al. *Nat. Commun.* 12; 6910, 2021). Broad surveys of HBV integrations facilitate and improve the understanding of both the timing and biology of HBV integration during infection and HBV-related hepatocarcinogenesis.



Dr. Young Nyun Park

Department of Pathology, Yonsei University of Health System, Severance Hospital, Seoul, Korea

Update in HCC Pathology

Hepatocellular carcinoma (HCC) is heterogeneous in moleculopathological features and biologic behavior. Large-scale genetic studies of HCC have been accumulated, and a pathological-molecular classification of HCC has been proposed. According to updated WHO Classification of Digestive System Tumors 5th edition, about 35 % of HCCs can be classified into distinct histopathological subtypes according to their molecular characteristics. Among the recently identified subtypes, macrotrabecular massive (MTM)-HCC, neutrophil-rich HCC, vessels encapsulating tumor clusters (VETC)-HCC, and progenitor phenotype HCC (HCC with CK19 expression) are associated with poor prognosis, and lymphocyte-rich HCC subtype is related to better prognosis.

HCC with K19 expression, 4–28% of HCCs shows clinical characteristics of higher serum alpha-fetoprotein (AFP) levels, frequent association with chronic hepatitis B, and lymph node metastasis. Histomorphologically, K19-positive HCCs demonstrate a more infiltrative growth, poor differentiation, more frequent vascular invasion, and more intratumoral fibrous stroma than K19-negative HCCs. From the molecular aspect, K19-positive HCCs have been matched with various gene signatures associated with stemness and poor prognosis, including the G1 group, S2 class, cluster A, proliferation signature, vascular invasion signature, and cholangiocarcinoma-like gene expression trait. K19-positive HCCs also show upregulated signatures related to transforming growth factor- β pathway and epithelial-to-mesenchymal transition (EMT). The main regulators of K19 expression include hepatocyte growth factor-MET paracrine signaling by cancer-associated fibroblast, epidermal growth factor-epidermal growth factor receptor signaling, laminin, and DNA methylation. K19-positive HCCs are characterized by increased telomere length, increased expression of hTERT and shelterin complex proteins, and increased chromosomal instability compared to K19-negative HCCs.

MTM-HCC, 5–20% of HCCs shows macrotrabeculae (> 6~10 cells in thickness) in at least 50% of the tumor. The molecular feature of this variant is characterized by frequent TP53 mutation, FGF19 amplification and angiogenesis activation including high ANGPT2 mRNA levels. MTM-HCCs show frequent HBV infection, frequent vascular invasion, poor differentiation, CK19 expression, high serum AFP levels and a poor clinical outcome.

VETC-HCC, about 19% of HCCs shows high serum AFP levels, larger tumor size, poor differentiation, macrotrabecular pattern, and frequent vascular invasion. This novel vascular pattern promotes metastasis of HCC in an EMT independent manner. In the context of low androgen receptor (AR) expression, upregulated Angpt2 induces vascular remodelling, leading to VETC-mediated metastasis. In contrast, under conditions of high AR expression, upregulated Rac1 induces lamellipodia formation, resulting in invasion-mediated metastasis. Interestingly, VETC-HCC and MTM-HCC show a tendency of pulmonary metastasis, in contrast to lymph node metastasis in HCC with K19 expression.



Dr. Shinichi Aishima

Pathology & Microbiology, Faculty of Medicine, Saga University
Japan

Morphological Subtypes of Hepatocellular Carcinoma

Hepatocellular carcinoma (HCC) is derived from hepatocytes or their precursors. Recent advances in tumor genomics and transcriptomes have identified several somatic/genetic alterations that are closely related with histological subtypes. Morphological heterogeneity and distinct subtypes of HCC are now classified based on the clinical characteristics, morphological features and molecular abnormalities.

Steatohepatitis HCC is characterized by tumor cells with histologic features resembling steatohepatitis, such as Mallory-Denk bodies and/or ballooning, and pericellular fibrosis. Many cases of steatohepatitic HCC arise in the setting of nonalcoholic steatohepatitis and alcoholic steatohepatitis with obesity, hypertension and/or diabetes, but other cases arise in absence of fatty liver disease or metabolic syndrome. Steatohepatitic subtype show frequent IL6 / JAK / STAT activation. Macrotrabecular HCC is characterized by >50% growth of macrotrabecular pattern and show aggressive biological behavior. Macrotrabecular subtype is related with TP53 mutation and FGF19 amplification. Clear cell change with glycogen accumulation was occasionally observed in conventional HCC. Chromophobe type has tumor cells with clear cytoplasm and bland nuclei. Discrimination between clear cell type and chromophobe type is difficult. Fibrolamellar carcinoma occurs in non-diseased liver of young median age. Tumor cells with pale bodies or distinct nucleoli together with lamellar fibrotic stroma confirm a diagnosis of fibrolamellar carcinoma. Tumor cells of fibrolamellar carcinoma is positive for CK7 and CD68. Recurrent genomic abnormalities typically involving DNAJB1-PRKACA fusion gene are detected. Scirrhouis type is defined as the tumor containing dense intratumor fibrosis and mimics cholangiocarcinoma on imaging. Scirrhouis subtype often show biliary phenotype in immunohistochemistry and is associated with TSC1 / TSC2 mutations. Neutrophil-rich or lymphocyte-rich subtypes are rare. Neutrophil-rich type shows worse prognosis, while lymphocyte-rich type shows better prognosis.

Several subtypes of HCC have been proposed. To brush up the definition and the classification of HCC may contribute to the treatment selection and prediction of prognosis.



Dr. Kazuomi Ueshima

Department of Gastroenterology and Hepatology,
Kindai University Faculty of Medicine, Japan

Mechanism of Resistance to Immunotherapy for Hepatocellular Carcinoma

Atezolizumab bevacizumab, combined immunotherapy, is now the first-line treatment for hepatocellular carcinoma. It is characterized by a high response rate and long duration of response in responders, and this combined immunotherapy is currently widely used. On the other hand, there are some cases in which hyper progression is observed as the primary resistance, or there are many cases in which even if once respond, the effect gradually diminishes as the secondary resistance. Research on this mechanism is progressing, and it has been suggested that the Wnt / β catenin pathway mutation is involved or that the tumor microenvironment is involved. In this session, I will talk about the mechanism of drug resistance of immunotherapy in hepatocellular carcinoma in IO monotherapy and combined immunotherapy, respectively.



Dr. Sadahisa Ogasawara

Department of Gastroenterology,
Graduate School of Medicine, Chiba University, Japan

Dramatic Transformation of Treatments in Patients with Advanced Hepatocellular Carcinoma

Systemic therapies of advanced hepatocellular carcinoma (HCC) have passed through the era of multi-molecular target agents, and the era of combined immunotherapy has arrived as the mainstay of treatment. An open-label randomized phase III study (IMbrave 150 trial) comparing the combination of atezolizumab and bevacizumab with sorafenib in advanced-stage HCC patients as a first-line therapy demonstrated an improvement in the overall survival using the combination of atezolizumab and bevacizumab. The guidelines are being updated around the world based on the result of the IMbrave 150 trial, with atezolizumab plus bevacizumab positioned as the standard first-line systemic therapy option. Upon entering the era of combined immunotherapy, several new clinical issues of advanced HCC have been identified. First, second, or later lines of treatment after failure of or intolerance to the first-line atezolizumab plus bevacizumab has not been established in patients with advanced HCC. The other clinical challenge is the identification of a population that is expected to be an effective combination immunotherapy in patients with advanced HCC.

Session 5: Oncoimmunotherapy for HCC



Dr. Thomas Yau, China

Clinical Associate Professor in Medical Oncology
Department of Medicine, Li Ka Shing Faculty of Medicine,
The University of Hong Kong, China

To be announced.



Dr. Takuto Nosaka

Second Department of Internal Medicine,
University of Fukui, Japan

Leukotrienes Derived from Tumor-Infiltrating M2 Macrophages Promote the Progression of Hepatocellular Carcinoma

Background: Leukotrienes (LTs), which are metabolized from arachidonic acid by 5-lipoxygenase (5-LOX), have been involved in cancer development and metastasis. We reported a mechanism by which alveolar macrophage-derived LTB₄ promotes the development of lung metastasis of hepatocellular carcinoma (HCC) (J Immunol. 2018). However, the functional role of LTs in HCC remains to be elucidated. In this study, we analyzed the contribution of LTs to HCC progression in mouse models and clinical specimens to investigate the potential of LTs for targeted therapy.

Methods: An HCC mouse model was established by inoculating a mouse HCC cell line (BNL) into the portal vein of Balb/c mice and collected 17 days later. 5-LOX inhibitors or clodronate liposomes (CLLs) were administered intraperitoneally after tumor injection. Immunostaining for 5-LOX, Ki-67, CD90, and CD133 was performed on HCC tissue specimens from 88 patients of surgical resections or mouse model. In the HCC tissue, fluorescence multiplex staining was performed to identify 5-LOX-positive cells and the amounts of LTs were measured by ELISA. Proliferative and stem cell potentials were assessed by MTT assay, sphere formation assay, and quantitative PCR.

Results: 5-LOX-positive cells were increased in HCC compared to normal and cirrhotic livers. Immunostaining of 5-LOX in resected HCC tissue showed that patients in the high 5-LOX group had a significantly poorer postoperative recurrence and overall survival (OS) than those in the low 5-LOX group (median OS: 34.3 vs. 114.0 months, $p < 0.05$). In the HCC mouse model, 5-LOX inhibitor significantly suppressed tumor growth (tumor weight: 0.7 vs. 0.4 g, $p < 0.05$) and decreased the number of Ki-67, CD133, and CD90 positive tumor cells. In vitro, LTs metabolized by 5-LOX promoted the proliferative activity, stem cell function, and increased gene expression of OCT4, c-MYC, and NANOG of HCC cell lines ($p < 0.05$). Moreover, fluorescence multiplex staining revealed that intra-tumor CD163-positive M2 macrophages expressed 5-LOX. Depletion of macrophages with CLLs reduced the number of 5-LOX-positive cells and the amounts of LTB₄ and LTC/D/E₄, and suppressed tumor growth ($p < 0.05$).

Conclusion: In the microenvironment of HCC, it was revealed that LTB₄ and LTC/D/E₄ produced by M2 macrophages enhance the proliferation and stem cell function of cancer cells. Furthermore, inhibition of LT production may suppress tumor progression and is expected to be clinically applied as a new therapeutic strategy for HCC.



Dr. Takahiro Kodama

Department of Gastroenterology and Hepatology,
Osaka University Graduate School of Medicine, Japan

Multomics Profiling Identifies the Link between Intra-tumor Steatosis and Immune-exhaustion in Non-viral HCC

Background: Incidence of non-viral hepatocellular carcinoma (HCC) has increased rapidly but its molecular and immunological features have not been fully characterized. We thus performed the molecular and immunological profiling of non-viral HCCs through multi-omics approach.

Method: We performed RNA-sequence of tumor tissues in 113 non-viral HCC patients who underwent curative surgical resection. For 55 tumors, we further sequenced cancer genomes using gene panels focusing on 69 genes in which recurrent genetic alterations were reported in HCC. Intratumoral abundances of immune cell types were estimated by CIBERSORT analysis of transcriptomic data. Spatial transcriptome sequence was performed in the 10x Genomics Visium platform to define the spatial topography of gene expression in non-viral HCC tissues.

Results: Clinically, heavy drinker was significantly associated with poor prognosis. Unsupervised hierarchical clustering of tumor transcriptomes classified non-viral HCCs into 3 molecular classes (Class I, II, III), which were not associated with etiology of background liver disease but stratified patient prognosis. Class I with the poorest prognosis had significantly higher rate of TP53 mutations, class III with the most favorable prognosis showed the immune-excluded phenotype with frequent CTNNB1 mutations. Profiling of tumor infiltrating immune cells with CIBERSORT analysis identified that M2 macrophage infiltration was significantly associated with poor prognosis. The multivariate Cox proportional hazard analysis identified heavy drinker, M2 macrophage infiltration and class I were all independent predictors of poor prognosis in non-viral HCCs. Among class II, we identified a subclass with tumor-promoting immunity characterized by T cell exhaustion, CD163+ M2 macrophage and α SMA+ fibroblast infiltration, high PD-L1 surface expression of tumor cells, and TGF- β signaling activation. Pathologically, this subclass was characterized by intratumoral steatosis and lipidomics-based intratumor free fatty acid profiling showed the increase in palmitic acid (PA) in this subclass. Lipid accumulation by PA supplementation in HCC cells upregulated PD-L1, CXCL8, CSF1 and TGF- β expression in vitro. Furthermore, lipid-accumulated HCC cells promoted M2 polarization of co-cultured macrophages and upregulated TGF- β expression of co-cultured fibroblasts. Spatial transcriptomics of steatotic HCCs suggested that CD163+ M2 macrophages and VIM+ cancer-associated fibroblasts may produce TGF- β and induce exhaustion of surrounding CD8+ T cells.

Conclusions: Multomics profiling identified the subclass with tumor-promoting immunity in non-viral HCCs and suggested that pro-tumoral immune networks may be furnished in the steatotic tumor microenvironment.



Dr. Toshio Miki

Department of Physiology,
Nihon University School of Medicine, Japan

Placental Stem Cell Transplantation Prevented Disease Development in Ornithine Transcarbamylase Deficiency Model Mice

Stem cell-derived hepatocyte transplantation may be an ideal approach for pediatric metabolic liver diseases such as Ornithine transcarbamylase (OTC) deficiency. Human amniotic epithelial cells (hAECs) are one of the neonatal stem cells and have been shown to express hepatic genes and enzymes upon engraftment in mouse liver. Here we report that liver-directed hAEC transplantation partially restored the OTC enzyme function and improved disease phenotypes. The OTC-deficiency model mice treated with hAECs had increased OTC enzymatic activity in the liver and better-tolerated ammonia challenge compared to untreated controls. The presence of human mitochondria in the recipient mouse liver was demonstrated with immunohistochemistry while anti-human nuclei marker positive cells were not detected. To determine the cause of this discrepancy, we further transplanted hAECs which were genetically labeled cytoplasm with GFP and co-labeled mitochondria with DsRed, into mouse liver and found the possibility of intracellular mitochondria transfer. In vitro studies demonstrate that nanotube-dependent intracellular mitochondria transfer between hAEC and OTC deficient mouse hepatocytes. Our findings suggest a novel mechanism of hAEC-mediated therapeutic efficacy that transplanted hAECs differentiate to hepatocyte-like cells and distribute hepatic mitochondria to neighboring OTC deficient mouse hepatocytes to restore the ammonia metabolism function.



Dr. Yuji Iimuro

Department of Surgery, Yamanashi Central Hospital,
Yamanashi, Japan


Minimal Invasive Hepatectomy in the Post-SVR Era

Background and Aim: Sustained virological response (SVR) following treatment with direct-acting antivirals (DAA) significantly decreases the incidence of hepatocarcinogenesis in HCV-positive patients. Recently, we have adopted laparoscopic hepatectomy as the first treatment choice for HCCs which appear after DAA-induced SVR. In the present study, we analyzed the relevance of our treatment strategy.

Methods: Incidence of HCC occurrence and prognosis after treatment were analyzed in 612 HCV-positive patients who achieved SVR with DAA in our hospital between 2016 and 2020.

Results: HCC appeared in 48/612 (7.8%) after SVR. Concerning HCC history before DAA treatment, HCC occurred in 21 out of 34 history-positive (61.8%) and 27 out of 578 history-negative patients (4.7%). Treatment choice for 48 HCC patients was surgical resection:22, curative RFA:16, and others:10, respectively. Laparoscopic hepatectomy was employed in 13/22 patients (59%). We compared treatment efficacy between surgical resection (22) versus curative RFA (16). RFS at 1, 3, 5 year was 86%/63%, 66%/47%, 66%/28% in resection/RFA, respectively ($p=0.107$). OS at 1, 3, 5 year was 100%/100%, 87%/93%, 87%/82% in resection/RFA, respectively. Focusing on 22 patients without HCC history before SVR (14/8; resection/RFA), RFS and OS at 1, 3, 5 year was 92%/63%, 76%/50%, 76%/33% ($p=0.088$), and 100%/100%, 100%/100%, 100%/80% in resection/RFA, respectively. As for liver function after SVR achievement, s-Alb, PT%, Plt, and WBC significantly had improved when HCC resection was performed. From a view point of resection approach, intraoperative bleeding and post-surgical hospital stay are smaller in laparoscopic resection compared to open surgery in our other surgical cohort, consistent with recently reported safety and efficacy of laparoscopic hepatectomy (Ban, et al. *Annals of Surgery* 2020).

Conclusion: Relatively good RFS was observed after surgical resection in HCC patients after SVR with DAA, especially in patient without pre-HCC history. Considering recent advance in technique and safety in laparoscopic hepatectomy as well as improvement of liver function after SVR, our treatment strategy for post-SVR HCC is possibly relevant.



Dr. Masayuki Ohtsuka

Department of General Surgery,
Graduate School of Medicine, Chiba University, Japan

Surgery for Perihilar Cholangiocarcinoma: Resection and Transplantation

Currently, surgical resection with negative surgical margins (R0 resection) is believed to be the best treatment option for perihilar cholangiocarcinoma (PHCC). Therefore, all patients with “resectable” PHCC who have acceptable performance status and liver function are appropriate candidates for radical resection. However, “resectable” PHCC has not been clearly defined, so that the indications for resection vary widely among centers around the world. Traditionally, PHCCs of Bismuth type IV and Blumgart T3 have been considered unresectable. However, with recent improvements in surgical techniques and perioperative management, the indications for resection of PHCC have expanded, and these advanced tumors are no longer necessarily considered unresectable. Although extensive hepatic resection, such as left trisectionectomy, and combined vascular resection and reconstruction are often required for the resection of Bismuth type IV and Blumgart T3 PHCCs, these procedures are feasible and can be performed relatively safely in specialized centers, achieving 5-year survival rates of 30-40%, and even 40-50% when patients have pN0M0 disease.

Alternatively, liver transplantation has become an attractive option for the treatment of PHCC in the United States and Europe. Theoretically, liver transplantation can overcome extensive infiltration of the bile ducts, where R0 resection cannot be achieved, without considering the remnant liver function, and also can cure from background parenchymal damage, especially from primary sclerosing cholangitis (PSC). According to recent data from the Mayo group, 5-year survival rate after transplantation is 62% for all patients and 49% for de novo PHCC patients, indicating that transplantation is certainly effective for some PHCC patients. However, these excellent results are based on the Mayo protocol, including strict patient selection, aggressive neoadjuvant therapy, and operative staging prior to transplantation. Only patients with early-stage PHCC arising in PSC and “unresectable” “early-stage” PHCC arising de novo are eligible to this protocol. In this protocol, “unresectable” “early-stage” de novo PHCC is defined as PHCC less than 3cm in radial diameter without evidence of lymph node metastases, which is likely to be very limited in clinically experienced PHCCs. Because of favorable outcomes of liver transplantation for PHCC, some transplant surgeons believe that liver transplantation is more effective than resection, and that indications for liver transplantation should be expanded to include patients with “resectable” PHCC. However, there are still insufficient data comparing the survival of PHCC patients after transplantation and resection, and more prospective studies are needed to clarify the indications for liver transplantation in PHCC patients.



Dr. Washim Jafri

Gastroenterology Hepatology,
Aga Khan University Karachi, Pakistan

Management of Hepatocellular Carcinoma “Current Therapeutic Options”

Due to effective screening the incidence of HCC is on the rise. HCC is a universal health burden due to the rapidly rising mortality rate associated with it. According to the latest numbers, it is estimated that its incidence will continue to grow. It is crucial to devise therapeutic strategies that could control the disease and prolong the survival of patients. Fortunately, systemic therapy has advanced rapidly over the past few years. However, the advent of immunotherapy has proven to be a game changer. The role of genomic and adoptive cell therapy is still unclear. A lot of in-depth research is therefore needed to further enhance our perception of the disease at molecular and genetic levels, in order to explore new treatment options for HCC.



Dr. Etsuro Hatano

Department of Surgery, Graduate School of Medicine,
Kyoto University, Japan

Proposal of Resectability for Hepatocellular Carcinoma for Future Clinical Trial

Backgrounds: In the era of multidisciplinary approach and/or multiple choice of treatments, resectability for HCC should be defined. This study aimed to propose a resectability classification of hepatocellular carcinoma (HCC).

Methods: We proposed following the three groups; resectable-(R), borderline resectable-(BR) and unresectable (UR)-HCCs. Resectable groups were sub-divided according to the value of indocyanine green clearance of remnant liver (ICG-Krem) and presence of macrovascular invasion (MVI); BR-HCC was defined as resectable HCCs with MVI and/or ICG-Krem ≥ 0.03 and < 0.05 and R-HCC was the remaining. Two-hundred ninety-eight patients with HCC who underwent liver resection (LR) between 2011 and 2017 were retrospectively analyzed to validate the proposed classification. Sixty-four patients with UR-HCC were used as a control subject.

Results: In patients with resected HCC, ICG-Krem ≥ 0.05 was associated with decreased risk of clinically relevant postoperative liver failure ($p=0.013$) and presence of MVI was associated with worse overall survival (OS) ($p<0.001$). 3- and 5-year OS rates according to the proposed classification were 80.3, and 68.3% vs. 51.4, and 35.6%, in the R and BR groups, respectively (both $p<0.001$). Multivariate analysis showed BR-HCC was independently associated with poorer OS ($p<0.001$) after adjusting for known tumor prognostic factors. Meanwhile, BR-HCC was associated with benefit in terms of OS compared with UR-HCC ($p<0.001$).

Conclusion: Our proposal of resectability for HCC allows for stratifying survival outcomes of HCC and maybe useful for future clinical trial.



Dr. Mureo Kasahara

National Center for Child Health and Development, Japan

Hepatoblastoma Management: From Resection to Transplantation

Mureo Kasahara, Akinari Fukuda, Seisuke Sakamoto

National Center for Child Health and Development

Recently, liver transplantation (LT) has been increasingly performed for unresectable hepatoblastoma (HB) with acceptable results. Anatomic resection or transplantation following adequate chemotherapy for PRETEXT III/ IV patients has been recommended for optimal outcome.

However, hepatoblastoma with extrahepatic involvement (such as lung and peritoneal dissemination) or with tumor thrombi extending into portal vein/ inferior-vena-cava are challenging. The meticulous surgical approach is technically demanding and might require major liver resection or transplantation with vascular reconstruction and extracorporeal circulation.

We, herein, report cases with liver resection and transplantation for advanced hepatoblastoma with peritoneal dissemination, with extended tumor thrombi into right atrium. Patient selection, preoperative evaluation of the anatomy as well as intraoperative assessments are essential to achieve sufficient outcome. Our findings justify further investigation to identify the optimal hepatectomy or transplant management for children with HB.

Session 7: HCC in Asia, Epidemiology (1)



Dr. Lai Wei

Dean and Professor

Hepatopancreatobiliary Center

Beijing Tsinghua Changgung Hospital

School of Clinical Medicine, Tsinghua University, Beijing, China

To be announced.



Dr. Manoj K. Sharma

Institute of Liver and Biliary Sciences (ILBS),
New Delhi, India

Epidemiological Aspects of HCC Prevention in Asia-Pacific

According to WHO, worldwide, liver cancer accounted for 4.7% of all new cancer cases, and 8.3% of all cancer related deaths in 2020. In 2020, Asia contributed to 3/4th of the liver cancer cases worldwide with regards to incidence, mortality and 5 year prevalence is concerned [1].

Liver related deaths contribute to variable proportion of overall deaths in Asia-Pacific (<3% to >6% across various countries). Asia-Pacific contributes to 2/3rd of global liver disease related deaths, 3/4th of liver cancer related deaths and 80% of HBV related liver cancer deaths [2]. Liver cancer accounts for 40% of liver related death in Asia-Pacific [2,3].

There are various risk factors for liver cancer, HBV, HCV, alcohol, NASH being common ones. Chronic hepatitis B virus infection is responsible for more than half of the deaths due to liver cancer in the Asia-pacific.

HBsAg and anti-HCV prevalence are declining through decades, but still there is high HBV and HCV burden in the Asia-Pacific. NAFLD prevalence has been increasing through decades in the Asia-Pacific. Alcohol per capita consumption increased in the WHO Western Pacific and South-East Asia regions in the last decade [4].

Strategies to prevent HCC include primary prevention against new cases of viral hepatitis, secondary prevention of HCC in susceptible individuals. Most important interventions of primary prevention include HBV immunization, reduce aflatoxin exposure, reduce alcohol use and reduce NAFLD/obesity. Most important secondary prevention measures include treating viral hepatitis.

Universal hepatitis B vaccination has resulted in dramatic reduction in incident cases of chronic hepatitis B and HCC in children and adolescents, as found in Taiwan. Also, immunization of infants against HBV reduces their risk of developing HCC as children and young adults [5].

There is a lower liver cancer risk with antiviral therapy in chronic hepatitis B (including patients with even normal to minimally elevated ALT and no cirrhosis) [6]. Similarly HCV eradication induced by direct-acting antiviral agents reduces the risk of hepatocellular carcinoma [7].

Aflatoxin B1 is one of the most potent natural carcinogens, found in village grain stores in many south East Asian countries. Aflatoxin exposure may account for HCC incidence variations in many areas of high HCC incidence. Measures taken to decrease aflatoxin exposure (like hand sorting, sun drying, drying on mats, storage in natural fiber bags, use insecticides etc) can lead to increase in the number of individuals with undetectable aflatoxin albumin adducts [8].

The WHO's Global Health Sector Strategy on viral hepatitis (2016) aims for elimination of viral hepatitis as a major public health threat by 2030 (i.e, 90% reduction in incidence and 65% in mortality) compared with a 2015 baseline [9]. Countries that have not yet reached the 2020 goal of 1% HBsAg prevalence among under 5 children through vaccination should focus on increasing their vaccination coverage, including timely birth dose. Countries that have already scaled up the timely birth dose, adding antenatal HBsAg testing of pregnant women and tenofovir prophylaxis in eligible women as an additional opportunity to prevent mother to child transmission may be cost effective in some regions.

Obesity and NAFLD, although traditionally thought of as diseases of high-income countries, are increasingly recognised and have become epidemic in all countries of the Asia-Pacific region, irrespective of income status. The political declaration of the high-level meeting of the United Nations General Assembly on the prevention and control of non-communicable diseases (NCDs) mandated the development of a global monitoring framework, including indicators, and a set of voluntary global targets for the prevention and control of NCDs. Following the declaration, WHO developed a global monitoring framework to enable global tracking of progress in preventing and controlling major NCDs. This work yielded a set of nine voluntary targets for 2025; and a set of 25 indicators [10]. NAFLD has been incorporated in the National NCD prevention programme of India in Feb 2021.



Dr. Wan-Long Chuang

Hepatobiliary Division, Department of Internal Medicine,
Kaohsiung Medical University Hospital,
Kaohsiung Medical University, Taiwan

Changing Epidemiology of Hepatocellular Carcinoma in Taiwan

Taiwan is a hyperendemic country of hepatitis B virus (HBV) and hepatitis C virus (HCV) infection. The prevalence of HBsAg is around 15% to 20%, and the prevalence of anti-HCV is between 4 to 8% in adults of Taiwan. Because HBV and HCV infection could lead to chronic hepatitis, liver cirrhosis and hepatocellular carcinoma (HCC), HCC becomes one of the major health problems in Taiwan. The HBV accounted for 80 to 85% in the causes of HCC, while HCV infection was found in 10 to 20% of HCC patients in 1990s. Universal hepatitis B vaccination was launched in 1984, and the national viral hepatitis therapy and surveillance program was conducted since 2003. The pegylated interferon and nucleos(t)ide analogs were reimbursed for chronic HBV infection and the pegylated interferon combined with ribavirin was provided for chronic HCV infection (all oral direct acting antiviral agents were reimbursed from 2017). The incidence and mortality of HCC decreased in recent 10 years. There was a continuous decline in age- and sex-adjusted rate ratios of HCC mortality and HCC incidence for birth cohorts born after implementation of the HBV vaccination program. Treatments for chronic HBV infection and chronic HCV infection are associated with lower incidence of HCC. The prevalence of HBsAg decreases approximately to 50 % and the prevalence of anti-HCV is about 40% to 50% in HCC patients after 2010s. The government of Taiwan aimed to eliminate the HCV infection before 2025 in Taiwan. The incidence and mortality of HCC will be further decreased in near future.




Dr. Mamun-Al Mahtab

Interventional Hepatology Division, Department of Hepatology
Bangabandhu Sheikh Mujib Medical University, Bangladesh

The Magnified Challenge of HCC in Bangladesh in the Context of COVID-19 Pandemic

HCC remains a major concern in Bangladesh as a leading cause of death, as in many other countries of the Asian Pacific region. It has been ranked third amongst the cancer related mortalities in Bangladesh. Of the twenty thousand plus Bangladeshis dying of liver diseases every year, it can be safely said that a significant portion of them die of HCC. It has been estimated that patients with hepatitis B related HCC contract the deadly disease much earlier in Bangladesh than in most parts of the world, not to say that almost 90% of them present with very advanced disease. There is gap in HCC screening and Hepatology services in Bangladesh compared to the huge demand and during the COVID-19 pandemic, when like elsewhere we also had to divert our resources to tackle the new menace, our already inadequate capabilities for early diagnosis and management of HCC has suffered greatly. In this contest and from our experience of handling SARS-CoV-2, we now have to emphasize on creating mass awareness about HCC in the new normal era if we are to close the gap and save many more thousands from untimely HCC related deaths in Bangladesh.



Dr. Saeed Hamid

Professor and Director, Clinical Trials Unit,
Aga Khan University, Pakistan

HCC Caused by Hepatitis Delta Virus Infection in Asia-Pacific

Hepatitis Delta is the severest form of viral hepatitis known to man. There are a number of hot spots for HDV infection in Asia-Pacific, including Pakistan, Mongolia and countries of Central Asia. Often younger people are affected and develop complications of liver disease at a very young age. Development of cirrhosis leads to HCC in many of these patients, which seems to be more aggressive than HCC relate to HBV mono-infection. This talk will focus on the prevalence and clinical profile of patients with HBV/HDV infection with particular reference to HCC in these patients.



Dr. Teerha Piratvisuth

Faculty of Medicine, NKC Institute of Gastroenterology and Hepatology
Prince of Songkla University, Thailand

Epidemiology Hepatocellular Carcinoma (HCC) in Thailand

Hepatocellular Carcinoma (HCC) is one of common malignant tumor worldwide ranged as the sixth cancer entity and the third cause of cancer death. HCC is the second most common cancer and the leading cause of cancer- death in Thailand. The age-standardized incidence rate is 34.8-38.6 and 11.3-14.6 per 100,000/year in Thai men and women, respectively. The implementation of a universal HBV immunization in 1992 in Thailand results in decreased incidence rate of HCC in last 2 decades. HBV is the most common cause of HCC (50% of HCC patients) followed by HCV, alcohol, and NASH in 16%, 14% and 11%, respectively. Hepatomegaly, liver mass and clinical of cirrhosis are the major features of patients with HCC. However, about 24% of the patients are asymptomatic at the time of diagnosis of HCC.

Majority of the patients present at the late stage of HCC. Approximately, 2/3 of HCC patients have BCLC stage B and C at the time of diagnosis. Moreover, 25% of the patients have terminal stage (BCLC stage D) at the first diagnosis. Implementation of HCC surveillance with biannually ultrasound leads to diagnosis of HCC at earlier stage which are eligible for curative treatment. Noteworthy, about 29% of Thai HCC patients have AFP <200 ng/mL. The economic study done in Thailand reported that HCC surveillance in patients with chronic hepatitis B is cost-effective. The policy to increase awareness among the physicians and population regarding HBV vaccination and HCC surveillance as well as treatment of chronic liver disease would improve the prevention, treatment, and outcomes of HCC.



Dr. Rino Gani

Hepatobiliary Division Department of Internal Medicine,
Universitas Indonesia,
Cipto Mangunkusumo Hospital Jakarta – Indonesia

Hepatoma in Indonesia : Immunology Point of View

Rino A Gani, Irsan Hasan

Hepatocellular carcinoma is still a major health problem in Indonesia. This cancer was ranked 5th as the most prevalent cancer in males and ranked 9th in females across all cancers in Indonesia. Patients with BCLC C treated with TKI monotherapy or in combination with immunotherapy. Immunohistochemistry of resection samples from our patients showed beta-catenin positives were among the minority of our HCC patients. Mutation in beta-catenin pathways may increase the proliferation of HCC and inhibition of beta-catenin pathways have been shown to be synergistic with sorafenib that suppresses the ability of HCC cells to proliferate further. This strategy may be beneficial in our HCC patients. Most immunotherapy used in HCC was an immune checkpoint inhibitor. PD-1 inhibitors and CTLA-4 inhibitor showed promising results. Lymphocyte T cells have been a major focus on immune checkpoint therapy which can directly kill cancer cells through cytotoxic T-cells and trigger diverse immune responses through CD4+ helper T cells in adaptive and innate immunity. Our study in T cell response during treatment with TACE may explain the role of T cell response in HCC and the importance of T cell response in TACE.

Forty-one patients with hepatocellular carcinoma (HCC) and 40 patients with liver cirrhosis (LC). Mean CD4 in HCC patients significantly higher compared to LC patients whereas Th1, Th17, Interleukin (IL-17) and Gamma-interferon (IFN) were not different. CD4 in HCC increases not in type 1 reaction which may imply a defect in immunology reaction which brings these chronic liver diseases to HCC. HCC with Th1 and Th17 increase significantly after TACE were have a better response for TACE. A strong type 1 reaction was also needed to have a better response of TACE. Immunologic reaction through Th17 may play a major role in the response of TACE. Our findings may support the importance of immunologic reaction especially T lymphocytes in the successful response of locoregional therapy. However, many questions still remain in the role of immune reaction in HCC and for this reason studies should be taken to clarify these.

Interdisciplinary collaboration in the management of HCC need not to be emphasized. Our experience in the management of HCC showed us that interdisciplinary collaboration in HCC management has been a better result in terms of Overall Survival of our patients.



Dr. Man-Fung Yuen

Department of Medicine, The University of Hong Kong
Hong Kong, China

Global Epidemiology & Risk Factors of Hepatocellular Carcinoma

At present, incidence rate of hepatocellular carcinoma (HCC) is still considerably high worldwide. HCC not only is one of the most common cancers globally, it causes substantial morbidity and mortality. In 2018, liver cancer resulted in more than 780,000 deaths globally. The three main etiological factors of HCC include two chronic viral infections namely hepatitis B virus (HBV) infection, hepatitis C virus (HCV) infection and alcoholic liver disease. Non-alcoholic fatty liver disease (NAFLD) is now noteworthy increasingly contributory entity. Effective screening and management strategies are crucial to reduce the HCC risk and its mortality.

HBV accounting for majority of HCC cases were acquired via perinatal and early horizontal transmission. With the widespread implementation of universal vaccination for newborns, HBV-related HCC incidence has been declining in many countries. In addition, antiviral therapies using nucleos(t)ide analogues or pegylated interferon also reduce the incidence of HCC.

New direct antiviral agents (DAAs) for HCV have improved infection cure rates to 98 – 100%. All patients with HCV should now be considered for DAAs treatment unless there are strong contraindications. It is expected that HCV-related HCC incidence would also be decreasing in the near future.

Concerning NAFLD, its global incidence is increasing rapidly. Thus, its impact on HCC incidence may become increasingly apparent as compared to other causes discussed above in coming years. Progression to HCC in NAFLD occurs faster in patients with non-alcoholic steatohepatitis. Other synergistic/ additive factors include the presence of metabolic syndrome and other miscellaneous factors. Lifestyle changes are essential element of management while effective drug therapy is eagerly awaited.

As far as the management of HCC is concerned, early diagnosis via imaging surveillance among persons with HCC risk factors remains the most important strategy.

Dr. Oidov Baatarkhuu

Mongolian National University of Medical Sciences, Mongolia



Epidemiology of HCC in Mongolia

Mongolia has much higher liver disease burden than any other regions of the world. Cancer is the second most common cause of death accounting for nearly a fifth of all deaths, hepatocellular carcinoma (HCC) is the most prevalent cancer type accounting for ~40% of all cancers in Mongolia. . Besides the most common etiology for HCC in Mongolia was HCV infection which is 46%, HBV infection 34%, co-infection of HBV and HCV 14.4% and alcohol which is 5.6%. Most patients had advanced HCC – 88 (45.1%) in stage III and 57 (29.2%) in stage IV. The risk factors associated with HCC development were history of acute hepatitis, chronic hepatitis, and the presence of liver cirrhosis. Of these, the presence of liver cirrhosis was the strongest risk factor. In Mongolia, over 60% of patients had a tumor size more than 5 cm. Single tumors were only found in 15%.2-4

The Strategy for Early Detection of Liver Cancer issued in May 2014 (commenced in 2015) recommends screening people 40 to 65 years of age for HBV and HCV with rapid tests. Confirmation by enzyme-linked immunosorbent assay will be done at the district level. Those identified with chronic hepatitis will receive alpha-fetoprotein (AFP) and ultrasound tests every 6 months. Data will be collated at the National Cancer Center. Those identified with tumors smaller than 2 cm will be followed up every 4 months, which differs from American and European guidelines. Patients with lesions larger than 2 cm will be sent to the National Cancer Center of Mongolia. There is an algorithm to indicate the need for biopsy (e.g., AFP level, ultrasound findings).

The incidence rate of HCC was of 68.4 cases per 100,000 population, which 72.9 for males and 63.9 for females. In 2020, A total of 2145 new cases of liver cancer were recorded, which accounts for 32 % of the total new cancer cases. Compared to the region, the incidence rate of liver cancer was higher in the eastern aimags than the country average, the rate was 13.2 per 10 000 population⁵.

Hepatocellular carcinoma continues to be the leading cause of death in both male and female. The number of deaths is increasing every year, and in 2019 it increased by 473 cases compared to 2009. Most patients diagnosed at an advanced stage of the disease. 23.5% of patients who diagnosed with HCC survived longer than 5 years.⁵⁻⁶

References

1. Baatarkhuu O, Kim DY, Bat-Ireedui P, Han KH. Current situation of hepatocellular carcinoma in Mongolia. *Oncology* 2011;81 (Suppl 1):148-151
2. Baatarkhuu O, Kim DY, Nymadawa P et al. Clinical features and prognosis of hepatocellular carcinoma in Mongolia: a multicentre study. *Hepatol Int* 2012 Oct; 6(4):763-769.
3. Oidov Baatarkhuu, G,Ugantsetseg, D.Munkh-Orshikh et al. Viral Hepatitis and Liver Diseases in Mongolia. *Euroasian Journal of Hepato-Gastroenterology*, January-June 2017;7(1):68-72
4. Epidemiology, Genotype Distribution, Prognosis, Control, and Management of Viral Hepatitis B, C, D, and Hepatocellular Carcinoma in Mongolia. *Euroasian Journal of Hepato-Gastroenterology*, January-June 2018;8(1):1-6
5. Health indicator, Health Department center,2019
6. Health indicator, Health Department center,2020



Dr. Junko Tanaka

Department of Epidemiology, Infectious Disease Control and Prevention,
Graduate school of Biomedical and Health Sciences, Hiroshima University,
Japan

Epidemiology of Viral Hepatitis and HCC in Japan

In Japan, over 300,000 people lost their lives due to cancer, annually, and it increases as the number of elderly are increased.

On the other hand, number of death due to liver cancer, (“malignant neoplasms of the liver and intrahepatic bile duct”, which is mainly caused by persistent infection with hepatitis C virus (HCV) or hepatitis B virus (HBV), had increased since 1970. It had peaked at over 30,000 in 2002, but has continued to decline since then, for both men and women.

Proportions of HCV or HBV-related liver cancer among all liver cancer deaths are estimated to be 49% and 14% in 2013, respectively, and they are decreasing.

In 2000, viral hepatitis was considered to be one of the largest infectious diseases in Japan, and national countermeasures were established. Advanced national projects against viral hepatitis have been successfully implemented, such as prevention of mother-to-child transmission of HBV started in the 1980s and HCV screening for safe blood transfusion started in 1989. Epidemiological survey of blood donors showed that both of incidence of hepatitis virus infection and prevalence of persistent hepatitis virus infection among younger populations are extremely low in recent years.

In this symposium, I would like you to introduce and discuss the study results from our viral hepatitis epidemiology group under the Ministry of Health, Labour and Welfare in Japan. I will show the numbers of persistent HCV or HBV infection in 2000, 2011 and 2015, and of the numbers of patients with viral hepatitis-related disease using the National database, which has the advantage of being a universal health insurance system in Japan, and I will talk about the trend of liver cancer mortality.



Dr. Hideo Yoshida

Department of Gastroenterology and Hepatology,
Japanese Red Cross Medical Center, Japan

HCC Treatment in JRCMC (Japanese Red Cross Medical Center)

We have a system in our institute to treat all stages of HCC except for liver transplantation which we used to perform. In other words, we provide a wide range of services, from diagnosis and treatment of chronic liver disease, which is the background of hepatocellular carcinoma, to surgery and local therapy for early-stage HCC, hepatic artery embolization for intermediate to advanced stage HCC, chemotherapy with molecular targeted agents, and palliative care for end stage HCC. We also provide palliative care for end stage HCC.

We performed radiofrequency ablation for 1093 cases from January 2008 to April 2021, even if the indication was beyond the range of indications defined by tumor size and number of tumors, if we thought the radiofrequency indication would be effective in improving prognosis. From February 2012 to August 2020, 268 cases of HCC were treated with Cyber Knife. 85 were radiation for intrahepatic lesion, 183 were for extrahepatic lesion.

Molecular targeted therapy is also flexible in terms of drug selection and administration, and may be combined with radiofrequency ablation or hepatic artery embolization. 82 cases were treated with molecular targeted therapy between January 2015 and April 2021.

We are actively treating hepatitis, including viral hepatitis, both before and after curative treatment for hepatocellular carcinoma to prevent carcinogenesis and recurrence. We also provide treatment for complications of cirrhosis in patients with advanced hepatocellular carcinoma with decreased reserve capacity and portal hypertension. Those are very important to keep patient's QOL high and prolong prognosis. The palliative care ward is also located in the same building, which allows us to easily visit patients in the hospital while maintaining good communication with palliative care physicians, putting patients at ease.

The actual treatment of HCC at our hospital will be presented.



Dr. Hironao Okubo

Department of Gastroenterology,
Juntendo University Nerima Hospital, Japan

Management of Adverse Event from the Pharmacological Perspective in Patients with Hepatocellular Carcinoma Using Tyrosine Kinase Inhibitor

In order to progress in clinical outcome of tyrosine kinase inhibitor (TKI) for hepatocellular carcinoma (HCC), not only therapeutic strategy of systemic chemotherapy but appropriate management of adverse events (AEs) during the pharmacotherapy would be needed in the clinical settings. While physicians were accustomed to a sorafenib toxic profile that based on ten years clinical experience, the experience in the management of the other drugs such as lenvatinib and cabozantinib were relatively limited. Since there are some differences in the pharmacological characteristics among TKI, it is necessary to have familiar with pharmacological properties of these drugs. In particular, lenvatinib for HCC has the characteristics of differing administered dose unlike the other carcinoma. In addition, our recent study has demonstrated that patients with HCC receiving TKI showed large variability in the drug concentration. Therefore, we need to consider the TKI therapy from a pharmacological perspective based on not only dose-response but exposure-response. First, we review the pharmacological properties of each TKI in this lecture. Second, we focus on the factors related to the exposure of each TKI and the effects of exposure on development of adverse events. Third, we show the mechanism of AEs such as fatigue, hypertension, and protein urea and the methods to diminish severity of AEs.



Dr. Shiv Kumar Sarin

Department of Hepatology,

Institute of Liver and Biliary Sciences, New Delhi, India

Management of HCC Patient with Portal Vein Thrombosis

Dr. S K Sarin, Dr. Navin Kumar, Dr. Vinod Arora

Department of Hepatology, Institute of Liver and Biliary Sciences, New Delhi, India

PVTT is present in 10%-40% of HCC at the time of diagnosis, and is an adverse prognostic factor. Patients with PVTT usually have an aggressive disease course, poor hepatic functional reserve, limited treatment options and higher recurrence rates. Among untreated HCC patients with PVTT, the median overall survival has been reported as 2 to 4 months. The PVTT results in disordered hepatic and portal blood flow and associated impairment of liver function, heat-sink effects of blood flow in the area of the PVTT, risk of recurrence and spread of tumor being in the blood vessels. High levels of prothrombin induced in vitamin K absence (PIVKA II) with or without alfa-feto protein has been found to be a good marker of portal vein invasion. The current BCLC staging system categorizes HCC patients with PVTT as advanced stage and recommends systemic therapy with Sorafenib as a first line therapy. However, sorafenib is associated with only marginal benefits among patients with PVTT. First-line lenvatinib, which was shown to be noninferior to sorafenib, excluded patients with main portal trunk invasion. We have used high dose of Vitamin K, which induces apoptosis and cell cycle inhibition, including the MAPK pathway for HCC with PVT. In a series of 60 patients, a combination of high dose of vitamin K (VK1) given for 6 days with sorafenib was found to be more effective (VK1) than sorafenib alone in advanced HCC patients with PVTT being present in 73%. PIVKA II reduction was seen in 94% patients (median PIVKA II reduction from 74 ng/ml to 4.5 ng/ml). This therapy can be given up to Child B 7 patients who were not candidates for other local therapies.

Although traditionally PVTT has been considered contraindication to liver transplantation or surgical resection, in specialized units, partial hepatectomy with en bloc resection of PVTT in second-order and third order branches has been shown to offer significant benefits in selected patients. However, the risk of recurrence is high if the tumor involves the first order branches. Locoregional therapies are no more considered an absolute contraindication for PVTT. Transarterial radio-embolization (TARE) has been shown to provide partial or complete response in upto 70-90% patients, with complete regression of tumor in nearly half, with survivals reaching similar to that achieved in patients without PVT. The success rate with stereotactic body radiotherapy (SBRT) has been found to be effective in achieving actuarial overall survival in responders and non-responders close to 15 and 7 months. After SBRT, the patients can be taken up for TACE, TARE or immunotherapy. Liver transplantation has also been successfully carried out in patients with VP1 or 2 tumor thrombus after successful local therapies, including TARE and SBRT, though the overall long-term survival remains to be seen. The role of immune check point inhibitors in improving the overall survival are limited. Recently encouraging results have been shown with these agents even in patients with Child B patients with PVTT. A personalized and multidisciplinary management to achieve optimal outcomes in patients of HCC with PVTT.



Dr. Hitoshi Maruyama
Department of Gastroenterology,
Juntendo University, Japan

Contrast Enhanced US-based Assessment of HCC Hemodynamics Related to Systemic Treatment

Hepatocellular carcinoma (HCC) represents primary liver cancer. It is problematic worldwide because of the major reason for cancer-related death in cirrhosis patients. Liver cancer is the major target of ultrasound (US), which is the simple, non-invasive, and real-time imaging method. Microbubble-based contrast agents are safe and reliable and have become popular, which has resulted in the improvement of diagnostic performances of US due to the increased detectability of the peripheral blood flow. Contrast-enhanced US (CEUS) is now one of the most frequently used modalities in the practical management of liver tumors, including the detection and characterization of the hepatic lesion, evaluation of the effects of various treatments, intra-operative support, and post-treatment surveillance. Recent development has introduced several oral multikinase inhibitors, which have been approved for the treatment of advanced unresectable HCC. Because one of the targets of them is angiogenesis (vascular endothelial growth factor receptor and platelet-derived growth factor receptor), there may be a possibility that the evaluation of hepatic hemodynamics using CEUS has a potential effect on the prediction of the therapeutic results. This presentation overviews recent studies regarding CEUS in the systemic treatment of HCC with the use of multikinase inhibitors.




Dr. Kenya Kamimura

Department of General Medicine, Niigata University School of Medicine,
Division of Gastroenterology and Hepatology, Niigata University Hospital,
Japan

Effective Prevention of TKI-related Vascular Damage induced Adverse Events and Maintenance of Hepatic Function by Dried Bonito Broth and Histidine

Tyrosine kinase inhibitor (TKI) is an anti-angiogenic chemotherapeutic that prolongs the survival rates of patients with hepatocellular carcinoma. However, TKIs induce vasculature damage-related adverse events, including hand-foot syndrome and hypertension, which affect the patients' quality of life. We have reported that vascular damage resulted in the narrowing of the normal vascular dimension area using medaka as an animal model, and histidine (HIS), a major amino acid contained in dried bonito broth (DBB), prevented these changes. Therefore, in the study, we examined the effects of DBB and HIS on TKI-related vascular damages and associated adverse events in patients. Our results clearly demonstrate that DBB and HIS prevented TKI-related abdominal vascular damage and effectively maintained hepatic function, and prevented clinical symptoms and toxicity.



Dr. Reina Sasaki-Tanaka

Division of Gastroenterology and Hepatology,
Department of Medicine, Nihon University School of Medicine, Itabashi,
Tokyo, Japan

Rapid Hepatitis C Virus Clearance by Antivirals Correlates with Immune Status of Infected Patients and Decreased Immune Related Cytokines and Chemokines

Introduction: Hepatitis C virus (HCV) infection causes chronic hepatitis, and has been one of the important factors causing cirrhosis and hepatocellular carcinoma (HCC). Direct-acting antivirals (DAAs) can easily clear HCV RNA, but face issues such as altered immune status, reinfection and carcinogenesis.

Methods: Altered immune parameters associated with 31 HCV genotype 1b infection and their correlation with virus eradication in 12 weeks DAA-treated patients were examined. Pre-DAA-treatment and post-DAA-treatment sera were analyzed for cytokines/chemokines using MILLIPLEX MAP human cytokine/chemokine magnetic bead panel (Millipore, Billerica, MA, USA). Serum complement level and antibody neutralization activity were measured separately. Rapid virological responders (RVR) or end-of-treatment responders (EOTR) were defined as patients with HCV RNA negative at week 4 or positive at week 4 and negative at week 12, respectively. HCV RNA eradication and a decrease in liver fibrosis-related cytokines after treatment were observed when compared with pretreatment sera from RVR and EOTR.

Results: In pretreatment sera, interferons and T-helper 1 or 2 cell-associated cytokines/chemokines were significantly higher among RVR as compared with EOTR. Furthermore, serum complement and virus neutralizing antibody levels were higher in pretreatment RVR sera. Eradication of HCV RNA by DAA decreased liver fibrosis-related cytokines. Pretreatment sera from RVR displayed an enhanced cytokine/chemokine, complement and virus neutralizing antibody response as compared with EOTR sera. Our results suggested that enhanced host immune status may play an additive role on HCV RNA clearance by DAA. On the other hands, IFN- α 2 and IFN- γ were significantly downregulated in sera post-treatment as compared to pre-treatment. T-helper 1 cell response associated CCL3 (macrophage inflammatory protein-1 α ; MIP-1 α), CCL4 (MIP-1 β), IL-12P70, interferon- γ inducible protein-10 (CXCL10) and GM-CSF were significantly downregulated in sera post-treatment as compared to pre-treatment.

Conclusions: RVR patients, in general, displayed an enhanced level of cytokine expression compared to that seen in EOTR patients. However, DAAs also reduce IFNs and many immunoregulatory cytokines. In this point, we have to continue careful follow-up on patients who achieved sustained virological response after DAA treatment.




Dr. Ming-Lung Yu

Hepatobiliary Section, Department of Internal Medicine,
Kaohsiung Medical University Hospital, Kaohsiung Medical University,
Kaohsiung City, Taiwan

The Clinical and Pathogenic Significance of HCC after Viral Eradication

Chronic hepatitis C virus (HCV) infection is a major cause of hepatocellular carcinoma (HCC) globally. Although successful HCV eradication by achieving a sustained virological response (SVR, undetectable HCV RNA 12–24 weeks after therapy) substantially decreases the risk of HCC development, the HCC risk cannot be completely eliminated.

With the highly effective and safe DAA regimens, the increasing number of post-SVR HCC is expected in the near future. It is thus important to understand the patient and tumor characteristics as well as long-term outcomes of HCC developed after SVR by antivirals. Aged, an albumin bilirubin grade (ALBI) of 2 or 3 and baseline AFP ≥ 10 ng/mL were associated with higher HCC risk among cirrhotic SVR patients, while age, higher baseline AFP and diabetes are significant risks among the non-cirrhotic SVR group. We recently analyzed overall survival outcomes in 1389 HCV-related HCC patients, including 301 post-SVR HCC and 1088 with HCV viremia at HCC diagnosis (viremic HCC). At HCC diagnosis, post-SVR HCC patients were older, less obese, less likely cirrhotic, with better liver function, lower alpha-fetoprotein levels, earlier BCLC stages, and higher rate of treatment with surgery, as well as significantly longer survival, compared to viremic-HCC. However, on sub-analysis, viremic-HCC patients who subsequently received antiviral treatment and achieved SVR had higher median survival and lower mortality than post-SVR HCC patients. The advantages in clinical and tumor characters at HCC diagnosis determined the better overall survival of post-SVR HCC patients; however, HCV eradication after HCC development was also associated with improved survival. Patients with high genetic risk score of hepatic fat accumulation, combining variants in PNPLA3, MBOAT7, TM6SF2, and GCKR (glucokinase regulator) are at risk of HCC after SVR by DAAs. The data suggests that hepatic fat (i.e., lipotoxicity) promotes HCC in this setting and may represent a target for chemoprevention. Several studies have demonstrated that HCV infection induced epigenetic and gene expression alterations associated with risk for HCC. These alterations could not be reversed after HCV eradication. Understanding the mechanisms and characteristics of post-SVR HCC could improve the risk stratification and might help us to identify potential targets to prevent liver cancer in patients treated for HCV infection.



Dr. Yoichi Hiasa

Department of Gastroenterology and Metabology,
Ehime University Graduate School of Medicine, Japan

Risk of Hepatocellular Carcinoma After Sustained Virological Response in Hepatitis C Virus Infection

Treatment with direct-acting antivirals (DAAs) achieves sustained virological response (SVR) in more than 95% of patients with hepatitis C virus infection. However, liver damage, including cirrhosis, often persists even after achieving SVR, increasing the risk of hepatocellular carcinoma (HCC).

Our department conducted a multicenter clinical research project with a group of specialized medical institutions in Ehime Prefecture, Japan, called the “EKEN study group”. We investigated the risk of HCC after SVR in patients with hepatitis C infection treated with DAAs at these institutions, including our hospital.

The risk factors for occurrence of HCC before DAA treatment in patients with no past history of HCC were investigated. Using multivariate analysis, male, low albumin level and high FIB4 index were extracted as significant pre-treatment factors. Subsequently, by multivariate analysis including risk factors at the end of DAA treatment, two factors, high FIB4 index and high alpha-fetoprotein (AFP) at the end of treatment, were extracted as significant risk factors for HCC.

Based on the results of Cox proportional hazards regression analysis including the levels of the factors at 12 weeks (SVR12) after the end of DAA treatment, male, high AFP at SVR12 (SVR12-AFP), high FIB4 index at SVR12 (SVR12-FIB4), and low levels of albumin at SVR12 (SVR12-Alb) were extracted as risk factors for HCC. By the log-rank test, the group of patients fulfilling all four high-risk factors had 13.7% of patients with HCC, whereas patients with none of these risk factors did not develop HCC.

There was a high rate of recurrence of HCC (53.4%) at 3 years after DAA treatment in our study. Male, absence of SVR, and frequency of past HCC treatments were extracted as significant risk factors by multivariate analysis. The risk factors for early recurrence within 1 year after DAA treatment were different from those for late recurrence. High AFP at the end of treatment was identified as a risk factor for early recurrence. On the other hand, decreased eGFR was identified as a risk factor for late recurrence, and was associated with the frequency of HCC treatments and the comorbidity of diabetes mellitus.

Our results suggest that careful follow-up and screening for HCC is required even in hepatitis C patients in whom SVR is achieved with DAA treatment. Moreover, the risk factors associated with HCC occurrence and recurrence in hepatitis C patients need to be assessed, and a follow-up strategy should be established according to the risk factors.



Dr. Jia-Horng Kao

Graduate Institute of Clinical Medicine, National Taiwan University College of Medicine,

Department of Internal Medicine, National Taiwan University Hospital, Taiwan

Development of HCC in Treated HBV Patients

Ample evidence indicates an etiological association of persistent hepatitis B virus (HBV) infection with hepatocellular carcinoma (HCC). The incidence of HCC is extremely high in HBV hyperendemic areas. For example, in adult patients chronically infected with HBV, the annual risk of developing HCC varies between about 0.5% in the absence of cirrhosis and 2-3% in the presence of compensated cirrhosis if left untreated. Recent data indicated that long-term suppression of HBV replication by using antiviral therapy can reduce the risk of HCC and mortality over time in patients with immune-active CHB or cirrhosis. However, whether HCC is prevented or delayed deserves further examinations. Moreover, establishment of risk prediction or risk models for HCC may guide the strategic implementation of HCC surveillance in treated patients. In a recent systematic review and meta-analysis of 14 models developed to predict HCC in CHB patients receiving antiviral therapy, the REAL-B model exhibited best discrimination and calibration. For the future development of more accurate HCC risk models in treated CHB patients, external validation is urgently needed and machine learning based on more comprehensive data may provide better predictive power in our clinical practice. Taking these lines of evidence together, substantial reduction of HBV-related HCC should be expected in early 2050s by scaling up the primary and secondary preventive measures.



Dr. Yasuhito Tanaka

Department of Gastroenterology and Hepatology,
Faculty of Life Sciences, Kumamoto University, Japan

Gene Expression Signature Associated with HCC Development after HCV Eradication

Chronic hepatitis C virus (HCV) infection is an important risk factor for hepatocellular carcinoma (HCC). The risk of HCC development is not completely eliminated after a sustained virologic response (SVR) to effective antiviral treatment. In the recent study, we elucidate the mechanisms of HCC development after SVR achievement by omics analyses; genome-wide association study (GWAS) and comprehensive mRNA analyses.

1) Based on the GWAS, rs17047200 AT/TT in TLL1 gene was an independent risk factor for developing HCC, in addition to male gender, older age, lower albumin level, advanced hepatic fibrosis stage, presence of diabetes and higher post-treatment α -fetoprotein level. TLL1 expression analyses showed that mRNA levels in human stellate cells increased with activation. Tll1 transgenic mice also induced steatohepatitis and HCC development by choline deficient high fat diet more efficiently.

2) To characterize the gene signature of HCC development after SVR, we analyzed data of HCC and the adjacent liver in comparison with public data of several liver tissues (HCV-related HCC, non-B non-C (NBNC) HCC, Normal liver) from International Cancer Genome Consortium (ICGC) and NCBI Sequence Read Archive (SRA) study. There was not the specific signature of post-SVR HCC compared with HCV-related HCC and NBNC HCC. On the other hand, in adjacent liver after SVR achievement, inflammatory genes were not significantly upregulated, and lipid metabolic and oxidative reduction related genes were deregulated. By investigating co-expression cancer associated genes related with these genes in SVR group, one of module positively correlated with SVR group, including lipid metabolic, mitochondria function genes and tumor suppressor genes. Interestingly, Mt-A was highly interconnected with nodes in this module and the expression of Mt-A was upregulated in adjacent liver of only SVR group. The Mt-A was a novel nuclear-encoded and mitochondrial localized protein and electron microscopy revealed changes in mitochondrial morphology. Further functional analyses are underway. In conclusion, the combination of these biomarkers might predict the post-SVR HCC development.



Dr. Hayato Hikita

Gastroenterology and Hepatology,
Graduate School of Medicine, Osaka University, Japan

The Interaction of Hepatoma Cells and Stromal Cells Via IL-6 Family Cytokines

In approximately 60% HCC, STAT3 is activated. However, the impact of STAT3 activation in HCC on tumor growth in vivo remains unclear. In the present study, we examined the significance of STAT3 activation in liver tumors on the tumor growth and its underlying mechanisms using HCC mouse model, cell lines and clinical samples.

In liver tumors developed in KrasG12D mice (Alb-Cre KrasG12D), STAT3-targeted genes, IL-6 family cytokines and CTGF were upregulated compared in surrounding non-cancerous lesion or control mouse liver. CTGF expression levels were positively co-related with expression levels of STAT3-targeted genes and IL-6 family cytokines in liver tumors. Single RNA sequencing revealed that hepatic stellate cells (HSCs), macrophages, and endothelial cells, expressed IL-6 family cytokines, including IL-6, LIF and OSM. It also revealed that hepatoma cells expressed CTGF.

In vitro experiments, IL-6, LIF and OSM concentration increased in culture media of HSCs, macrophages, or endothelial cells. Administration of recombinant IL-6, LIF and OSM activated STAT3 and promoted cell growth with increase of CTGF expression in hepatoma cells. Co-culturing with HSCs, macrophages or endothelial cells activated STAT3 and enhanced CTGF of hepatoma cells. The co-culturing also promoted hepatoma cell growth, which is suppressed by CTGF knockdown of hepatoma cells. Recombinant CTGF increased IL-6 family cytokines in HSCs, macrophages, or endothelial cells.

In liver tumors developed in CTGF knockout KrasG12D mice (Alb-Cre KrasG12D CTGF fl/fl), expression levels of IL-6 family cytokines were suppressed. Using clinical samples, hepatoma cells expressed CTGF, and HSCs, macrophages or endothelial cells expressed IL-6 family cytokines. Both of IL-6 family cytokine and STAT3-targeted gene expressions were co-related with CTGF expression levels.

In conclusion, STAT3 activation in HCC increases IL-6 family cytokines of stromal cells, which further enhances STAT3 activation in hepatoma cells. The crosstalk between hepatoma cells and stromal cells via CTGF/IL-6 family cytokines promotes liver tumor growth in vivo.



Dr. Motoyuki Otsuka

Department of Gastroenterology, Graduate School of Medicine,
The University of Tokyo, Japan

Impairment of Homologous Recombination by HBx as the Mechanism for HBV-Related Hepatocarcinogenesis

Background & Aims: Hepatitis B virus (HBV) causes hepatocellular carcinoma (HCC). While the need for HBV regulatory protein X (HBx) for viral transcription via impairment of the structural maintenance of chromosome 5/6 (Smc5/6) complex was recently demonstrated, HBx is also a potent driver of HCC. However, the mechanism by which HBx expression induces hepatocarcinogenesis is unclear.

Methods: Degradation of Smc5/6 complex and accumulation of DNA damage were observed in both in vivo and in vitro HBV infection models. Rescue experiments were performed using nitazoxanide (NTZ), which inhibits degradation of the Smc5/6 complex by HBx.

Results: Degradation of the Smc5/6 complex triggered by HBx impaired homologous recombination (HR) repair of DNA double-strand breaks (DSBs), leading to cellular transformation. We found that DNA damage accumulated in the liver tissue of HBV-infected humanized chimeric mice, HBx-transgenic mice, and human tissues. HBx suppressed the HR repair of DSBs, including that induced by the clustered regularly interspaced short palindromic repeats-Cas9 system, in an Smc5/6-dependent manner, which was rescued by restoring the Smc5/6 complex. NTZ restored HR repair in, and colony formation by, HBx-expressing cells.

Conclusions: Degradation of the Smc5/6 complex by HBx increases viral transcription and promotes cellular transformation by impairing HR repair of DSBs.



Dr. Taro Yamashita

Department of General Medicine, Kanazawa University Hospital,
Japan

Recent Progress in Basic and Clinical Research of Liver Cancer Stem Cells

The cancer stem cell (CSC) hypothesis was proposed over 4 decades ago and states that tumor growth is maintained by a small subset of cancer cells analogous to normal tissue stem cells in terms of self-renewal and differentiation capacity. Advances in CSC isolation were initially achieved in hematological malignancies and later in solid tumors, including hepatocellular carcinoma (HCC), the major histological type of liver cancer. HCC is known as a heterogeneous disease in terms of morphology, cellular behavior, responses to treatment, and clinical outcome. Increasing evidence suggests the importance of liver CSCs for tumor growth, metastasis, and chemo/radiation resistance in HCC, but the application of the liver CSC concept for the clinical diagnosis and treatment of HCC has not yet been achieved to the extent initially expected. Furthermore, the heterogeneity and plasticity of liver CSCs has recently been noted and might be related to drug resistance and the rapid growth and/or metastasis of the tumor after treatment. Here, we introduce our recent advancement in liver CSC research. We also discuss its clinical implications especially on the diagnosis of early-stage HCC and its prognostic outcome in terms of metastasis, which may lead to the development of improved diagnostics and treatment in HCC.



Dr. Haruhiko Takeda

Department of Gastroenterology and Hepatology,
Graduate School of Medicine, Kyoto University, Japan

Genetic Alterations during Multistep Hepatocarcinogenesis Revealed by Whole Genome Sequencing

Hepatocellular carcinoma (HCC) is a major cause of cancer-related death worldwide. Although several targeted therapy agents are available for advanced HCC, their anti-tumor efficacy remains limited. As the complex genetic landscape of HCC would compromise the antitumor efficacy of targeted therapy, the deeper understanding of genetic landscape of hepatocarcinogenesis is necessary. Recent comprehensive genetic analyses have revealed the driver genes of HCC, which accumulate during the multistage process of hepatocarcinogenesis, facilitating HCC genetic heterogeneity. Recently developed whole genome sequencing (WGS) can examine not only point mutations but also structural variations such as chromosomal translocations and HBV integration into human genome. In addition, the aberrations at non-coding elements can be identified as well as coding gene mutations. Although the comprehensive analysis strategy using WGS is so complicated, the application of WGS for the real-world clinical specimens is highly expected in the era of personalized oncology.

We conducted multi-regional WGS analysis of HCCs with nodule-in-nodule appearance, and identified the genetic alterations, including single nucleotide variants, indels, structural variations, copy number alterations and HBV integrations, in the outer hypovascular tumors and inner hypervascular aggressive tumor tissues. Based on the multiregional genetic aberrations data, we constructed phylogenetic tree in every case, and examined so-called “trunk” and “progressor” mutations. Notably, hypovascular tumors already had many chromosomal abnormalities such as translocations, arm-level copy number loss and even “chromothripsis”, crisis event of chromosome. While the progressor genes differed by case, trunk aberrations always included TERT-associated alterations, such as promoter mutations, HBV integration, translocations and focal copy-number gain with high allele frequencies.

We also conducted multi-omics analysis on over 200 noncancerous cirrhotic liver tissues. We found HCC-related gene mutations can be detected in cirrhotic livers, whereas TERT promoter mutations, the most major genetic changes in HCC, were never detected in all noncancerous liver samples analyzed. These findings were well supported by multi-regional WGS analysis of cirrhotic liver samples reported by Sanger Institute in 2019.

These comprehensive genetic profiling by multi-regional sequencing strategy can lead to the assumption that TERT alteration is the key driver in the first step of hepatocarcinogenesis. Our findings also indicate the pivotal targets associated with tumor progression differ between cases, highlighting the importance of personalized strategies for the identification of therapeutic targets and the respective molecular targeted therapy for each patient. Now we should prepare for the new era of the personalized medicine based on WGS.



Dr. Gamal Shiha

Hepatology and Gastroenterology Unit,
Internal Medicine Department, Faculty of Medicine,
Mansoura University, Egyptian Liver Research Institute and Hospital, Egypt

Predictive Scores for Hepatocellular Carcinoma Risk Stratification after Achieving SVR Following DAAS

Many HCC risk prediction scores were developed to guide HCC risk stratification and identify CHC patients who either need intensified surveillance or may not require screening. There is a need to compare these different HCC risk scores and their predictive performance in clinical practice.

Our Aim is to compare the newest HCC risk scores evaluating their discriminative ability, and clinical utility in a large cohort of CHC patients

Patients and Methods: The performance of the scores was evaluated in 3075 CHC patients who achieved SVR following DAAs using Log rank, Harrell's c statistic, also tested for HCC-risk stratification and negative predictive values.

Results: HCC developed in 212 patients within 5 years follow up. Eleven HCC risk scores were identified and displayed significant Log rank ($p \leq 0.05$) except TE-HCC of Alonso-Lopez, and Chun scores where ($p=0.374$, $p=0.053$ respectively). Analysis of the remaining nine scores revealed that ADRES, GES pre-post treatment, Watanabe (post-treatment) scores including dynamics of AFP, were clinically applicable and demonstrated good statistical performance; Log rank analysis <0.001 , Harrell's C statistic (0.66-0.83) and high negative predictive values (94.38-97.65%). In these three scores, the 5 years Cumulative IR in low risk groups is very low (0.54-1.6) so, screening could be avoided safely in these patients.

Conclusion: ADRES, GES (pre and post treatment), Watanabe (post-treatment) scores seem to offer acceptable HCC-risk predictability and clinical utility in CHC patients. The dynamics of AFP as a component of these three scores may explain their high performance when compared to other scores.



Dr. Ryosuke Tateishi

Department of Gastroenterology,
The University of Tokyo Hospital, Japan

Radiofrequency Ablation for Hepatocellular Carcinoma

Hepatocellular carcinoma (HCC) generally arises from chronic liver disease with impaired function, which often limits surgical therapies. Locoregional therapies have been developed to expand treatment options for localized HCC outside the indication of surgical treatments. Percutaneous ablation is a method to destroy targeted tumors by chemical reaction, heat, freezing, or electric pulse using needle-like devices. Percutaneous ethanol injection was replaced by radiofrequency ablation (RFA) after several randomized controlled trials comparing the two modalities. Recently, second-generation microwave ablation has been gaining market share over RFA due to its larger ablative area. The significant limitations of percutaneous ablation include restricted applicability to difficult-to-access regions, such as hepatic hilum and dome, and visibility of target tumor under ultrasound to guide needle/probe insertion. Several techniques have been developed to address the challenges, including artificial ascites and pleural effusion, contrast-enhanced ultrasonography, and fusion imaging. The complications related to percutaneous ablation, such as bleeding, infarction, liver abscess, intestinal perforation, and tumor seeding, have been thoroughly assessed. Also, the countermeasures for these complications have been well established in the last two decades. The possibility of combination therapy with other modalities has been explored to enhance the efficacy of ablation. Among combination therapies, the combination with immunotherapy is the most promising one, where immune activation through thermal- or cryo-ablation is expected to enhance the efficacy of immune checkpoint inhibitors. The treatment for background chronic liver disease is essential to improve the overall survival of patients with HCC. Nucleos(t)ide analogs drastically improved the prognosis of patients with hepatitis B who underwent radiofrequency ablation. We recently observed an improved overall survival in patients with chronic hepatitis C due to the emergence of direct-acting antivirals (DAAs). Based on the recent results of randomized controlled trials, including a domestic trial called SURF trial, the current Japanese guidelines equally recommend hepatic resection and RFA for patients with HCC who have 3 or fewer nodules, none of which exceed 3 cm and Child-Pugh A or B liver function without vascular invasion or extrahepatic metastasis. RFA will continue to play a significant role in the treatment of HCC.



Dr. Shuntaro Obi

Internal Medicine,
Teikyo University Chiba Medical Center, Japan

Hepatic Arterial Infusion Chemotherapy (HAIC) in 2021

I would like to thank Professor. Moriyama, the president of APASL-ONCOLOGY 2021, for giving me this opportunity to present my work.

There have been two major drastic changes in the field of liver cancer.

One is the change in etiology due to the eradication of hepatitis C virus, and the other is the change in treatment strategy due to the introduction of combined immunotherapy.

In Japan, hepatitis C virus was the cause of the majority of hepatocellular carcinoma (HCC). With the prevention of infection and eradication of the virus, the number of hepatitis C-derived HCC has decreased. Furthermore, the decrease in hepatitis C-derived HCC was accompanied by a decrease in the number of deaths of HCC patients in Japan. Instead of that NAFLD-related liver cancer has increased. NAFLD-associated hepatocarcinoma makes it difficult to establish an effective screening system. Therefore, it is often discovered in advanced cancer. In addition, combined immunotherapy is only available for advanced HCC with good liver function in Child-Pugh A, so the treatment of advanced HCC in Child-Pugh B is left out. On the other hand, in the SILIUS Study, which investigated the effect of adding arterial chemotherapy to sorafenib, no significant difference was found in the primary endpoint of overall survival, but there was an effect of adding arterial chemotherapy in patients with portal vein tumor invasion. Therefore, HAIC may still have a place to play.

The cost of combined immunotherapy is also an issue. The economic situation of countries in Asia Pacific is not favorable, partly due to COVID-19. Intravenous chemotherapy is also an inexpensive way to treat advanced liver cancer compared to combined immunotherapies. Recently, the usefulness of HAIC with FOLFOX regimen has also been reported.

In this lecture, I would like to discuss the position of HAIC in the treatment of HCC and topics including the latest information. I hope that the lecture will be useful for the treatment of liver cancer from tomorrow.

Finally, I wish this APASL-STC a successful conclusion.



Dr. Kazuhiro Nouse

Department of Gastroenterology, Okayama City Hospital
on behalf of Okayama Hepatocellular Carcinoma Group and RELPEC Group,
Japan

Effective Use of Local Ablation Therapy for the Treatment of Early to Intermediate HCC

Background: There are two major themes that should be solved regarding RFA. First is the prevention of HCC recurrence after RFA. Second is the application of RFA for the treatment of intermediate stage HCC that is not recommended in many HCC treatment algorithms.

Aims: The aims of this study were ① to know the treatment effect of HAIC with CDDP as a neoadjuvant therapy for the prevention of recurrence after RFA, and ② to know the effect of RFA for the treatment of intermediate HCC.

Methods: ① Seventy HCC patients were randomly assigned to HAIC group and non-HAIC group, and the recurrence rates after RFA were compared between these groups (UMIN000007267). ② Among 3671 newly developed HCC in Japanese RELPEC group, 169 “up-to-7 in” intermediate stage HCC who were treated with RFA, OPE or TACE were enrolled, and the characteristics and the survival of the patients were compared.

Results: ① RFS at 1 (3) year in the HAIC group and non-HAIC group were 82.9% (54.3%) and 74.3% (34.3%), respectively (HR, 0.597; 95% CI, 0.320–1.091; $p = 0.094$). Subgroup analysis showed that the beneficial effect of HAIC was observed in patients with a single nodule and Child–Pugh score 5. Intrahepatic distant RFS in the HAIC group was significantly better than that in the non-HAIC group (HR, 0.468; 95% CI, 0.235–0.896; $p = 0.022$). ② Curative treatments such as RFA and OPE were chosen in 59 and 50 patients, respectively, whereas recommended therapy, TACE, was chosen only in 60 patients (35.5%). Median tumor size in RFA/OPE/TACE was 28/37/34mm and median tumor number was 4/2/3, indicating that RFA was chosen for the treatment of small multiple HCC and OPE was chosen for the treatment of large HCC, small in number. ALBI score of OPE (-2.56) was better than those of RFA (-2.23) and TACE (-2.36). MSTs of RFA (5.3 yr.) and OPE (5.4 yr.) were significantly longer than that of TACE (3.1 yr., $P=0.023$). Survival rate of RFA was significantly better than that of TACE even after the adjustment of the background with propensity score ($P=0.04$).

Conclusions: HAIC with CDDP had a potential to prevent the recurrence of HCC after RFA, and RFA showed better survival than TACE in “up-to-7 in” intermediate HCC.



Dr. Jidong Jia

Liver Research Center, Beijing Friendship Hospital,
Capital Medical University, China

The Key Recommendations by APASL PBC Guidance 2021

The diagnosis of PBC can be established when meeting two or more of the following three criteria: 1) Biochemical evidence of cholestasis based mainly on the elevation of ALP and GGT with the exclusion of extrahepatic biliary obstruction by imaging studies; 2) Presence of AMA or other PBC-specific ANAs including anti-sp100 or anti-gp210 ; and 3) Histologic evidence of non-suppurative destructive cholangitis mainly affecting the interlobular bile ducts. The diagnosis of PBC with AIH features could be made in PBC patients if two of the three following criteria are met: 1) moderate/severe interface hepatitis in liver histology (mandatory); 2) serum ALT/AST more than 5 times ULN; and 3) IgG level more than 1.3 times ULN or the presence of ASMA).

Oral UDCA (13~15mg/kg/day) should be standard therapy for all PBC patients. UDCA treatment should be continued for prolonged periods, and compliance to therapy should be checked. For PBC patients (non-cirrhotic or cirrhosis with Child-Pugh A) with an inadequate response to UDCA, OCA could be added or used to as monotherapy; other choices include adding bezafibrate (400 mg/d) or fenofibrate (200 mg/d) , budesonide (6 -9 mg/d) might be added to non-cirrhotic PBC patients with suboptimal response to UDCA. For those diagnosed with PBC-AIH overlap syndrome, Immunosuppressive agents (including corticosteroid with or without azathioprine or mycophenolate mofetil could be used as add-on therapy to UDCA, or de novo combination therapy with UDCA.

Pregnancy can be advised in PBC patients at childbearing age. Patients with features of cirrhosis should be well informed about the possible maternal and fetal complications.

Although data on UDCA treatment during pregnancy and breastfeeding remains limited, continued use of UDCA can be considered in those patients after special counseling on these particular issues.

Liver transplantation should be considered in patients with decompensated cirrhosis, MELD \geq 15, Mayo Risk Score $>$ 7.8, or severe, intractable pruritus. Post-transplant UDCA treatment is safe and effective in improving liver function tests and prevent PBC recurrence.



Dr. Naoki Morimoto

Division of Gastroenterology, Department of Medicine,
Jichi Medical University, Japan

Laparoscopic Radiofrequency Ablation in the Era of Non-viral Hepatitis

Background: Recent advances in diagnostic imaging have made it possible for hepatocellular carcinoma (HCC) to point out not only the main tumor but also small daughter nodules and early recurrence. On the other hand, HCC with steatohepatitis is increasing, it is often difficult to detect the target tumor on the percutaneous ultrasound (US) in obese cases. Therefore, we evaluated the usefulness of laparoscopic radiofrequency ablation (RFA) in the recent changes in the situation surrounding HCC.

Methods: We examined the efficacy, adverse events, and the presence or absence of detection of the target nodule by preoperative non-contrast ultrasound in patients who underwent laparoscopic RFA.

Results: Of the 507 patients who underwent RFA from 2014 to 2019, laparoscopic RFA 458 patients with 796 nodules, excluding percutaneous RFA (43) and RFA during laparotomy (6), were included. The median age was 70 years, and the background liver diseases were HCV 31%, HCV-SVR 30%, HBV 12%, alcohol 13%, NASH 9%, and others 5%. In recent years, NASH and alcoholic liver disease have increased. In addition, the proportion of recurrent cases increased significantly ($P < 0.01$). Number of Child-Pugh A, B and C was 397, 58 and 3, respectively. The median diameter of main tumor was 21 mm (6-44), and single nodule / 2-3 nodules / ≥ 4 nodules were 250/176/32 cases, respectively. Of the 403 cases who underwent preoperative non-contrast US, 106 cases (26%) and 137 nodules (20%) were difficult to detect on the percutaneous US. Poor detection tended to be more frequent in NASH, and significantly more in recurrent cases ($P < 0.01$). But with laparoscopic US, it was possible to detect all nodules, except for 2 nodules, and RFA could be performed. The 5-year cumulative survival rate of 234 naive cases was 82.5%, the 5-year overall recurrence rate and the local tumor progression rate was 60.7% and 4.9%, respectively. There were no cases of thermal damage to adjacent organs even in case treated liver surface lesions. Bile leakage, laparoscopic port hemorrhage, and subcutaneous emphysema were observed in 1 case each, but all of them improved conservatively.

Conclusion: With the laparoscopic approach, the target lesions were well visualized without being affected by the lungs, the omentum on the liver (Chilaiditi syndrome), or thick body wall. HCC cases with non-viral liver disease and recurrence have been increasing, laparoscopic RFA is considered to be one of the useful treatment options for patients who have difficulty in percutaneous treatment.



Dr. Hiroaki Kanzaki

Department of Gastroenterology,
Graduate School of Medicine, Chiba University, Japan

Exploring Tumor Microenvironment in Patients with Advanced Hepatocellular Carcinoma

Background and Aims: The combination of atezolizumab and bevacizumab has become a standard treatment for advanced hepatocellular carcinoma (HCC). Although exploring the tumor microenvironment has essential clinical implications in the era of combination immunotherapy, most studies on the tumor microenvironment in HCC are based on the analysis of archival samples at the time of HCC diagnosis. Considering the lengthy clinical course and characteristics of multicentric carcinogenesis, the tumor microenvironment may not be constant, but may differ from that at the time of advanced HCC. The present study was aimed to analyze tumor microenvironment by using needle biopsy samples obtained prior to initiation of systemic therapy in patients with advanced HCC.

Methods: HCC was confirmed via pathological examination in 70 patients and their samples were analyzed. TME was evaluated by PD-L1 and CD8 immunohistochemical analyses.

Results: 1) PD-L1 expression was higher than previous reports (28.6%). PD-L1+ expression correlated with high infiltration of CD8+ lymphocytes. 2) Among advanced HCC, patients with high AFP levels and/or vascular invasion tended to show PD-L1+ expression and high infiltration of CD8+ lymphocytes. 3) Of the 70 patients, 20 patients were able to analyze archive samples. 20.0% had a change in PD-L1 expression to positive, and 35.0% had a change in infiltration of CD8+ lymphocytes to high. 4) Of the 20 cases, gene expression analysis was performed by the PanCancer IO360 Panel in 13 cases. The result of comparing gene profile was different between the archival samples and those prior to systemic therapy in 69% of the patients on the expression heat map.

Conclusions: The tumor microenvironment might not be constant, but may change during the evolution to advanced HCC.



Dr. Cosmas Rinaldi A Lesmana

Department of Internal Medicine, Hepatobiliary Division,
Dr. Cipto Mangunkusumo National General Hospital,
Universitas Indonesia, Jakarta, Indonesia

Management Challenges for Intermediate Stage Hepatocellular Carcinoma (HCC) in the Era of Systemic Therapy

Hepatocellular carcinoma (HCC) is a global problem, and it is one of the top ten cancer in the world. Hepatitis virus infection is the main cause for HCC development in Asia Pacific region, whereas hepatitis B virus (HBV) infection is still considered as the most responsible cause, especially in Indonesia, which represent the largest country in Southeast Asia region. Based on Asian Pacific Association for The Study of The Liver (APASL) recommendation, transabdominal ultrasound examination combined with alfa fetoprotein (AFP) is the standard screening and surveillance tools in daily practice, however, standard ultrasound machine and AFP blood test are considered not good modalities for early detection of HCC development due to several factors, such as operator dependent, small size of the tumor, cirrhosis based condition, patient's factor like obesity or with the presence of hepatic steatosis, and low AFP level for dysplastic nodule or even in early HCC development. Another main problem in clinical practice, that most patients with chronic liver disease are asymptomatic where it will cause the diagnostic delay until late stage of the disease. The advantage of early abdominal CT scan or MRI study have become something excessive due to its cost and patients' comfortable.

Based on HCC guidelines, there are two common stages of the disease which is usually found in daily practice, intermediate-stage, and advance stage as it will be translated into palliative management and best supportive care (BSC) management. Most of HCC patients in the intermediate stage are still in a good condition and in the young productive age due to HBV vertical transmission in Asian region. Loco-regional therapy, such as trans-arterial chemoembolization (TACE), is still considered as the most treatment of choice for intermediate stage. It is not always giving the satisfaction result, especially for the downstaging purpose. Another strategy approach, such as combining TACE with percutaneous radiofrequency ablation (RFA) treatment has also been considered in some elective cases. However, the risk of internal bleeding, high fever, and severe pain after the procedures have also become a big concern to the patient and patient's family.

Currently, there have been options for home medication, such as oral systemic therapy, as the drug development has given a promising future for cancer control, but the side effects of the systemic therapy can suffer more the patients. Some of the patients even passed away below the survival target time. Another new option, Immunotherapy, has also been considered as a new promising treatment for unresectable HCC. However, the patient's condition, liver function, and other co-morbidities should also be counted into clinical practice before treatment decision.

In conclusions, intermediate stage of HCC is common and become a challenging situation in daily practice. Systemic therapy and immunotherapy have not shown the satisfaction results yet, however, early detection of the disease is still the most important thing to achieve the best treatment result.



Dr. Issei Saeki

Department of Gastroenterology and Hepatology,
Yamaguchi University Graduate School of Medicine, Japan

Impact of Skeletal Muscle Volume in Patients with Intermediate-stage Hepatocellular Carcinoma (HCC) Receiving Sorafenib: A Comparison with Advanced HCC Patients

Introduction: The standard treatment strategy in intermediate-stage hepatocellular carcinoma (HCC) is currently changing, and molecular target agents are often now used for patients with transcatheter arterial chemoembolization-refractory or high tumor burden. We have recently reported that skeletal muscle volume is not only a predictor of overall survival (OS), but also of post-progression survival (PPS), in HCC patients receiving sorafenib. We conducted sub-analyses of the above-mentioned data to further investigate the impact of skeletal muscle volume in intermediate-stage HCC patients compared with advanced HCC patients.

Methods: We retrospectively enrolled 356 HCC patients receiving sorafenib (BCLC stages B/C: 78/278 patients) from three hospitals in Japan. Various clinical parameters, including skeletal muscle index (SMI), were analyzed as prognostic factors of OS, progression-free survival (PFS), and PPS.

Results: Low-muscle volume was defined as a median SMI of <45 cm²/m² in males and <38 cm²/m² in females. BCLC stage C patients with high muscle volume showed longer survival and PPS than those with low muscle volume [median survival time (MST): 12.4 vs. 9.0 months, $p = 0.001$; median PPS: 7.9 vs. 5.4 months, $p = 0.002$], whereas no significant differences in OS and PPS among BCLC stage B patients with two groups were found (MST: 19.3 vs. 13.5 months, $p = 0.348$; median PPS: 9.7 vs. 10.8 months, $p = 0.578$). Additionally, there were no differences in PFS in BCLC stages B/C patients based on skeletal muscle volume. Multivariate analyses indicated that muscle volume was an independent predictor of OS and PPS in BCLC stage C HCC patients, but not in BCLC stage B HCC patients.

Conclusions: We demonstrated the different impacts of skeletal muscle volume on clinical outcomes according to BCLC staging in HCC patients receiving sorafenib. Although skeletal muscle volume is not a predictor of survival in BCLC stage B patients, these most patients progress to stage C. Therefore, these patients could benefit from the maintenance or upregulation of skeletal muscle volume ahead of advanced stage.



Dr. Rakhi Maiwall

Hepatology,

Institute of Liver and Biliary Sciences, New Delhi, India

Mechanisms and Management of Sorafenib Resistance in Hepatocellular Carcinoma

Hepatocellular carcinoma (HCC) is now recognized as the second leading cause of cancer-related deaths. Majority of tumors are diagnosed in an advanced stage despite recent advances in the recognition and management. A high rate of relapse confers a grim prognosis. HCC are vascular tumors making anti-angiogenesis inhibitors as potential targets of therapy. Sorafenib has been the backbone of treatment for advanced stage HCC. It is a multikinase inhibitor which works by inhibiting the tumor cell proliferation by blocking the RAS/RAF/Mitogen activated protein kinase-extracellular signal regulated kinase MEK/ERK pathways. The pathway is instrumental in preventing cell cycle progression or induction of apoptosis in tumor cells. Additionally, sorafenib also inhibits the platelet-derived growth factor receptor (PDGFR- β), vascular endothelial growth factor receptor (VEGFR), hepatocyte factor receptor (c-KIT) and other pathways inhibiting tumor angiogenesis. Sorafenib had been shown to be effective in management of metastatic HCC. It is the first drug approved for management of advanced HCC based on the results from two large multicentric trials. However, the efficacy of sorafenib has a limitation of both primary and acquired resistance to the drug. Tumor microenvironment, transport processes particularly in ATP-binding box transporters, epigenetics including the role of non-coding and micro RNAs have been implicated in sorafenib resistance. Another important mechanism of development of sorafenib resistance in the regulated cell death is the defects in apoptosis, pyroptosis, ferroptosis or autophagy. The tumor microenvironment is depicted by the complex cross-talk of the cancer cells with immune and non-immune cells which perpetuate HCC progression. The management of sorafenib resistance involves combining sorafenib with cytotoxic drugs like irinotecan, targeting multiple pathways for instance the epidermal-growth factor receptor (EGFR) by cetuximab, P13-AKT pathway and other immunotherapeutic drugs. Multiple studies have suggesting an encouraging role of combining immune check point inhibitors with sorafenib. These drugs have to be chosen based on assessment of tumor microenvironment for obtaining maximal response in HCC management.



Dr. Wei-Peng Yong

Department of Haematology-Oncology,
National University Cancer Institute, Singapore

Optimal Sequencing of TKI after Atezolizumab and Bevacizumab in HCC

Tyrosine kinase inhibitors such as sorafenib, lenvatinib, regorafenib and carbozantinib has been the mainstay treatment for HCC in the past decade. In the era of immunotherapy, atezolizumab and bevacizumab is the currently the standard first line therapy for advanced HCC. In this talk, we will learn about who are the patients where TKIs may have a role in the first line setting, and factors affecting sequencing of TKIs in the second line setting.



Dr. Yutaka Yasui

Department of Gastroenterology and Hepatology,
Musashino Red Cross Hospital, Japan

Systemic Therapy for Intermediate-stage Hepatocellular Carcinoma Including Real-world Data of Ramucirumab Treatment as Second or Later Line

Background and Aims: Recent advances in systemic therapy for unresectable hepatocellular carcinoma (HCC) have changed our real-world clinic, including treatment strategy for the intermediate stage HCC. Patients are considered TACE unsuitable if they are likely to exacerbate Child-Pugh grade or have a high tumor burden. However, the real-world data of systemic therapy for intermediate stage HCC is not fully established. This study aims to elucidate the real-world data systemic treatment for intermediate-stage HCC.

Method: First, we retrospectively analyzed the patients with intermediate-stage unresectable HCC who received 1st-line systemic treatment; i.e. sorafenib (n=129), lenvatinib (n=33), or atezolizumab plus bevacizumab combination therapy (n=23). Second, we analyzed patients who received ramucirumab (Ram) as 2nd or later line systemic treatment. Ram-cohort included intermediate and advanced stages. The radiological response was assessed using modified RECIST criteria.

Results: Median overall survival (OS) of the 1st-line systemic therapy in intermediate HCC patients was 18.2 months. Median progression free survival (PFS) was 4.7 months. The factors associated with survival by univariate Cox-proportional hazard model were mALBI grade 2b/3 (p=0.04), beyond up-to-7 criteria (p=0.03), neutrophil to lymphocyte ratio (NLR) >3.4 (p=0.02), and AFP >200 ng/mL (p=0.004). In multivariate analysis, NLR>3.4 (Hazard ratio 1.6, 95% C.I. 1.0-2.6, p=0.04) and AFP >200ng/mL (HR 1.7, 95% C.I. 1.1-2.5, p=0.02) were independent factors associated with survival. Ram-cohort consists of 79 patients where 39 (49.4%) were intermediate stage, 40 (50.6%) were received Ram as 2nd-line and 52 (65.8%) were AFP >1000ng/mL. Median OS was 7.5 months, which was not significantly different between 2nd-line and 3rd or later lines (8.8 months vs. 7.3 months, p=0.92). Median PFS was 3.2 months. When we only analyzed patients who received Ram as 2nd-line and were Child-Pugh A, OS was 10.3 months, and PFS was 4.4 months. The presence of extrahepatic spread (EHS) was not associated with PFS (present 3.2 months vs. absent 3.7 months, p=0.30) and patients who had major vascular invasion (MVI) showed similar PFS to those who had not (present 3.1 months vs. absent 3.2 months, p=0.84). PFS was not significantly different between patients with intermediate-stage HCC and those with advanced-stage HCC (3.7 months vs. 3.1 months, p=0.17).

Conclusions: OS of 1st-line systemic therapy for intermediate stage HCC was 18.2 months. NLR and pre-treatment AFP levels were factors associated with OS. Ramucirumab treatment showed consistent PFS irrespective of treatment line, BCLC stage, presence of EHS, or presence of MVI.



Dr. Keisuke Koroki

Department of Gastroenterology,
Graduate School of Medicine, Chiba University, Japan

Analyses of Intermediate-stage Hepatocellular Carcinoma Patients Receiving TACE Prior to Designing Clinical Trials

Patients with intermediate-stage hepatocellular carcinoma (HCC) having a high tumor burden exhibit a high frequency of recurrence and progression to advanced stage after transarterial chemoembolization (TACE). Novel combination immunotherapies, such as atezolizumab+bevacizumab are expected to replace TACE. A clinical trial comparing TACE with combination immunotherapies is needed to prove whether it is feasible. We evaluated the effectiveness of TACE in order to design clinical trials and identify limited high-burden populations that could be replaced from TACE to combination immunotherapies. We retrospectively analysed 316 intermediate-stage HCC patients in our hospital between 2003 and 2015. When high burden was defined as up to seven criteria out, there was no significant difference in prognosis between low burden and high burden. In all models, high-tumor burden patients showed a poor durable response rate (DRR) of ≥ 6 months and a poor prognosis after TACE. Patients with confirmed durable response of ≥ 6 months showed better survival outcomes for high-tumor burden intermediate-stage HCC. When designing clinical trials comparing TACE with combination immunotherapies, up to seven criteria may not be appropriate as a definition of high burden. And a DRR of ≥ 6 months could be an alternative endpoint.



Dr. Hasmik Ghazinyan

Nork Clinical Hospital of Infectious Diseases,
Yerevan, Armenia

Hepatocellular Carcinoma Emergence in Armenia: Outcome of Multiple Risk Factors, January 2019 to March 2020 Nork Clinical Hospital of Infectious Diseases

Ghazinyan H.1, Pineau P.2

1 Nork Clinical Hospital of Infectious Diseases, Yerevan, Armenia

2 Institut Pasteur, Unite Organisation nucleaire et oncogenese, INSERM U9993, Paris, France

Background: Hepatocellular carcinoma (HCC) is most often multifactorial: Alcohol, HCV, HBV, other (e. g. NASH), and is strongly modulated by the environment. Primary liver cancer (PLC) incidence in Northern Eurasia according to GLOBOCAN. Incidence in Armenia is above 13 cases/105 in men and above 6.5/105 in women. PLC emerged as a major health threat in Armenia and the incidence of Liver Cancer in the country is higher than in neighboring countries

We intend to provide the first detailed description of PLC risk factors and clinical presentation in Armenia.

Methods: A series of 69 patients were diagnosed with PLC. Demographic data, risk factors, histology, PLC work-up, symptoms and biological variables were collected at the time of diagnosis and patient survival was determined long-term.

Results: HCC was found in the majority of cases of PLC (95.6%) while tumors appeared in patients with cirrhosis in most cases (90.3%). The sex ratio of this series was (M:F=3.9) with the mean age of patients (56.9±11.4 years). HCV was the main risk factor (68.1% of cases) followed by heavy alcohol consumption (51.7%) followed by HBV (18.8%). Metabolic disorders were prevalent with 63.7% of the patients with obesity being the most common (BMI≥30), also Some life style toxic factors (alcohol and tobacco consumption) significantly precipitate early HCC onset. According to our data there is accumulation of risk factors in most patients 34.7% (n=24) of patients present with 4 risk factors, 15.9% of patients (n=11) present a single risk factor. The median overall survival time was 10 months (IQR:6-14). Younger patients (≤57.0 years) were characterized by an even high proportion of male sex (94.1% vs 65.7% for patients over >57 years old, P<0.01), as were frequent tobacco consumption (85% vs 58.8%, P<0.05). We noticed that HBV-infected patients self-reported significantly higher rates of somatic cancers in their families (92.3% vs 58.6%, P<0.05).

Conclusions:

- The current problem of HCC in Armenia seems to be due to the presence of HCV spread with non-infectious risk factors including heavy alcohol intake, tobacco consumption, and metabolic disorders especially non-alcoholic fatty liver disease
- Further studies are warranted to characterize viral characteristics and molecular alterations that may promote liver tumorigenesis in Armenia.



Dr. George Lau

1. Humanity and Health Clinical Trial Centre, Humanity and Health Medical Group, HKSAR
2. Liver Diseases & Transplant Centre, The Fifth Medical Centre of Chinese PLA General Hospital, Beijing- Humanity & Health Medical Group, HKSAR China

Management of Intermediate Hepatocellular Carcinoma - Past, Present and Future

In our practice of clinical Hepatology in Asia-Pacific region, intermediate stage hepatocellular carcinoma (HCC), mostly due to chronic hepatitis B infection, remains the most important clinical burden. In accordance to Barcelona Clinic Liver Cancer (BCLC) staging system, intermediate stage (stage B) HCC includes multiple tumorous lesions confined to the liver without vascular invasion in a patient with persevered liver functions (Child-Pugh A or B) and good performance status. Over the past three decades, little progress has been made to improve the outcome of those patients with intermediate stage HCC. This is mainly due to its wide heterogeneity in etiology, tumor burden and liver function (and stage of liver fibrosis). To date, with the use of Trans-Arterial Chemo-Embolization (TACE) with or without drug-eluting bead (TARE), an improved 2-years survival could be obtained. In selected cases, liver transplantation has also been offered to those “down-staged” to the Milan, University of California San Francisco (UCSF) or Up-to-Seven criteria. However, the disease-free and overall survival in these cases remain unclear. Disappointingly, with the rapid development and approval of tyrosine kinase inhibitors (TKIs) as systemic therapy for advanced HCC, its combinations with TACE have so far failed to provide beneficial clinical outcomes. Nonetheless, in a pooled results from 2 phase 3 studies (REACH and REACH-2), median OS for ramucirumab versus placebo was 13.7 versus 8.2 months; HR (95%): 0.43 (0.23–0.83) for intermediate HCC with prior sorafenib therapy. Additionally, in a recent proof-of-concept study which included 642 consecutive patients with multinodular intermediate-stage HCC exceeding the up-to-seven criteria with Child–Pugh A liver function, who usually do not benefit from TACE, lenvatinib provides a more favorable outcome than TACE. In the coming future, with the renewed understanding of the immune tumor microenvironment, new innovative approaches, such as addition to TACE with durvalumab plus bevacizumab (EMERALD 1), lenvatinib plus pembrolizumab (LEAP 012), atezolizumab plus caboznatinib (COSMIC 312), nivolumab plus ipilimumab (CheckMate 74 W) and nivolumab (TACE 3) are expected to come into play. On the other hand, more personalized approach with the aid of different scoring system and new biomarkers are expected to further improve the management (and even “cure”) of our patients with intermediate stage HCC.



Dr. Masatoshi Kudo

Department of Gastroenterology and Hepatology,
Kindai University Faculty of Medicine, Osaka, Japan

Treatment Strategy of Intermediate-stage HCC: LEN-TACE Sequential Therapy

LEN-TACE sequential therapy was developed in proof-of-concept studies based on the marked prolongation of OS in patients with intermediate-stage HCC beyond the up-to-seven criteria. OS was 37.9 months with upfront lenvatinib with subsequent selective TACE vs. 21.3 months with TACE alone, indicating that LEN-TACE sequential therapy significantly improved OS (HR, 0.48; 95% CI, 0.16–0.79; $p < 0.01$). PFS, ORR per mRECIST, and preservation of liver function were also favorable in the lenvatinib-treated group. In addition, 5 of 30 patients (17%) who received LEN-TACE sequential therapy achieved cancer-free drug-free status, indicating that this therapy can potentially achieve cure in patients with intermediate-stage HCC beyond the up-to-seven criteria. The results were reproduced in many clinical studies, and LEN-TACE sequential therapy has become a well-established approach for TACE-unsuitable intermediate-stage HCC in Japan. The idea that systemic therapy with a drug that achieves a high response (e.g., lenvatinib) combined with subsequent selective TACE for residual viable tumors increases the curative effect of TACE, preserves liver function, suppresses hypoxia-inducible cytokines, and ultimately improves survival in TACE-unsuitable intermediate-stage HCC led to the recommendation of this sequential therapy in the consensus statements of the Asia-Pacific Primary Liver Cancer Expert (APPLE) association and the Japan Society of Hepatology (JSH). Thus, both the APPLE and JSH consensus statements recommend LEN-TACE sequential therapy as the first choice of treatment for TACE-unsuitable patients with intermediate-stage HCC. Upfront systemic therapy was also recently recommended for TACE-unsuitable patients in the e-updated European Society for Medical Oncology clinical practice guidelines [12]. Further, the American Association for the Study of Liver Diseases consensus statement, which was updated in 2020, recommends upfront systemic therapy in addition to TACE in patients with intermediate-stage HCC with a high tumor burden. This revision (i.e., systemic therapy as a treatment option for intermediate-stage HCC) is the first substantial revision in 20 years since the establishment of the Barcelona Clinic Liver Cancer Group algorithm in 1999.

Lenvatinib is associated with a high response rate per mRECIST, a quick response in TACE-resistant tumors such as confluent multinodular type or poorly differentiated HCCs, and a synergistic effect with TACE. Therefore, LEN-TACE sequential therapy has become an established treatment option that may lead to cancer-free drug-free status or longer survival even when complete response (CR) is not achieved in TACE-unsuitable intermediate-stage HCC.



Dr. Yosuke Hirotsu
Genome Analysis Center,
Yamanashi Central Hospital, Japan

Diagnosis, Genome Surveillance and Immune Response of COVID-19

After the COVID-19 pandemic, it became urgent to establish a testing and diagnostic system for SARS-CoV-2. We have set up RT-qPCR, antigen and antibody tests in our hospital, and have established a system that allows testing 24 hours a day, 7 days a week. We have conducted in-depth analysis of the immune response in the body after COVID-19 mRNA vaccination and have confirmed that a robust boost response occurs regardless of age or gender. Whole genome analysis of the virus was conducted to monitor the genome for the emergence of new threatening variants of concern (VOCs). After vaccination, the immune response to breakthrough infection and the subsequent clinical course were also analyzed.



Dr. Masaya Sugiyama

Genome Medical Sciences Project, Institute,
National Center for Global Health and Medicine, Japan

Serum Predictive Factors for Severe Symptoms of COVID-19

Severe acute respiratory syndrome coronavirus 2 (SARS-CoV-2) infection leads to the development of severe/critical symptoms. COVID-19, a novel coronavirus-related illness, has spread worldwide. Patients with apparently mild/moderate symptoms are abruptly able to change into severe pneumonia during a day. Severe symptoms could lead to serious condition or death. To avoid the development of severe symptoms, it is important to predict patients who develop severe symptoms before their onset. In this study, a comprehensive analysis of serum chemokines and cytokines was conducted using serial serum samples from COVID-19 patients. The expression profiles of humoral factors and the clinical and laboratory data were collected to analyze the association with the development of severe pneumonia along the time axis. We found five factors, CCL17, IFN- λ 3, IL-6, IP-10, and CXCL9 associated with the development of severe symptoms. The factors were classified into two groups. One included IFN- λ 3, IL-6, IP-10, and CXCL9, and their values surged and decreased rapidly before the onset of severe pneumonia. The other included CCL17, which value was lower in severe/critical groups at an early phase of SARS-CoV-2 infection than mild/moderate and non-COVID-19 patients. These data were validated in independent cohort samples. Although high expression of CCL17 is related with allergic diseases, it is a first report that the down-regulation of CCL17 lead to a disease. And we firstly discovered the relationship between IFN- λ 3 and COVID-19 in this study. These predictive factors could be promising bio-markers to find severe/critical patients at an early phase of infection.



Dr. Shuichiro Shiina

Professor, Department of Gastroenterology,
Juntendo University, Japan

Management of Hepatocellular Carcinoma in the Era of COVID-19

COVID-19 has been giving the devastating impact on the current medical care system. At the moment, the novel coronavirus infection has been slowly settling down in Japan and the usage rate of beds has decreased. However, there are still concerns about arrival of sixth wave of novel coronavirus which would tighten up the medical care provision system. There are quite many guidelines on COVID-19, but only a few on the management of hepatocellular carcinoma (HCC) during COVID-19 pandemic. We develop recommendations to preserve adequate clinical practice for the management of HCC (<https://rdcu.be/catEy>). Experts of HCC in the Asia–Pacific region exchanged opinions via webinar, and the following recommendations were formed. Close contact should be minimized to reduce possible exposure of both medical staff and patients to the novel coronavirus. To prevent transmission of the virus, meticulous hygiene measures are important. Most patients with HCC are elderly, and elderly people are more likely to become severely ill when infected with the novel coronavirus. With the decrease in regular medical service, the medical staff may be mobilized to provide COVID-19-related patient care. However, diagnosis and treatment of HCC should not be delayed because of COVID-19 pandemic. The management of HCC should be the same as in non-pandemic circumstances. HCC is highly malignant, thus it is recommended not to delay curative treatment such as surgery and ablation. In addition, it is clearly stated that minimally invasive ablation should be selected if surgery is at high risk. The results of a multicenter randomized controlled trial (SURF trial) of hepatectomy and radiofrequency ablation were presented this year, and not only overall survival rate but also recurrence-free survival rate did not show superiority of surgical treatment. However, a kind of triage is necessary even among patients with HCC when resources are insufficient for all to be treated. Curative treatments should be periodized and cytoreductive or non-curative treatment such as vascular interventions and systemic therapies may be postponed until it can be performed safely with sufficient resources. For patients with confirmed or suspected to be infected with the novel coronavirus, diagnosis and treatment should be postponed until the virus is eliminated or they are confirmed as not being infected with it. These are collection of measures implemented by front-line medical professionals. We would evolve these recommendations over time as more real-world data becomes available.



Dr. Takuya Yamagishi

Antimicrobial Resistance Research Center,
National Institute of Infectious Diseases, Japan

Responses to COVID-19 Outbreaks in Healthcare Setting in Japan, January 2020 - September 2021

Novel coronavirus disease (COVID-19) is an emerging infectious disease that causes respiratory symptoms, sometimes results in fatal outcome (fatality 2.5% according to WHO). Once the disease entered into the country, most of the countries have been seeing large number of cases that were out of the capacity in their medical system, even in highly developed countries. Introduction of effective vaccines and promising monoclonal antibodies gave us a hope, and the situation is getting better in many countries. Although several drugs and vaccines become available, rapid outbreak response is still one of the main control measures to fight against COVID-19 across the world. As a national rapid response team under the Ministry of Health, Labour and Welfare, staff at the National Institute of Infectious Diseases supported local governments to conduct outbreak responses to COVID-19 events. Between January 2020 and September 2021, we engaged in more than 200 outbreaks and approximately half of them were healthcare-associated outbreaks. The hospitals specialized in cancer and the units for oncology patients in general hospitals were also affected, which sometimes caused the poor outcome of the cases.

The response to COVID-19 outbreak requires multifactorial approaches including case identification and isolation, rapid contact identification and isolation, providing free testing opportunity, providing medical system for the appropriate treatment (e.g. oxygen, monoclonal antibody, or steroid) and beds for hospitalization for moderate or severe cases, strengthening infection prevention and control among staff members and building and implementing business contingency plan if the staff members were in shortage because the number of cases and close contacts among staff members became too large to operate the routine work at their facilities. In this session, I would like to introduce the experience of COVID-19 outbreak response in healthcare settings in real world.



Dr. Hiroshi Yotsuyanagi

Professor, Chairman, Division of Infectious Diseases,
Advanced Clinical Research Center,
The Institute of Medical Science,
The University of Tokyo, Japan

COVID-19 in Japan

The first COVID-19 patient in Japan was confirmed in January 2020. Since then, more than 1.7 million cases have been reported, of which about 1% have died. Up to now, five waves of infected people have been seen, and the virus strain has changed each time. From July to September 2021, the delta strain was prevalent and many infected people had respiratory failure. COVID-19 is a disease with hepatic dysfunction from the early stage of onset, but the strongest hepatic dysfunction was experienced during the fifth wave. The number of infected people has decreased with the rapid spread of vaccination, but the true reason for the decrease in infected people is not clear.



Dr. Takamichi Murakami

Department of Radiology,
Kobe University Graduate School of Medicine, Japan

Imaging Evaluation of HCC in the System Chemotherapy Era

Multiphasic dynamic contrast-enhanced CT and MRI studies may contribute to detection, characterization, and the assessment of treatment response and prediction of prognosis in patients with HCC who have candidate for systemic therapy with molecular targeting agent or immune checkpoint inhibitor.

Recent advances regarding both hardware and software developments have enabled us to overcome several drawbacks on the dynamic studies. For the CT examination, virtual monochromatic images or material decomposition algorithms in dual-energy CT, or post-processing technique of contrast enhancement boost images can overcome lower detection sensitivity by increasing the degree of contrast enhancement for the diagnosis of small HCCs. Material decomposition images, such as iodine map images, can also estimate iodine density (mgI/ml) in the tumor quantitatively, indicating tumor vascularity.

For the MR examination, radial k-space sampling with k-space weighted image contrast reconstruction (free-breathing sequence) is a useful tool for obtaining MR imaging data under free breathing and can be clinically applied in patients with impaired breath-holding capability in the dynamic study with hepatobiliary specific contrast agent. The free-breathing sequence can achieve dynamic MRI with high temporal resolution without sacrificing spatial resolution or signal-to-noise ratio (SNR), leading to the improvement of visual assessment of enhancement.

Gd-EOB-DTPA enhanced MR images may be a biomarker to predict treatment effect of immune checkpoint inhibitor (ICIs), of HCC. The therapeutic mechanism of immune checkpoint inhibitors is largely dependent on the number of lymphocytes in the tumor. In other words, “immune-cold” tumors with few lymphocytes in the tumor microenvironment have been found to be less response to ICIs. Based on the association between β -catenin mutation and OATP1B3 receptor expression, the possibility of non-invasive evaluation of the immune-cold tumors using EOB-MRI is being explored.



Dr. Hidenori Toyoda

Department of Gastroenterology,
Ogaki Municipal Hospital, Japan

Tumor Marker Profiles in Patients with Viral and Non-viral Hepatocellular Carcinoma

Tumor markers of hepatocellular carcinoma (HCC) are supportive tools of the detection and diagnosis of HCC. We compared tumor marker profiles of early-stage HCC between patients with hepatitis virus-related HCC and patients with non-viral HCC. We also characterized tumor marker profiles in patients with HCC that developed after the eradication of hepatitis C virus (sustained virologic response; SVR).

In the multicenter study, the levels of three tumor markers of HCC, alpha-fetoprotein (AFP), lens-culinaris agglutinin-reactive fraction of AFP (AFP-L3) and des-gamma-carboxy prothrombin (DCP)/protein induced by vitamin K absence-II (PIVKA-II), were measured at the diagnosis of initial HCC of BCLC class 0 or I. They were compared between patients with viral HCC, patients with non-viral HCC, and those with HCC that developed after SVR (SVR-HCC).

The study included 2543 patients with viral HCC, 869 patients with non-viral HCC, and 220 patients with SVR-HCC. The median levels (75% IQR) of AFP, AFP-L3, and DCP were 13.0 ng/mL (5.0–62.7), 0.5% (0–7.1), 30 mAU/mL (18–95), respectively, in viral-HCC, 6.7 (3.6–15.7), 0.5 (0–7.8), 42 (22–288), respectively, in non-viral HCC, and 6.0 (3.7–13.8), 0.5 (0.5–6.4), 24 (19–43), respectively, in SVR-HCC. AFP levels were significantly higher in viral HCC than in non-viral HCC and SVR-HCC (viral vs. non-viral, $p < 0.0001$; viral vs. SVR, $p < 0.0001$). In contrast, DCP levels were significantly higher in non-viral HCC than in viral HCC and SVR-HCC (non-viral vs. viral, $p < 0.0001$; non-viral vs. SVR, $p < 0.0001$). SVR-HCC showed lowest levels of both AFP and DCP. The percentage of patients with tumor marker levels above conventional cut-offs (20 ng/dL for AFP, 10% for AFP-L3, and 40 mAU/mL for DCP) in viral HCC, non-viral HCC, and SVR-HCC were 41.5%, 21.9%, and 21.7%, respectively, for AFP (viral vs. non-viral, $p < 0.0001$; viral vs. SVR, $p < 0.0001$), 19.6%, 19.9%, and 19.3%, respectively, for AFP-L3, and 41.0%, 51.1%, and 28.6%, respectively, for DCP (non-viral vs. viral, $p < 0.0001$; non-viral vs. SVR, $p < 0.0001$).

Whereas AFP predominantly elevated in viral HCC, DCP elevation was predominant in non-viral HCC. The value of HCC tumor markers may be modest in SVR-HCC. The patterns of profiles of tumor marker elevations may differ based on the etiology of HCC. These should be taken into consideration when using tumor markers in surveillance and the diagnosis of HCC. In addition, the combination use of these HCC tumor markers may improve their value to support the detection and diagnosis of HCC.

Session 16: Diagnosis of HCC

Dr. Do Young Kim

Professor, Severance Hospital,

Yonsei University College of Medicine, Korea

To be announced.



Dr. Hiroko Iijima

Department of Internal Medicine,
Division of Gastroenterology and Hepatology,
Hyogo College of Medicine, Japan

Diagnosis of Hepatocellular Carcinoma by Contrast-enhanced Ultrasound -Focusing on Early Hepatocellular Carcinoma

Background: It is known that blood flow changes during the multi- step carcinogenesis of hepatocellular carcinoma are characterized by a decrease in normal hepatic artery blood flow, followed by a decrease in portal blood flow, and then an increase in neoarterial blood flow. Sonazoid is phagocytosed by Kupffer cells. In moderately differentiated hepatocellular carcinoma, the number of Kupffer cells decreases and hypointensity during CEUS Kupffer phase. eHCC is thought to show isointensity or hypointensity during CEUS Kupffer phase. The hepatocellular phase of eHCC on Gd-EOB-DTPA contrast-enhanced MRI (EOB-MRI) is mostly depicted as a low-signal nodule.

Objective: The diagnostic ability for eHCC with EOBMRI, focusing on CEUS.

Materials and Methods: 880 out of 1352 nodules that were evaluated with CEUS and EOB-MRI from April 2008 to December 2020 were included. We excluded nodules that were diagnosed as benign liver tumors or malignant liver tumors that were differentiated from HCC by imaging or histological evaluation.

Results: Out of the 880 nodules, hyper-/non-hypervascular at the CEUS arterial phase or EOB-MRI arterial phase were 688/192, respectively. Out of the 192 non-hypervascular nodules, iso-/hypovascular at the CEUS portal phase were 147/45, respectively. Out of the 45 hypovascular nodules, iso-/hypo-intensity at the Kupffer phase were 16/29, and that showed a decrease in the portal blood flow and suggested eHCC were suspected even though some nodules showed a potential decrease of Kupffer cells. Iso-/hypo-intensity at the EOB-MRI hepatobiliary phase were 13/32, respectively. Out of 147 isovascular nodules at the CEUS portal phase, iso-/hypo-intensity at the Kupffer phase were 128/19. Although it is not clear what caused the decrease in the portal blood flow in the 19 nodules, the result suggests eHCC may be included in this group. Among these 19 nodules, iso-/hypo-intensity at the EOB-MRI hepatobiliary phase were 5/14, respectively.

Discussion: Our results indicate that nodules with arterial hypovascular on CEUS, decreased portal blood flow, Kupffer phase with iso to hypointensity, and decreased intensity during EOB-MRI hepatobiliary phase are considered to be potentially diagnostic of eHCC.

Conclusion: Imaging with a combination of Sonazoid CEUS and EOB-MRI is important for the diagnosis of eHCC.



Dr. Takeji Umemura

Department of Gastroenterology,
Shinshu University School of Medicine, Japan

aMAP Score Prediction of Hepatocellular Carcinoma Development in Patients with Chronic Liver Disease

Prediction of HCC development in patients with chronic liver disease remains a clinical necessity. Numerous studies have attempted to identify the factors predicting HCC development in patients with chronic liver disease. The clinical utility of such liver fibrosis markers as the FIB-4 index, APRI, and Mac-2-binding protein glycosylation isomer, as well as noninvasive indirect liver stiffness measurements, such as FibroScan and MRE, has been studied extensively. The optimal method for predicting HCC remains under scrutiny.

Recently, a new HCC risk score, aMAP score, which consists of age, gender, albumin, bilirubin, and platelet count, was reported to be useful in predicting the development of HCC in chronic liver disease. The score appears more suitable because the parameters are easily accessible in most primary care settings

DAA has been developed as a treatment for chronic hepatitis C, and many patients have achieved SVR. On the other hand, surveillance for cases that develop HCC after SVR is an important issue. In this presentation, I will report whether aMAP score is predictive for post-SVR HCC occurrence in chronic HCV patients and whether it is useful for predicting HCC in a cohort of patients with primary biliary cholangitis who are under long-term follow-up at my institution.



Dr. Yusuke Kawamura

Department of Hepatology, Toranomon Hospital, Japan

Treatment Strategy of Intermediate Stage HCC Using Lenvatinib “Lenvatinib TACE Sequential Therapy”

The Barcelona Clinic Liver Cancer (BCLC) system is widely used for staging HCCs, and transarterial chemoembolization (TACE) is recommended for treatment of the intermediate stage (stage B). In addition, the APPLE Consensus Statements established the following three TACE unsuitable conditions: (i) Unlikely to respond to TACE: Confluent multinodular type, massive or infiltrative type, simple nodular type with extranodular growth, poorly differentiated type, intrahepatic multiple disseminated nodules, or sarcomatous changes after TACE, (ii) Likely to develop TACE failure/refractoriness: up-to-7 criteria out, (iii) Likely to become Child-Pugh B or C after TACE: up-to-7 criteria out (especially, bilobar multifocal HCC), mALBI grade 2b. Meanwhile, lenvatinib treatment also shows favorable results in TACE-resistant tumors such as poorly differentiated, confluent multinodular type or infiltrated type HCCs. Recently, the TACTICS trial showed better progression-free survival in combination use of sorafenib plus TACE for unresectable HCC compared with TACE alone. Similar to the TACTICS trial, the combination of Lenvatinib and TACE (Lenvatinib TACE sequential therapy) has shown encouraging results in various clinical reports, including the TACTICS-L study. In addition, the TACTICS-L study presented a high complete response rate at 6week. Moreover, better treatment outcomes in progression-free, post-progression and overall survival are reported in other clinical research. However, there are many unclear points about mechanisms of enhancing therapeutic effect in this sequential therapy.

Therefore, this session aims to explore these mechanisms that enhance the therapeutic effect of TACE.



Dr. Yoshinari Asaoka

Department of Medicine,
Teikyo University School of Medicine, Japan

Lenvatinib for Intermediate Stage HCC

Intermediate stage HCC is a stage that includes a diverse group of cases, excluding early stage and advanced stage. The main treatment for intermediate stage HCC was TACE, but the degree of response to TACE varies from case to case. In some cases, the effect is poor and repeated TACE results in impaired liver reserve. TACE-unsuitability is defined as clinical conditions that prevent a survival benefit from TACE or conditions that TACE is even harmful. Up-to-7 criteria out nodules are thought to be TACE-unsuitable. Recent studies have shown the efficacy of Lenvatinib for intermediate stage HCC beyond up-to-7 criteria. Basic considerations also suggest a complementary role for TACE and Lenvatinib. Based on these data, the treatment strategy for TACE unsuitable intermediate stage HCC is changing. To confirm this paradigm, Lenvatinib-TACE sequential therapy for intermediate stage HCC is applied in clinical settings in Japan. TACTICS and TACTICS-L have clearly shown the possibility that the harmonic combination of TACE and TKI would benefit for intermediate HCC. In this presentation, we would like to show the role of Lenvatinib in the treatment of intermediate stage HCC.



Dr. Eishiro Mizukoshi

Department of Gastroenterology,
Kanazawa University Hospital, Japan

The Dawn of a New Era in Hepatocellular Carcinoma Treatment with Molecular Targeted Therapy and Local Therapy

In the field of cancer treatment, a phenomenon called the "abscopal effect" has been known for a long time. It is known that radiation therapy for cancer not only regresses tumors in the irradiated area, but also regresses tumors in distant areas that were not irradiated, i.e., outside the irradiation area. The mechanism of the abscopal effect is thought to be the activation of anti-tumor immunity, mainly tumor-specific T cells, by irradiation, but this is rarely experienced in actual clinical practice.

On the other hand, with the advent of immune checkpoint inhibitors in cancer therapy, the abscopal effect has come to be regarded as an important phenomenon in the immunotherapy of cancer. One of the reasons for this is that it has been reported not only in animal models but also in humans that the addition of immune checkpoint inhibitors to local cancer therapies that exert the abscopal effect can further enhance the anti-tumor immune response of the host.

Local therapies for hepatocellular carcinoma (HCC) include transcatheter arterial chemoembolization (TACE) and radiofrequency ablation (RFA). These therapies have been reported to enhance the anti-tumor immune response to HCC after treatment, which may be a mechanism similar to the abscopal effect of radiotherapy. The use of immune checkpoint inhibitors in combination with such local therapy has the potential to improve the curative effect of local therapy in early-stage cancers and inhibit recurrence. In addition, in advanced cancers, immune checkpoint inhibitors administered after local therapy for some tumors may further enhance the anti-tumor effect.

In this presentation, I will show the therapeutic strategy for the combination of local therapy and immunotherapy for HCC, focusing on the anti-tumor immune response.



Dr. Levent Doğanay

Professor of Gastroenterology,
Umraniye Teaching and Research Hospital,
School of Medicine, University of Health Sciences, Turkey

Adjuvant Systemic Therapies in Intermediate HCC

Hepatocellular cancer is one of the most prevalent cancers throughout the world. In most countries most of the cases are detected at late stage resulting in high mortality rate with a mortality to incidence ratio around 1. Treatment options for very early and early stages are local ablative therapies, surgical resection, or transplantation. When HCC is multinodular (beyond Milan criteria) but without portal vein invasion or metastasis, the tumor stage is determined as intermediate stage. The recommended treatment for intermediate HCC is trans-arterial therapies and trans-arterial chemo-embolization (TACE) is globally adopted as standard treatment. However, the recurrence rate is substantial even in one year follow up, rationalizing adjuvant therapies. Prior trials failed to show benefit of adjuvant tyrosine kinase inhibitors, but with a different study design; tyrosine kinase inhibitor, multi-kinase inhibitors and PD-L1 inhibitor – anti VEGF combination might work. In this presentation novel treatment strategies those combines TACE with systemic treatments in intermediate HCC are discussed.



Dr. Chun-Jen Liu

Department of Internal Medicine and Hepatitis Research Center,
National Taiwan University College of Medicine and Hospital, Taiwan

Value of Lenvatinib in the Treatment of Intermediate Stage HCC

The incidence rate of hepatocellular carcinoma (HCC) is expected to increase, with most cases occurring in Asia-Pacific region. The majority of HCC development is due to chronic infection with hepatitis B or C virus. Unfortunately, since early detection rate is not high, a significant proportion of patients are diagnosed of HCC at late stage incapable of receiving curative therapy. Advancements in the treatment of HCC over the past few decades have been remarkable. New treatment modalities or strategies (for example, drug-eluting beads and selective internal radiation therapy) have been shown to improve the treatment outcomes. Most importantly, recent progress in systemic therapies has improved the prognosis of patients with unresectable or advanced HCC (uHCC or aHCC). Nowadays, six regimens of systemic therapies have become available in most countries, following release of phase III trial data (sorafenib, lenvatinib, regorafenib, cabozantinib, ramucirumab, and atezolizumab plus bevacizumab). In a global randomized phase III trial (REFLECT), lenvatinib has been shown to improve the overall survival of patients with uHCC by statistical confirmation of non-inferiority to sorafenib. Notably, lenvatinib significantly improved progression-free survival versus sorafenib (median: 7.4 months versus 3.7 months). Landscape in the treatment of uHCC is changing. For patients with intermediate stage HCC, transarterial chemoembolization (TACE) remains the main stream of treatment. However, certain subject may be unsuitable for TACE or at high risk of liver reserve deterioration after TACE. Lenvatinib alone or in combination with TACE has been shown to improve the survival of this group of patients in preliminary data and pilot study. Its potential efficacy will await future large clinical trial or cohort data.



Dr. Naoki Matsumoto

Division of Gastroenterology and Hepatology,
Department of Medicine, Nihon University School of Medicine, Japan


Contrast-enhanced Ultrasonography for Blood Flow Detection in Hepatocellular Carcinoma During Lenvatinib Therapy

Aim: Blood flow reduction after initiation of lenvatinib therapy may not always indicate of tumor necrosis. This study aimed to compare the blood flow detectability of contrast-enhanced ultrasonography (CEUS), contrast-enhanced computed tomography (CT), and contrast-enhanced magnetic resonance imaging (MRI) in hepatocellular carcinoma during lenvatinib therapy.

Methods: Total 12 cases underwent CEUS and contrast-enhanced CT/MRI within two weeks, during lenvatinib therapy. Vascularity in CEUS and CT/MRI were compared.

Results: At the time of CEUS examination, the median period from the start of lenvatinib was 227 ± 210 (31–570) days. CEUS showed hyperenhancement in eight cases (66.7%), hypoenhancement in two cases (16.7%), and no enhancement in one case (8.3%), while CT/MRI showed hyperenhancement in one case (8.3%), ring enhancement in three cases (25.0%), and hypoenhancement in eight cases (66.7%) ($p = 0.007$) (Figure 2-5). Transarterial chemoembolization (n=3), radiofrequency ablation (n=2), and stereotactic body radiation therapy (n=2) were performed after blood flow detection by CEUS.

Conclusions: Viability of the HCC should be confirmed using CEUS, when contrast-enhanced CT/MRI reveals lesion hypo-enhancement during lenvatinib therapy.



Dr. Chiun Hsu

Graduate Institute of Oncology,
National Taiwan University (NTU) College of Medicine.
Department of Medical Oncology, NTU Cancer Center, Taiwan

Guidelines in Evolution: Systemic Therapy for Intermediate-stage HCC

Advancement in systemic therapy has transformed the treatment landscape for patients with advanced hepatocellular carcinoma (HCC). Multiple options of systemic therapy in the first- and second-line setting are available, and more are expected to come. The advancement also ushered in new concepts and definition of intermediate stage HCC, as reflected by the most updated version of international practice guidelines. However, numerous knowledge gaps emerged when we applied clinical trial data to real-world practice. In this presentation, the knowledge gaps between data from pivotal clinical trials of systemic therapy for HCC and real-world practice will be reviewed. Challenges of bridging the gaps by systemically collecting and analyzing real-world data will be discussed.



Dr. Hideki Iwamoto

1 Division of Gastroenterology, Department of Medicine, Kurume University
School of Medicine

2 Iwamoto Internal Medicine Clinic, Japan

Importance of Keeping Balance between Therapeutic Effects and Adverse Events in Lenvatinib for Hepatocellular Carcinoma ~ Refinement of Administration Schedule and Combination with Transarterial Therapy ~

Background: Lenvatinib is an effective and evidenced molecular targeted agent (MTA) with high response rate for unresectable hepatocellular carcinoma (HCC). On the other hand, lenvatinib is a drug which is difficult to be administered for long term because of development of adverse events (AEs). Therefore, it is essential for long-term administration of lenvatinib to keep balance between therapeutic effects and AEs by refinement in lenvatinib treatment.

Material and Methods:

- ① We retrospectively assessed the therapeutic effects and AEs of 135 patients treated with lenvatinib and improvement of tolerability and therapeutic efficacy of 30 patients treated with the weekends-off administration method (weekends-off: 5 days-on/2 days-off administration).
- ② We retrospectively assessed the therapeutic effects of 132 patients with intermediate HCC treated with lenvatinib monotherapy (n=79) and lenvatinib combined with transarterial therapy (alternating therapy/AT, n=53).

Results:

- ① The incidence rates of AEs were 82.1% at any grade and 49.6% at over grade 3. Fatigue was the most important AE which caused dose reduction and discontinuation of treatment. Of the 30 patients who received weekends-off lenvatinib, 66.7% of patients tolerated the AEs and 61.5% of patients revealed improvement the therapeutic response. The weekends-off lenvatinib significantly prolonged administration period ($p<0.001$).
- ② The patients who could administer AT with lenvatinib and transarterial therapy showed significant longer overall survival than lenvatinib monotherapy (AT: not reached, monotherapy 17.8 months, $p<0.01$). The factors which could administer AT was younger age (under 80 years old) and preserved liver function (modified Albumin-bilirubin grade 1/2a). The median administration period was 466 and 168 days in AT and lenvatinib monotherapy, respectively ($p<0.001$).

Conclusion:

These results suggested that refinement of administration schedule and combination therapy between lenvatinib and transarterial therapy was promising for long-term administration of lenvatinib.



Dr. Pil Soo Sung

Department of Internal Medicine,
The Catholic University of Korea, Republic of Korea

Role of Tumor Immunogenicity and Tumor-associated Macrophages in Multi-Kinase Inhibitor Responses for Hepatocellular Carcinoma

The crosstalk between tumor cells and various cell types in the tumor microenvironment is strongly related to HCC progression and treatment resistance. Monocytes are recruited to the HCC tumor microenvironment by various factors and become tumor-associated macrophages (TAMs) with distinct phenotypes. For patients with stage C or B BCLC who are not suitable for local or surgical treatment, systemic therapies are recommended as a first-line treatment. The recent randomized phase 3 trial REFLECT demonstrated that lenvatinib is noninferior to sorafenib in overall survival in treatment-naïve unresectable HCC. Additionally, lenvatinib had better progression-free survival compared to sorafenib as a salvage therapy for transarterial treatment. This result may be due to the immune-modulatory effects of lenvatinib. The immune-regulatory activity of lenvatinib is an important determinant of its antitumor effect. This activity is mediated by a reduction in TAMs and an increase in intratumoral CD8⁺ T cells. Lenvatinib also improves the therapeutic impact of ICIs by a localized reduction in TAMs. PD-L1-expressing macrophage infiltration was recently demonstrated to be a potential predictor of the response to lenvatinib in unresectable HCC. PD-L1⁺ TAMs may represent tumor immunogenicity and may be targeted by ICIs and lenvatinib.

Considerable resistance to sorafenib is afforded by TAMs with an M2 phenotype via the production of hepatocyte growth factor (HGF) and activation of HGF/c-Met, mitogen-activated protein kinase/extracellular signal-regulated kinase 1/2, and PI3K/AKT pathways in tumor cells. In turn, this exacerbates the infiltration of M2-TAMs and generates a positive feedback loop. The number of CCL2⁺ or CCL17⁺ TANs correlates with tumor development, progression, and sorafenib resistance, as mediated by TAMs and regulatory T cell recruitment by TANs in HCC. As previously mentioned, monocyte/macrophage mobilization and TAM M2 polarization depend on the CCL2/CCR2 pathway in HCC. Interestingly, blocking this pathway with a specific chemical inhibitor can potentiate the effects of sorafenib by activating the antitumor activity of CTLs. CXCR4 and its ligand CXCL12 are critical mediators between TAMs and tumor cells in various cancer types. Increased hypoxia after sorafenib treatment results in the increased accumulation of M2 TAMs and regulatory T cells, which is partly mediated by CXCR4. In a murine HCC model, anti-PD-1 immunotherapy was effective only when administered alongside CXCR4 inhibitors when intratumoral hypoxia was caused by sorafenib. The future discovery of novel therapeutic combinations of TKIs and ICIs is expected to improve patient outcomes by regulating the TAM population in HCC TME.



Dr. Hong You

Beijing Friendship Hospital, Capital Medical University

Beijing, China

The Prediction Model of HBV-HCC during Anti-viral Therapy

Chronic hepatitis B (CHB) virus infection remains the leading cause of hepatocellular carcinoma (HCC) worldwide. Although nucleos(t)ide analogues have been proved to suppress HBV replication thereby reduce HCC risk, HCC occurrence can not be completely eliminated. Here, we summarize and assess comparative performance of 14 hepatocellular carcinoma (HCC) prediction models in chronic hepatitis B (CHB) patients during anti-viral therapy.

APASL Oncology 2021 Tokyo

“Your Gateway to Oncology in Asia-Pacific Region”

Abstracts

Sponsored Seminars



President Lecture by Towa Pharmaceutical Co., Ltd.



Dr. Mitsuhiro Moriyama

Professor and Chairman,
Division of Gastroenterology and Hepatology,
Department of Internal Medicine,
Nihon University School of Medicine, Tokyo, Japan

Considering the Occurrence of Liver Cancer from Chronic Hepatitis C / Cirrhosis in Japan

The prognosis in cases with chronic hepatitis C (CHC) and liver cirrhosis (LC) is predicted to improve by the use of direct acting anti-viral agent (DAA) treatment with a dramatic increase in their sustained virological response (SVR) rate comparison of Interferon therapy. Even in our department, the SVR rate has dramatically improved by these DAA treatment. In our department, the SVR rate were increased to 98.3% among 416 patients who treated by DAA. Especially in patients who treated DAA except Dacrasvir/Asnarevir, only 3 out of 352 cases (0.9%) became Non-SVR, and SVR rate of these patients improved to 99.1%. However, HCC was developed in 8 cases (1.99%) from 402 cases in cases with SVR and 1 (14.3%) out of 7 cases with relapse (non-SVR). We consider that there will be more cases of hepatocellular carcinoma (HCC) occurring after SVR, future. Thus, in Japan, cases with hepatitis C and LC can be almost eliminated from HCV by DAA, but there is an urgent need to take measures against hepato-carcinogenesis after achievement of SVR.

Next, regarding liver cancer, from the epidemiological point of view, the number of new cases of HCC in Japan is decreasing year by year to 38,000, but it is still high. Two clinical characteristics are mentioned: it is often found in the elderly, and the frequency of NBNC is high. On the other hand, the long-term prognosis in cases with HCC showed 10 years survival rate showed around 10% due to the background of high ectopic recurrence rate, and establishing the new methods for predicting and preventing of HCC occurrence and recurrence is important.

Based on above facts, I lecture on including the epidemiology of hepatitis C virus infection in Japan, the therapeutic effect of using anti-viral drugs, and the occurrence of HCC in cases after anti-viral drugs therapy in this section. Further, introduce our efforts in the prevention and prediction of HCC occurrence until now.

Morning Seminar (1) by Chugai Pharmaceutical Co., Ltd.



Dr. Sadakatsu Ikeda

Department of Precision Cancer Medicine,
Tokyo Medical and Dental University, Japan

Toward Further Advancement of Molecular Targeted Therapy Using Liquid Biopsy in HCC

Metastatic hepatocellular carcinoma (mHCC) remains a challenging disease despite of recent advancement of treatment options, including new multi-kinase inhibitors and immune checkpoint inhibitors. Unlike other solid tumors, such as non-small cell lung cancer, molecular targeted therapies for driving mutations in hepatocellular carcinoma are not established. A part of reason is that it is common to make a diagnosis by imaging and tumor marker in HCC and tissue biopsy is not mandatory. In recent years, clinical application of liquid biopsy started. FoundationOne Liquid CDx test was approved in August 2021 by Ministry of Health, Labour, and Welfare in Japan. By using liquid biopsy, potential driver mutations in HCC were observed in 56.9% patients. Potentially actionable genes include EGFR, ERBB2, BRAF, MET, and FGFR2. However, targeted therapy for these alterations were not yet approved by HCC, and it remains challenging to deliver treatment for these with known alterations. Further efforts to develop novel therapy in HCC is strongly warranted.



Dr. Takamasa Ohki

Mitsui Memorial Hospital,

Department of Gastroenterology Deputy Director, Japan

The Usefulness of Tolvaptan as a Treatment of Hepatic Edema among Advanced HCC Patients

Backgrounds: For treatment of hepatic ascites, furosemide and spironolactone are generally used, but renal dysfunction and hyponatremia often occur. Tolvaptan (TLV), a selective oral vasopressin V2-receptor antagonist, which was approved for refractory hepatic edema and ascites (HEA) in Japan in 2013, is known to be effective without causing such adverse events, but its efficacy for HEA in patients with advanced hepatocellular carcinoma (HCC) has not been well defined. In this seminar we focused on this theme.

Patients and Methods: We enrolled 85 advanced HCC patients with HEA using TLV between October 1st 2012 and September 31 2021. Patients were administered TLV 3.75-15.0 mg once daily. We defined the improvement of HEA as weight loss for more than 1.5 kg based on the Japanese guideline of HEA. We divided the patients into two groups according to the improvement of HEA and compared the patients' backgrounds and OS between the two groups. We also analyzed the factors which contributed to the improvement of HEA and OS using multivariate analysis.

Results: Of the 85 patients, 43 patients (50.6%) were responder. The proportion of Child-Pugh class C patients was significantly higher in non-responder group (32.6% vs. 66.7%, $P < 0.01$). The median of maximum tumor size was significantly larger in non-responder group (60 mm vs. 70 mm, $P < 0.047$). Logistic regression multivariate analysis showed that first 24 hours urine volume after administration of TLV (OR: 1.12 per 100 mL, 95%CI; 1.02-1.18, $P < 0.01$), as an independent factor related to the improvement of HEA. Sixty-six patients (77.65) died during the median survival time of 55 days, showing cumulative survival rates at 30, 60 and 180 days of 81.0%, 49.8%, 21.1% in the responder group, 52.8%, 26.3% and 3.8% in the non-responder group, respectively ($P < 0.01$). Cox proportional hazard multivariate analysis showed that tumor numbers over 10 (HR: 1.91, 95%CI; 1.08-3.38, $P = 0.017$), ALT level (HR: 1.06 per 10 IU/l, 95%CI; 1.01-1.11, $P = 0.039$), and blood urea nitrogen level (HR: 1.04 per 1.0 mg/dl, 95%CI; 1.02-1.06, $P < 0.01$), as independent factors related to OS. Unfortunately, improvement of HEA with TLV (HR: 0.59, 95%CI; 0.34-1.03, $P = 0.06$) did not retain statistically significance.

Conclusions: TLV was useful for HEA with advanced HCC. In this program, I will show the whole data of TLV with some case reports.



Dr. Tatsuo Kanda

Division of Gastroenterology and Hepatology,
Department of Medicine, Nihon University School of Medicine,
Itabashi, Tokyo, Japan

Clinical Symptoms of Liver Diseases: Pathogenesis and Treatment

In general, unless hepatic spare ability is in decline, symptoms do not appear even in patients with hepatic cirrhosis or hepatic carcinoma. In some patients with hepatic cirrhosis, general fatigue, pruritus and leg cramps are occasionally observed. In our study, pruritus (with ≥ 0 visual analog scale) was observed in 129(25%) of 525 patients (mean age 62.2 years; male/female: 247/278) with chronic liver diseases, including hepatic cirrhosis. Pruritus was observed in whole body, back, legs, etc. Although 82 (63.6%) of 129 these patients had already taken medicine and/or used ointment for their pruritus, pruritus did not improve in 11 (13.4%) of 82 patients. Diabetes mellitus did not have a significant impact on the occurrence of pruritus. Patients with anti-HCV positive or autoimmune liver diseases had significantly higher VAS than those with others. Patients with primary biliary cholangitis had significantly higher VAS than those with autoimmune hepatitis. Several patients had leg cramps. In patients with liver diseases, both pruritus derived from the central nervous system and that derived from peripheral organs exists and we should treat both pruritus. As part of this, treatment for leg cramps may be required.



Dr. Norio Akuta

Hepatology, Toranomon Hospital, Japan

New Findings and Future Prospects, Based on Japanese Patients of Histological Proven NAFLD in Toranomon Hospital

The top three causes of death are cardiovascular diseases (CVDs), malignancies, and liver-related events in patients with non-alcoholic fatty liver disease (NAFLD). Furthermore, severe liver fibrosis stage and presence of type 2 diabetes mellitus (T2DM) are the important predictive factors for liver cancer, as one of liver-related events. Previous reports based on large-scale clinical trials indicated that SGLT2 inhibitor (SGLT2i) could reduce the risk of CVDs in patients with T2DM. On the other hand, long-term impact of SGLT2i for NAFLD were still unclear. In Toranomon Hospital, 500 Japanese patients of histological proven NAFLD were investigated. The rate of liver-related events per 1,000 person years was 8.15 (liver cancer, 3.27). The rates of CVDs and malignancies except for liver cancer were 12.70 and 9.89, respectively. Liver cancer was the most common liver-related event, and CVDs indicated the highest incidence in Japan. Multivariate analysis identified the FIB-4 index ≥ 2.67 as a significant and independent noninvasive predictor of three complications. Furthermore, liquid biopsy with serum cell-free DNA is expected as one useful tool to assess potential biomarkers of liver cancer and prediction of prognosis. We reported that serum microRNA-122 levels were useful as one predictive factor of mortality in NAFLD, and serum TERT mutation (TERT C228T) with wild-type blocking PCR as one predictive factor of the early diagnosis of NAFLD-related liver cancer. 7 patients with NAFLD complicated by T2DM were treated with SGLT2i, and serial liver biopsies were prospectively evaluated at the start of treatment, 24 weeks, and 3 years. The primary outcome was liver histological changes (defined as decrease in NAS of one point or more without worsening in fibrosis stage, compared to the pretreatment). All 7 patients showed worsening of body mass index and waist circumference at 3 years compared to 24 weeks, despite the improvement of them at 24 weeks compared to the pretreatment. On the other hand, the rates of histological improvement at 24 weeks and 3 years were 100% and 86% compared to the pretreatment, respectively. Especially, the fibrosis stage scores, as the important predictive factor of liver cancer, improved at 24 weeks and 3 years in 29% and 29%, respectively. Thus, it is expected that SGLT2i might suppress not only CVDs but also liver-related events. Further study should be performed to manage the top three causes of death effectively in patients with NAFLD, and develop the novel treatment to suppress them.



Dr. Kazunari Murakami

Department of Gastroenterology,
Oita University, Faculty of Medicine, Japan

Gastric Cancer Risk with *H. pylori* Infection and Gastric Cancer Management in Japan

Over the past few years, the profile of *Helicobacter pylori* infection has changed in Japan. In particular, the relationship between *H. pylori* and gastric cancer has been demonstrated more clearly. In 2016, the committee of the Japanese Society for *Helicobacter* Research has revised the guidelines for diagnosis and treatment of *H. pylori* infection in Japan. In 2013, Treatments for *H. pylori*-associated gastritis was covered by health insurance. In fact, all *H. pylori*-infected patients in Japan can receive these insurance-covered combination therapies for the eradication. Before diagnosing and treating *H. pylori* infection, an endoscopic examination is required to obtain a definitive diagnosis of *H. pylori* gastritis. In 2014, first version of Kyoto classification of gastritis was published, and in 2018, it was revised. Successful eradication of *H. pylori* improves histological gastritis and may prevent various diseases associated with *H. pylori* infection, such as gastric cancer. It is necessary to evaluate the risk of gastric cancer by endoscopic findings, and also necessary to make a long follow-up after the eradication. Especially for atrophic gastritis, intestinal metaplasia, enlarged fold, and nodular gastritis, which are considered as being in a high-risk group of gastric cancer, and endoscopic diagnosis of them is undeniably required. Improvements of them after the eradication may be regarded as one reason for prevention of gastric cancer. We also attempt to score for these findings according to the grades of the lesions. On the other hand, Latest development of endoscopy system including image enhanced function and magnified function can make possible the fine diagnosis of gastric cancer in Japan. I would like to several guidelines in Japan about ESD technique, indications, and outcomes.



Dr. Akihito Nagahara

Department of Gastroenterology,
Juntendo University School of Medicine, Japan

Treatment Strategies for Acid Related Disease in Primary Care-Based on Clinical Practice Guidelines for GERD 2021

H.pylori infection induce atrophic gastritis and it has the protective effect on GERD. Therefore, the GERD prevalence is known to be inversely correlated with *H.pylori* infection rate. However, prevalence of GERD increased dramatically regardless presence of *H.pylori* infection in Asia. This might be caused by change of lifestyle and advent of an aging society. According to a questionnaire survey which we conducted revealed that the frequencies of erosive GERD, non-ERD (NERD), uninvestigated GERD, and Barrett's esophagus varied significantly among Asian countries. The most important factor in diagnosing GERD was the presence of symptoms in all countries. A proton pump inhibitor (PPI) was the most commonly prescribed drug to treat GERD in all countries (Digestion. 2020;101:66-79.). In this way, there is no doubt that symptom improvement as well as mucosal healing is important in clinical practice. This year, the Japanese Society of Gastroenterology revised the clinical practice guidelines for GERD. It will be revised regularly every few years based on the "sunset rules". In the last few years, potassium-competitive acid blocker (P-CAB) has been launched in Asia, and the revised version includes this drug. This guideline committee performed meta-analysis of clinical trials in Japan and Asia with P-CAB and PPI for GERD treatment. As a result, it is shown that there is no difference between PPI and P-CAB in the therapeutic effect in mild esophagitis which often seen in daily practice. It is well known that maintenance treatment is necessary for the treatment of GERD. As a maintenance therapy, PPI is described as a recommended drug, and P-CAB is a proposal drug. The reason is that although efficacy of P-CAB is expected to be equal or better than PPI, the amount of evidence of P-CAB regarding safety for long-term is still insufficient. PPI has established the firm position in clinical practice during decades. Although several years behind other countries, Nexium was finally approved for pediatric indications in Japan a few years ago. This situation simplifies the management of acid-related disease. For instance, PPI is useful to pediatric GERD, *H.pylori* eradication, middle-aged GERD with obesity, elder-aged GERD with hiatal hernia and kyphosis, and prevention of low-dose aspirin ulcer. The safety of PPI has been verified, and it can be prescribed for acid-related diseases from children to elderly. In other words, Nexium is thought to be useful in several acid-related life events from children to elderly.



Dr. Masafumi Ikeda

Chief, Department of Hepatobiliary and Pancreatic Oncology,
National Cancer Center Hospital East, Japan

Novel Cancer Immunotherapy for Hepatocellular Carcinoma: Evidence and Management

Systemic therapy is one of the most important treatment modalities for advanced hepatocellular carcinoma (HCC), and, in recent years, it has made rapid progress. Sorafenib has been acknowledged worldwide as the standard therapeutic agent for advanced HCC by two pivotal phase III placebo-controlled studies in 2008. Following the introduction of sorafenib for the treatment of HCC, phase III trials of numerous other agents have been conducted as first-line or second-line treatment. Until now, lenvatinib and atezolizumab plus bevacizumab (Atezo+Bev) demonstrated positive results in first-line treatment, and regorafenib, ramucirumab (patients only with 400 ng/ml or over of α -fetoprotein), and cabozantinib in second-line treatment. At present, all six regimens are available in clinical practice for HCC.

Among them, Atezo+Bev, which is one of cancer immunotherapies, has been reported to be clinically meaningful improvement in overall survival in patients with advanced HCC, and has changed our clinical practice. In a global phase III trial comparing Atezo+Bev with sorafenib (IMbrave150), Atezo+Bev combination demonstrated the superiority to sorafenib in both OS [hazard ratio: 0.58 (95%CI, 0.42-0.79), $p=0.0006$, (stratified log-rank test)] and PFS as assessed by the independent review facility based on RECIST v1.1 [hazard ratio: 0.59 (95%CI, 0.47-0.76), $p<0.0001$, (stratified log-rank test)]. The common adverse reactions reported in the Atezo+Bev group were hypertension (23.7%), proteinuria (18.8%), and fatigue (15.2%), but it was well-tolerated. Based on the results, Atezo+Bev was reimbursed for unresectable HCC in September 2020 in Japan. From this result, cancer immunotherapy has attracted attention, and the development of various combination regimens. Overall, the advances in cancer immunotherapy for HCC have brought change to the treatment landscape. In addition to the results of various trials of Atezo+Bev, including those of GO30140 and IMbrave150, a number of prescribing experiences in the clinical practice have been reported. In this seminar, I will present the results of clinical trials and clinical experience of Atezo+Bev and future perspective of cancer immunotherapy.



Dr. Ann-Lii Cheng

NTU Chair Professor, National Taiwan University

President Emeritus, NTU Cancer Center, Taiwan

Exploring Next-Gen Systemic Therapy for HCC: What Have We Learned?

The success of the combination of atezolizumab and bevacizumab (atezo-bev) has revolutionized the treatment for advanced HCC. Although the mechanism that leads to its better efficacy remains obscure, it is postulated that VEGF/VEGFR signal blockade may result in improved T-cell trafficking, promotion of immunosupportive, and suppression of immunosuppressive microenvironments. Along this line, it is hypothesized that multi-target tyrosine kinase inhibitors (TKI), with additional immunoregulatory mechanisms by several “off targets”, may provide an even better efficacy. However, to date we realize that a detailed understanding of the various “off targets” in regulating host immunity is mandatory before this can work.

Preliminary results of double CPIs, such as anti-PD1 plus anti-CTLA4, have demonstrated a promising activity. However, in these combinations a higher anti-CTLA4 dosage appears to be necessary, and high dose anti-CTLA4 is inevitably associated with a greater irAE which should be dealt with. Use of other CPIs with less add-on toxicity, such as anti-TIGIT or anti-LAG3, may be reasonable alternatives.

Triplet therapy, such as double CPI plus anti-VEGF mAb or TKI, has recently been explored. Preliminary results suggested an improved efficacy over the doublets. We are truly in a new era in which pursuing highly efficacious systemic therapy for HCC is possible.



Dr. Tung-Hung Su

Department of Internal Medicine

Taiwan, Republic of China

M2BPGi for Liver Fibrosis and Outcome Prediction

Liver inflammation and fibrosis are two key host factors leading to disease progression in chronic hepatitis. Non-invasive tests of liver fibrosis are emerging, and acceptable by the patients, including fibroscan, shear-wave elastography, and blood-based biomarkers, such as Fib-4 index, and Mac-2-binding protein glycosylation isomer (M2BPGi).

The Mac-2 binding protein (M2BP) is a secreted glycoprotein (~90kDa) with 7 N-glycans per monomer, which is polymerized in serum to form a sweet doughnut-like structure. The N-glycosylation of M2BP alters during the progression of liver fibrosis. These altered form of M2BP becomes the M2BPGi, which was secreted by hepatic stellate cells (HSCs) in the liver. M2BPGi may be detected specifically by the *Wisteria floribunda* agglutinin (WFA) lectin probe, and become a simple blood test for clinical usage.

M2BPGi has been introduced to correlate with liver fibrosis, and risk of HCC in patients with chronic hepatitis C, to predict liver reserve and outcome of cirrhosis, and liver failure after hepatectomy. In patients with chronic hepatitis B, M2BPGi levels can also help to estimate liver fibrosis, and are associated with an increased risk of HCC. A higher M2BPGi level before treatment or after sustained viral suppression can predict HCC development in patients of chronic hepatitis B receiving nucleos(t)ide analogue therapy. Moreover, M2BPGi is associated with mortality in chronic hepatitis B related cirrhosis. In patient with non-alcoholic fatty liver disease, M2BPGi also correlates with liver fibrosis, and may predict the development of HCC afterwards.

Overall, M2BPGi is an emerging and useful marker for liver fibrosis prediction in various etiologies of liver diseases. Moreover, M2BPGi can be used as a monitoring or a predictive marker for the management of liver disease.



Dr. Yoshiyuki Wada

Chief Surgeon, Department of Hepato-Biliary-Pancreatic Surgery,
National Hospital Organization Kyushu Medical Center, Japan

LEN-TACE Sequential Therapy as a Therapeutic Strategy for Intermediate-stage Hepatocellular Carcinoma

Systemic chemotherapy for hepatocellular carcinoma (HCC) has improved in recent years. At present, six treatment options including combinations of immune-checkpoint inhibitors and antiangiogenic agents are available. With the development of new drugs, overall survival has improved. Sequential therapy using these chemotherapeutic agents has spread worldwide, and many guidelines recommend sequential therapy for incurable HCC. The development of systemic chemotherapy has led to changes in the strategies of HCC treatment. Specifically, treatment strategies for intermediate-stage HCC- Barcelona Clinical Liver Cancer (BCLC) stage B (BCLC-B HCC) have notably changed. Transarterial chemoembolization (TACE) was considered as the only established treatment for BCLC-B HCC at present. However, not only TACE refractoriness but also TACE unsuitability was proposed, and these concepts extend the role of systemic chemotherapy in intermediate-staged HCC. Thus, TACE indications have been reconsidered, i.e., TACE was recommended in patients with intermediate-staged HCC with TACE refractoriness or TACE unsuitability, which is expected in radical treatment with TACE. Systemic chemotherapy has been positively administered for HCC cases, which is unexpected in radical treatment with TACE.

Under these conditions, lenvatinib attracted substantial attention, as it resulted in high objective response for intermediate-staged HCC. Several studies have reported that lenvatinib may improve long-term outcomes compared with TACE for intermediate-stage HCC beyond up-to-seven criteria. Thus, lenvatinib treatment is preferred for these HCC cases in real-world clinical practice. The introduction of systemic chemotherapy treatment with high objective response has improved the treatment strategy for intermediate-stage HCC to bipolarization. The aim of positive treatment is radical cure, and that of palliative treatment is the prolongation of survival. LEN-TACE sequential therapy, which is a combination therapy of lenvatinib with high objective response and TACE with high radical power, is proposed as a positive treatment aimed at radical treatment and expected as a new promising attempt for intermediate-stage HCC beyond up-to-seven criteria. Moreover, conversion therapy, i.e., using chemotherapeutic treatment with high objective response such as lenvatinib, from chemotherapy to curative treatment has attracted attention. This presentation provides a trend of treatment for intermediate-stage HCC and introduces a new hopeful treatment strategy of LEN-TACE sequential therapy.




Dr. Tatsuya Yamashita

Advanced preventive medical sciences research center,
Kanazawa University, Japan

Positioning of Hepatic Arterial Infusion Chemotherapy and Lenvatinib for Advanced Hepatocellular Carcinoma

The 2021 edition of the Japanese Liver Cancer Practice Guideline weakly recommends hepatic arterial infusion chemotherapy (HAIC) for advanced hepatocellular carcinoma (HCC) with multiple intrahepatic or vascular invasions. The recommendations are based on evidence from two randomized controlled trials and several studies using propensity score matching. In a multicenter collaborating study in Japan, it has been reported that 5-FU+CDDP (FP) HAIC significantly improved overall survival (OS) compared with sorafenib in cases with vascular invasions and no extrahepatic lesions. Regarding HAIC, in ASCO 2021, FOLFOX HAIC is effective for advanced HCC and neoadjuvant chemotherapy before hepatic resection. In our study, 5-FU-based HAIC had a response rate of 29.6%, overall survival was about 30 months in responded patients, and more prolonged survival was obtained in patients who received conversion treatment. Under these circumstances, in ESMO 2021, the promising result of lenvatinib +CDDP HAIC (LEOPARD study) was reported. Lenvatinib +CDDP HAIC showed a very high response rate of 45.7% (RECIST v1.1). While cancer immunotherapy is emerging as systemic therapy for advanced HCC, lenvatinib + CDDP HAIC may also be an optional treatment for HCC patients with advanced intrahepatic lesions or rapid progressive intrahepatic lesions.



Dr. Yasuteru Kondo

Department of Hepatology,
Sendai Kousei Hospital, Japan

Ultra-FP Treatment could be Affordable Treatment Option for Advanced Stage of HCC

Recently, the choices of treatments for hepatocellular carcinoma (HCC) were increasing since the several molecular targeting agents (MTA) and iCIs were approved for treatment of advanced HCC patients. However, alternative treatment modalities are required because of the low response rates and unsuitability of MTA and iCIs in real world. On the other hand, the transarterial chemoembolization (TACE) and hepatic artery infusion chemotherapy (HAIC) have been improved by various kinds of methods. The liver resection, radiofrequency ablation (RFA) and microwave coagulation (MWA) might achieve complete cure. However, the treatment indication of liver resection, RFA and MWA should be limited. Therefore, multidisciplinary treatment including HAIC, TACE, MTA, RFA, MWA, and liver resection should be considered to control HCC. In this lecture, I will present about the role of Ultra-FP therapy (combination weak embolization with DEB-TACE (CDDP) and HAIC (low dose FP: CDDP and 5-FU)) for the HCC patients.



Dr. Ryosuke Tateishi

Department of Gastroenterology,
The University of Tokyo Hospital, Japan

Antiviral Therapy for Hepatocellular Carcinoma: Primary and Tertiary Prevention

Globally, the most significant cause of hepatocellular carcinoma (HCC) is chronic hepatitis B (CHB), followed by chronic hepatitis C (CHC). Therefore, controlling these two hepatitis viruses is considered the most effective way to reduce the incidence of HCC. Lamivudine for cirrhosis with hepatitis B showed reduced HCC risk in a randomized controlled trial (RCT). Since then, there have been a lot of reports supporting the preventive effect of nucleos(t)ide analog against HCC. Interferon (IFN) therapy has been proved to reduce the HCC risk in CHC. However, IFN-based therapy was not feasible for patients with a higher risk of HCC, including patients with advanced cirrhosis, the elderly, and those with impaired renal function because of frequent adverse effects. With recently emerging direct-acting antivirals (DAAs), a nearly 100% of sustained virological response (SVR) is now achievable regardless of patient age, liver fibrosis grade, and renal function. Although RCTs are not feasible from an ethical point of view, some large-scale studies indicated a preventive effect of DAAs similar to IFN-based therapy on HCC incidence. Now that SVR is achievable in almost all patients, the most crucial topic for chronic hepatitis C is how to follow patients with SVR. Unfortunately, the HCC incidence is not negligible for patients with advanced disease, especially the elderly patients who have substantial risk. We also have reported that lifestyle-related factors, obesity, and heavy alcohol intake, increase the risk of HCC after SVR. Anti-viral therapy for chronic viral hepatitis is also an effective strategy for patients who have already developed HCC. Nucleos(t)ide analogs are reported to improve the survival of HCC patients after curative hepatectomy. To be noted, the effect of antiviral therapy for hepatitis B was more prominent on overall survival than recurrence-free survival. Recurrence of HCC after radical therapy consists of de novo hepatocarcinogenesis and intrahepatic metastasis, which is unlikely to be suppressed by anti-viral therapy. On the other hand, liver function reserve can be improved by nucleos(t)ide analog use. In fact, we have reported a drastically improved overall survival of HCC with CHB after radiofrequency ablation over time, probably due to the increased use of nucleos(t)ide analogs. In contrast to anti-HBV therapy after radical treatment, patients with CHC needed to wait 15 years to see the emergence of DAA. There has been a concern about an accelerated recurrence after DAA therapy in HCC patients. Recent reports support that anti-HCV therapy is at least not harmful to HCC patients. On the other hand, improved liver function is also observed in CHC patients like CHB patients. We have reported the recently improved prognosis of HCC with CHC.



Dr. Sachiyo Yoshio

Department of Liver Diseases,
Research Center for Hepatitis and Immunology,
National Center for Global Health and Medicine, Japan

Current Status of HBV Prevalence and Efforts for Eradicating Hepatic Failure by HBV Reactivation in Patients with Cancer

Immune checkpoint inhibitors (ICIs) and molecular-targeted drugs, such as tyrosine-kinase inhibitors (TKIs) have taken cancer treatment into a new era. People with cancer who receive treatments with immunomodulative effects are at risk for hepatitis B virus (HBV) reactivation. This seminar will review the pathogenesis, diagnosis, management and prevention of HBV reactivation. The real-world occurrence rates and management of HBV reactivation in cancer patients will be shown. I would like to show efforts in the management of HBV reactivation in cancer institute hospital. Collaborations with hepatologists, cancer specialists not specializing in hepatology, pharmacists, nurses, laboratory technicians and systems administrators, and also patient education are needed to effectively prevent HBV reactivation. Let's go for zero morbidity and mortality related to HBV reactivation in patients with cancer through acquiring knowledge and awareness of HBV reactivation.

The clinical outcome of HBV infection is determined through the interplay between viral replication and the host's immune responses, involving HBV-specific T cells and B-cell mediated humoral immunity. HBV carrier is the status with positive hepatitis B surface antigen (HBsAg). Resolution of HBV infection is the status with serological clearance of hepatitis B surface antigen (HBsAg) with or without anti-HBs antibody. HBV persists in the liver of all patients with past HBV infection, even after attaining serological resolution. Immunosuppressive therapy in cancer patients down-regulates anti-HBV immune responses, which allows HBV replication to increase. HBV itself is a non-cytotoxic virus, which causes no liver damage. Liver injury is provoked by immune responses to the enhanced hepatic expression of HBV antigen. Liver injury interrupts cancer treatment and can lead to fulminant hepatic failure and death. Pre-emptive use of nucleos(t)ide analogues (NAs) can prevent HBV reactivation. Entecavir (ETV) and tenofovir (TDF)/tenofovir alafenamide (TAF) are high resistant barriers NAs and can be used for a long time. Screening of HBV markers, HBsAg, anti-HBs and anti-HBc antibody, should be conducted in all patients with cancer. The regular testing of HBV DNA should be performed during and at least 12 months after immunosuppressive therapy. These screening and monitoring enables appropriate intervention of NAs and prevent HBV reactivation. The patients with B-cell depleting therapy and allogenic hematopoietic stem cell transplantation might be better to be monitored more than 12 months after treatment.




Dr. Kaoru Tsuchiya

Department of Gastroenterology and Hepatology,
Musashino Red Cross Hospital, Japan

Recent Advances in Systemic Therapy for Hepatocellular Carcinoma and Management of Hepatitis B Infection

Primary liver cancer is the sixth most commonly diagnosed cancer and the third leading cause of cancer death worldwide in 2020. Approximately 75-85% of primary liver cancer is hepatocellular carcinoma (HCC). In the last 3 years, the landscape of systemic therapy for HCC has been dynamically changed. The combination of an anti-programmed death-ligand 1 and an anti-vascular endothelial growth factor (atezolizumab + bevacizumab) is recommended as first-line, and 4 oral multi-tyrosine kinase inhibitors (sorafenib, regorafenib, lenvatinib, cabozantinib), 1 anti-angiogenic antibody (ramucirumab), and other immune checkpoint inhibitors (ipilimumab in combination with nivolumab, nivolumab, and pembrolizumab in monotherapy) have been approved. The wider availability of systemic therapies increases the possibility for longer overall survival with sequential therapy or locally cure with conversion therapy. On the other hand, there is no established data on sequences after atezolizumab + bevacizumab, and therefore this lack of supporting evidence makes it difficult to provide strong recommendations for second and later-line treatment.

Hepatitis B virus (HBV) infection is still a major cause of HCC, especially in Asian countries except for Japan. Even in Japan, the number of HBV-HCC is not decreased, while hepatitis C virus (HCV)-related HCC has been rapidly decreasing. Primary prevention involves the avoidance of viral infection through hepatitis B vaccination, and the universal neonatal hepatitis B vaccination program has successfully reduced the prevalence of HBV carriage. However, HBV elimination is still difficult to achieve. Regarding secondary prevention, long-term treatment with nucleoside analogs (NAs) has been proven to reduce the risk of HBV-related HCC. Some studies have already revealed the differences in risk of HCC according to the difference of NAs. Tertiary prevention has also been reported by life-long treatment with NAs to reduce the risk of HCC recurrence after curative treatment of primary HCC. In my presentation, I would like to show the recent advances in systemic therapy for unresectable HCC, including our real-world experience and management of HBV infection, especially focused on second and tertiary prevention of HCC.



Dr. Naoya Kato

Professor and Chair at Department of Gastroenterology,
Graduate School of Medicine,
Chiba University, Japan

New Personalized Approach for Intrahepatic Cholangiocarcinoma Based on Cancer Genomic Diagnosis in Japan

In the 23rd National Primary Liver Cancer Survey, intrahepatic cholangiocarcinoma (iCCA) accounted for 6.4% of primary liver cancers, and the proportion of iCCA is increasing year by year. The Liver Cancer Study Group-Japan published 2021 guidelines for the management of iCCA. For the treatment algorithm, resection, drug therapy, and palliative therapy are recommended based on the 4 factors of hepatic reserve, distant metastasis, regional lymph node metastasis, and multiple lesions. The combination of gemcitabine (G) + cisplatin (C) + S1 (S), GC, and GS is recommended as drug therapy for unresectable iCCA. Recently, it has been reported that FGFR2 fusion gene and IDH 1/2 mutations are specifically expressed in iCCA, and the frequency of FGFR2 gene abnormalities is 5.3% to 13.6% in Japan. Pemigatinib, a molecular-targeted drug that inhibits FGFR2, became available from June 2021 in Japan. FGFR2 fusion gene/rearrangement causes FGFR kinase activation without binding of FGF ligands to FGFRs. The FGFR kinase activates downstream signaling pathways leading to proliferation, migration, and angiogenesis. In the global phase II study FIGHT-202, a clinical study of pemigatinib 13.5 mg orally once daily for 14 days followed by 7 days off was conducted in 107 patients with unresectable cholangiocarcinoma with FGFR2 fusion gene/rearrangement. The ORR was 35.5% in 38 of 107 patients. PFS was 6.93 months, and OS was 21.06 months. The maximum rate of change in the sum of diameters of target lesions showed that the target lesions decreased in 91 of 103 patients. Accompanying symptoms, on the other hand, were observed in 94.4% of 107 patients, and the main adverse reactions were alopecia, hyperphosphatemia, dysgeusia, nail disorder, diarrhea, stomatitis, dry mouth, and fatigue. Serious adverse reactions include anemia, abdominal pain, dysphagia, acute kidney injury, thrombosis, retinal detachment, and hyperphosphatemia. At present, cancer genome diagnosis includes companion test and panel test. The latter includes patients with solid tumors for which no standard therapy is currently available or patients with solid tumors for which standard therapy has been completed because of local progression or metastasis, and for whom the attending physician considers that chemotherapy is likely to be indicated after this test based on general conditions and organ function, etc. in accordance with the guidelines of relevant academic societies. It is important to determine the timing of conducting a cancer genome profile test, bearing in mind that the test will be conducted by the cancer genome medical core hospital.



Dr. Arndt Vogel

Managing senior consultant in the Department of Gastroenterology, Hepatology and Endocrinology at Hannover Medical School
Head of the Visceral Oncology Cancer Center Hannover, Germany

Pemigatinib in Cholangiocarcinoma: Targeting FGFR2 Fusions

Intrahepatic Cholangiocarcinoma (ICC) is a highly aggressive malignancy with a median overall survival (mOS) below one year under palliative systemic therapy with gemcitabine and cisplatin. Although the molecular landscape of ICC is heterogeneous, a recurrent repertoire of driver genes exists: several studies suggest that approximately 40% of patients harbor targetable lesions. One of the most frequent alterations that occurs in up to 15% of ICC cases are genetic rearrangements that involve the transmembrane receptor tyrosine kinase fibroblast growth factor receptor 2 (FGFR2). The therapeutic promise of FGFR2 fusions has led to the clinical development of FGFR inhibitors, which have successfully completed phase II clinical trials and are currently further developed in phase III studies for FGFR2 fusion-positive ICC. Overall response rates to FGFR-targeted agents range between 20-35% in the second or higher lines of therapy and exceed the efficacy of conventional chemotherapy. On the basis of the Fight-202 phase 2 trial, the FGFR inhibitor pemigatinib was granted approval by the FDA and EMA for the treatment of previously treated cholangiocarcinoma. In my presentation I will provide an overview on efficacy and safety data of the pivotal FIGHT-202 study, additionally I will cover several post-hoc analysis of the trial, which have broadened our understanding FGFR2 fusion positive BTC.



Dr. Nobuhiro Nakamoto

Division of Gastroenterology and Hepatology, Department of Internal Medicine, Keio University School of Medicine, Japan

Role of Gut Microbiota in Liver Disease and Carcinogenesis

The liver has direct communication with the intestinal tract via the portal vein, and is constantly exposed to intestinal bacteria and the metabolites derived from the digestive tract. Therefore, liver serves as the first barrier against these foreign antigens. Since an excessive immune response to the pathogens causes autoimmune diseases, it is suggested that qualitative and quantitative changes in intestinal bacteria may contribute to the pathophysiology of liver diseases via the gut-liver axis. Indeed, recent progress in the analysis of intestinal microflora of patients revealed the specific gut microbiota associated with various liver diseases such as steatohepatitis, alcoholic hepatitis, autoimmune liver diseases, and hepatocellular carcinoma. Furthermore, recent reports demonstrated the possible contribution of gut microbiota to the antitumor effect of immune checkpoint inhibitors. On the other hand, it is difficult to prove the direct contribution of these bacteria to the disease onset or progression by the current metagenomic methods. Regarding this point, Humanized microbiota-associated (HMA) mice, defined as germ-free mice transplanted with fecal samples from diseased individuals or a single bacterial strain isolated from the patient, is a strong tool to clarify the direct association between the microbiota and immune responses especially in extra-intestinal organs. In this education seminar, I will show the recent progress in our research targeting disease-specific gut microbiota in primary sclerosing cholangitis, an intractable hepatobiliary disease. In addition, we will summarize the latest findings regarding the contribution of intestinal bacteria to the pathogenesis of chronic liver diseases and the related carcinogenesis.



Dr. Yoshinari Asaoka

Department of Medicine,
Teikyo University School of Medicine, Japan

SVR & HCV-related HCC

The remarkable development of Direct Acting Antivirals (DAA) had made it possible to achieve SVR in most of hepatitis C cases, and many cases are clinically benefiting from it. However, the ultimate goals of hepatitis C treatment are to improve the prognosis of hepatitis C patients, and the management of post-SVR hepatocellular carcinoma (HCC) is important for this purpose. In clinical practice, de novo carcinogenesis in SVR cases is often experienced. The risk factors are suggested to include liver fibrosis, advanced age, male sex, obesity, and alcohol consumption. The optimal surveillance for de novo carcinogenesis in SVR cases needs further investigation. On the other hand, the impact of DAA on recurrence in previously treated HCC patients is still controversial. IFN has proved to have an anti-tumor effect, but DAA does not have the effect on its own, so it was suggested that once the virus is eradicated, intra-hepatic surveillance by immune cells for cancer is reduced, which may increase recurrence. However, with the accumulation of many clinical data, it has been found that DAA does not significantly increase recurrence compared to IFN. It is thought that viral eradication by DAA may be desirable even in the cases after HCC treatment, since improved liver reserve facilitates subsequent treatment for recurrent tumors. The last few years have seen rapid progress in the drug therapy for advanced HCC, replacing the advances in DAA. Among them, immune checkpoint inhibitor is now being used for advanced HCC. It has been suggested that the etiology of HCC is involved in its therapeutic effect. The above clinical findings suggest that the immune status may differ depending on the etiology, and we will also discuss it from the aspect of molecular characteristics of HCV-related HCC.



Dr. Hironao Okubo

Department of Gastroenterology,
Juntendo University Nerima Hospital, Japan

HCV Eradication in the SDGs Era

Hepatitis C virus (HCV) infection is a major cause of severe liver disease including chronic hepatitis, cirrhosis and hepatocellular carcinoma. The HCV burden in public health is estimated at about 71 million people worldwide by World Health Organization (WHO) with at least 400,000 people that died every year from HCV disease. Various direct antiviral agent (DAA) regimens are rapidly evolving for patients with chronic hepatitis C viral (HCV) infection, and serological viral response has progressed. HCV eradication for all at ages have been take into consideration in the Sustainable Development Goals (SDGs) era. In order to promote HCV elimination for all at ages, there are two main components. One is screening system for detecting patients with HCV-Ab positive. Second is safety in the anti-HCV therapy. In this lecture, we will show the approach for detecting HCV patients in our institution and review the safe usage of DAAs from the pharmacological perspective.

APASL Oncology 2021 Tokyo

“Your Gateway to Oncology in Asia-Pacific Region”

Abstracts

Oral Free Papers



Surgical Treatment for Multinodular HCC with Right Hepatic Vein Tumor Thrombosis: A Case Report

¹Vietnam National Cancer Hospital

Giang Nguyen¹, Trong Nguyen¹, Hung Nguyen¹, Anh Pham¹

Background: Ventral segment saving right hepatectomy is proved to be an alternative choice for conditional right hepatectomy. Anterior approach with liver hanging technique is useful to prevent the dissemination of tumor cells to systemic circulation. Thus, we aim to combine these two useful techniques together.

Methods: Patient male 65 years old with 2 tumors in the right posterior section with thrombosis closed to the root of right hepatic vein. The left liver was small, RFV/BMW is only 0.41%. If we can preserve the ventral segment, the RFV/BMW would be 0.57%. So, we performed the ventral segment saving right hepatectomy with anterior approach using liver hanging maneuver.

Results: The operation's time was 270 mins, with estimated blood loss was 300ml. We got the complication of post hepatectomy liver failure grade B (ISGLS). The patient was discharged at POD 27.

Conclusions: The anterior approach using liver hanging technique can be combine with ventral saving right hepatectomy as a treatment for HCC with right hepatic vein tumor thrombosis.

A Case with HCC Successfully Treated with Prednisone for Atezolizumab-associated Grade 3 Colitis

¹Division of Gastroenterology, Department of Medicine, Showa University School of Medicine, Tokyo, Japan

Takahiro Fuji¹, Jun Arai¹, Yumi Otoyama¹, Ikuya Sugiura¹, Yoko Nakajima¹, Atsushi Kajiwara¹, Yuki Ichikawa¹, Shojiro Uozumi¹, Yuu Shimozuma¹, Manabu Uchikoshi¹, Masashi Sakaki¹, Hitoshi Yoshida¹

Background: Systemic chemotherapy has shown a significant survival benefit in patients with hepatocellular carcinoma (HCC). However, there are various immune-related adverse events (irAEs). We herein report a case with grade 3 colitis and successfully treated with prednisone.

Case presentation in 2018, asymptomatic 89-year-old man with hypertension was accidentally detected a 140mm hypervascular intrahepatic nodule with contrast-enhanced computed tomography (CECT). Washout of contrast medium was also detected and PIVKA-II was elevated. Since the ALBI grade was 2a without any distant metastasis, TACE was effectively performed to HCC. One year later, several intrahepatic nodules were seen in the bilateral lobes (BCLC intermediate stage, up-to seven criteria out). Therefore, the patient was treated with Lenvatinib for 1 year and 4 months. The complete response with mRECIST was achieved in two months, but finally multiple hypervascular nodules were seen again in the bilateral lobes. As the ALBI grade was 1, 2nd chemotherapy with atezolizumab and bevacizumab started. Although the complete response was achieved, the therapy was halted due to grade 3 colitis occurred after 6th course. In the analysis with stool culture, CECT, and colonoscopy, the diagnosis was the atezolizumab-associated colitis. The diarrhea was recovered after the oral administration of 0.5mg/kg/day prednisone and successfully restarted atezolizumab and bevacizumab without recurrence of colitis.

Conclusions: The management of irAEs is important to provide a significant survival benefit. Systemic chemotherapy with atezolizumab and bevacizumab could restart even if a patient once experienced the atezolizumab-associated grade 3 colitis.

New Research Trends in Onco-carcinogenesis and Nutritional Background Linked with Chronic Inflammation, Iron (Fe) Deposition, and Metabolic Changes

Professor Emeritus, President of Medical Association (Department of Obstetrics and Gynecology) National Defense Medical College Ministry of Defense, Japan

Kenichi Furuya

The metal iron (Fe) plays an important role in biological "redox reactions" under easily ionic transfer between Fe²⁺ and Fe³⁺ in a weakly alkaline environment, so called a normal physiological status. In chemical reaction of iron with oxygen (O₂), radical superoxide (RAS) will be produced, and causing damages of cellular DNA and proteins. Therefore, the optimal balance of iron levels between these beneficial and harmful effects in vivo, should be regulated precisely with not only classical ferritin-transferrin system but also new regulatory factors, including hepcidin, ferroportin, and hephaestine, respectively. Recently, there are a lot of interest on the carcinogenesis underwent chronic inflammation and related fibrosis. as follows: (1) local oxidative stress and cellular damage of RAS in iron-deposit tissues, (2) the hypoxic response in fibrotic tissues and carbohydrate-dominant metabolic changes under mTOR, HIF1 alpha and Glut1 expressions. In this lecture, I would like to introduce ovarian endometriosis (Ov-EM), a very common and a typical chronic inflammatory and fibrosis disorder (local hemorrhage, hemosiderin-deposit, adhesion, and chronic pain) in the female reproductive age. While Ov-EM is a benign-type disease, occasionally ovarian cancer (clear cell adenocarcinoma: CCA, mainly) develops during the follow-up period. This cancer has several characteristics of cellular glycogen storage, slow cell cycle, and chemo-refractory problem, as a poor prognosis. In as gynecological fields, I hope that this overview will be given mutual understanding about carcinogenesis with similar genetic changes and metabolic adaptations.

Case Reports of HCC with IVC and Rt. Atrium Tumor Thrombus and Extension into Left Renal Vein

¹Dr.RML Hospital ²Madras Medical College, Chennai, Tamil Nadu

Parimita Barua¹, Krishnasamy Narayanasamy¹

Hepatocellular carcinoma (HCC) with tumor thrombus extending in hepatic vein, inferior vena cava, and right atrial tumor thrombus are rare and most cases are considered as the advanced stage with a poor prognosis. We report two such cases with tumor thrombus extending to hepatic vein, IVC and right atrium from a single tertiary care centre in South India. Treatment options in such patients are limited as the disease is extensive. However, investigators state that surgery, systemic chemotherapy or intra-arterial chemotherapy, radiation therapy, and supportive care or their combination may help prolong the survival in such patients. Management of such patients is extremely difficult and risky. Compared with published literature one of our cases had hepatic vein, IVC, left renal vein with tumor thrombus in right atrium which has not been reported so far. Both the patients were started on systemic chemotherapy but the patients succumbed to illness after 4 weeks and 7 weeks of initiation of chemotherapy. With interventional techniques in appropriate patients with HCC and right atrial tumour thrombus extension survival may be prolonged. At present there is no treatment consensus for such patients. Whether Combination of Atezolizumab and Bevacizumab is beneficial in such patients needs consideration and enrolment of patients in trails. It is hence imperative to report such rare presentations of HCC and form appropriate treatment management algorithm to achieve the best management for such patients. In this article we have reported to such rare cases from a single tertiary care centre in Southern India.

Novel Immuno-Oncotherapy against HCC by Targeting MICA

¹Division of Gastroenterology, Department of Medicine, Showa University School of Medicine, Tokyo, Japan ²Institut de Recherche sur les Maladies Virales et Hepatiques, INSERM, France ³Department of Gastroenterology, Graduate School of Medicine, Chiba University, Chiba, Japan

Yumi Otoyama¹, Jun Arai¹, Kaku Goto², Ryo Nakagawa³, Ryosuke Muroyama³, Ikuya Sugiura¹, Yoko Nakajima¹, Athushi Kajiwara¹, Yuki Ichikawa¹, Shojiro Uozumi¹, Yuu Shimozuma¹, Manabu Uchikoshi¹, Masaki Sakaki¹, Naoya Kato³, Hitoshi Yoshida¹

Background: The association between natural killer group D ligand, MHC class I polypeptide-related sequence A (MICA) and hepatocellular carcinoma (HCC) development was identified in our previous genome-wide association study. Decreasing soluble MICA (sMICA) through MICA sheddases suppression facilitates natural killer cell-mediated cytotoxicity. Other group and we showed that suppression of a disintegrin and metalloproteinase (ADAM) 9 and ADAM10 contributes to cancer elimination by decreasing sMICA. Interestingly, sMICA downregulation is induced by a multikinase inhibitor, regorafenib (REG) through suppression of ADAM9 transcriptionally and translationally. Herein we further investigated a screening of FDA-approved drugs in vitro to find enzymatic inhibitors of ADAMs.

Methods: Using a fluorescence assay system, the enzymatic activity of ADAM9 and ADAM10 was evaluated. Human HCC cell line PLC/PRF/5 and HepG2 cells were treated with REG or retinoids for 48hr. Cell viability and sMICA level were measured by a CCK8 assay kit and an ELISA kit, respectively.

Results: In our screening of FDA-approved drugs in vitro, retinoids were found to be efficient ADAM9 inhibitors. The enzymatic activity of ADAM10 was also suppressed with retinoids. Treatment with retinoids reduced sMICA levels in human HCC cells. Interestingly, additional administration of REG to retinoids showed stronger suppressive effects of sMICA release more than each monotreatment without significant cytotoxicity.

Conclusions: Retinoids can be potential novel agents for a novel immuno-oncotherapy against HCC to suppress ADAM9 and ADAM10 enzymatic power. Therefore, retinoids should be explored as combination therapy partners with REG for developing therapeutic strategies with enhanced efficacies for HCC management and treatment.

Synergistic Nanoassemblies with Enhanced Cancer Chemo-Immunotherapy

¹Division of Hepatobiliary and Pancreatic Surgery, Department of Surgery, The First Affiliated Hospital, Zhejiang University School of Medicine ²NHFPC Key Laboratory of Combined Multi-organ Transplantation ³Department of Medical Oncology, Sir Run Run Shaw Hospital, Zhejiang University School of Medicine ⁴Department of Chemical Engineering, Zhejiang University

Xiaowei Shi^{1,2}, Liwei Shu³, Yiting Qiao^{1,2}, Jie Yao^{1,4}, Hangxiang Wang^{1,2}, Shusen Zheng^{1,2}

Background: Signal transducer and activator of transcription 3 (STAT3) serves as a converging point of multiple oncogenic pathways and is constitutively activated in a variety of cancer cells lines. Stattic, a selective inhibitor of STAT3, has been explored for targeted cancer therapy and can be applied as an effective adjuvant for conventional therapies to improve therapeutic outcomes.

Methods: Stattic was coassembled in a cabazitaxel prodrug nanoparticle to form a nanoassembly and prepare a co-delivery system. Its antitumor and anti-metastasis activity was evaluated in murine hepatocellular carcinoma H22 cells xenograft-bearing footpad model and murine B16F10 melanoma model. Results: The resultant nanosystem showed favorable colloidal stability, reduced systemic toxicity, improved pharmacokinetics in vivo, and synergistic activity against tumor growth and metastatic burden. Administration of the NPs reduced the percentage of TAMs and MDSCs and elevated CD4+ and CD8+ T cell infiltration, converting the immunologically cold tumors to immunogenic hot tumors and eliciting strong antitumor immunity. Furthermore, by remodeling the tumor microenvironment, stattic synergized with the taxane-based cabazitaxel drug to enhance drug sensitivity.

Conclusions: The intrinsically biodegradable, well-tolerated, and systemically injectable immunostimulatory nanomedicine requires further investigation as a chemo-immunotherapy for the treatment of many types of aggressive cancer.

Various Uses of Ramucirumab in Real World Practice for Patients with Hepatocellular Carcinoma

¹Department of Gastroenterology, Graduate School of Medicine, Chiba University ²Translational Research and Development Center, Chiba University Hospital ³Department of Gastroenterology, Asahi General Hospital, Asahi, Japan ⁴Department of Gastroenterology, Kimitsu Chuo Hospital, Kisarazu, Japan

Naoya Kanogawa¹, Sadahisa Ogasawara^{1,2}, Susumu Maruta³, Yotaro Iino⁴, Masamichi Obu⁴, Ei Itobayashi³, Ryosaku Azemoto⁴, Takafumi Sakuma¹, Fujita Naoto¹, Hiroaki Kanzaki¹, Keisuke Koroki¹, Kazufumi Kobayashi¹, Kiyono Soichiro¹, Masato Nakamura¹, Takayuki Kondo¹, Tomoko Saito¹, Shingo Nakamoto¹, Ryosuke Muroyama¹, Tetsuhiro Chiba¹, Naoya Kato¹

Objectives: Ramucirumab was shown to be effective as second-line treatment after sorafenib in advanced hepatocellular carcinoma (HCC) patients with AFP < 400 ng/mL in the global phase 3 trial. Although the evidence is for second line treatment after sorafenib, ramucirumab has been used in patients who have been pretreated with a variety of systemic therapies in clinical practice since it approved. In this study, we retrospectively examined the treatment outcomes of ramucirumab in patients that administrated after diverse treatments.

Materials and Methods: We corrected data on patients who received ramucirumab in patients with advanced HCC at three institutions in Japan. Radiological assessments were determined according to RECIST version 1.1 and the Common Terminology Criteria for Adverse Events (CTCAE) version 5.0 was used for the assessment of adverse events.

Results: Between June 2019 and August 2020, 21 patients inducted with ramucirumab were included in this study. None of patients received ramucirumab as second line treatment after sorafenib. Second-, third-, and fourth lines treatments were 6 patients (57%), 10 patients (48%), and 5 patients (24%), respectively. Median progression-free survival (PFS) and treatment duration of ramucirumab in this cohort were 2.3 months and 2.2 months, respectively. We confirmed that there were no notable adverse events and no significant changes of ALBI score during ramucirumab treatment.

Conclusion: Even though ramucirumab has been used for other lines than second line treatment immediately after sorafenib, its safety and efficacy seemed to be not significantly different from that of the clinical trial.

Regorafenib and Its Metabolites could Induce NK Cell-mediated Cytotoxicity in HCC by Targeting ADAM9

¹Division of Gastroenterology, Department of Medicine, Showa University School of Medicine, Tokyo, Japan ²Institut de Recherche sur les Maladies Virales et Hepatiques, INSERM, France ³Department of Gastroenterology, Graduate School of Medicine, Chiba University, Chiba, Japan

Jun Arai¹, Yumi Otoyama¹, Kaku Goto², Ryo Nakagawa³, Ryosuke Muroyama³, Keita Ogawa³, Ikuya Sugiura¹, Yoko Nakajima¹, Atsushi Kajiwara¹, Yuki Ichikawa¹, Shojiro Uozumi¹, Yuu Shimosuma¹, Manabu Uchikoshi¹, Masashi Sakaki¹, Naoya Kato³, Hitoshi Yoshida¹

Background: In our previous genome-wide association study, we demonstrated the association between MHC class I-related chain A (MICA) and HCC development. ADAM9 expression in HCC has been reported to correlate with disease prognosis, short overall survival, and metastasis. Increasing membrane-bound MICA (mMICA) and decreasing soluble MICA (sMICA) with suppressing MICA sheddases in HCC has shown stronger natural killer (NK) cell-mediated cytotoxicity. In this study, we evaluated the influence of molecularly targeted drugs for HCC on MICA shedding and identified the detailed mechanism of its modulation.

Methods: Human HCC cell line PLC/PRF/5 and HepG2 cells were treated with cabozantinib, lenvatinib, ramucirumab, bevacizumab, sorafenib, regorafenib and its active metabolites, M2 or M5 at the same concentrations as those in sera of patients. sMICA and mMICA levels were measured by an ELISA kit and FACS, respectively. In the knockdown of notable molecular targets for anticancer drugs, the specific siRNA of VEGFA, VEGFR2, BRAF, and ADAM9, was used.

Results: Knockdown of ADAM9, not of VEGFA, VEGFR2, or BRAF, significantly inhibited MICA shedding. To a greater extent than sorafenib, but without any cytotoxicity, regorafenib significantly suppressed mRNA and protein expression of ADAM9, thereby decreased sMICA and increased mMICA. Accumulation of mMICA in response to regorafenib was reversed by siRNA against ADAM9. Interestingly, M2 and M5 showed stronger suppressive effects of MICA shedding more than regorafenib in a dose-dependent manner.

Conclusion: Regorafenib and sorafenib could be molecularly targeted drugs against ADAM9. In particular, regorafenib, M2, and M5 inhibited MICA shedding via ADAM9 to potentially induce stronger NK cell-mediated cytotoxicity.

Particle Radiotherapy for Hepatocellular Carcinoma with Portal Vein Tumor Thrombosis

¹Department of Radiology, Hyogo Ion Beam Medical Center, Hyogo, Japan ²Department of Radiation Oncology, Hyogo Ion Beam Medical Center Kobe Proton Center, Hyogo, Japan

Yoshiro Matsuo¹, Kazuki Terashima¹, Daiki Takahashi¹, SungChul Park¹, Nor Shazrina Sulaiman¹, Yusuke Demizu^{1,2}, Sunao Tokumaru¹, Tomoaki Okimoto¹

Background: We investigated treatment outcomes of proton beam therapy (PBT) or carbon-ion radiotherapy (CIRT) for hepatocellular carcinoma (HCC) with portal vein tumor thrombosis (PVTT).

Methods: Inclusion criteria were as follows; HCC with PVTT without lymphnodal or extrahepatic metastases. All visible tumors, including primary tumor, PVTT, and intrahepatic metastases, if they existed, were irradiated with definitive doses. Additionally, patients with few and small intrahepatic metastases that could be curatively treated after radiotherapy were considered eligible.

Results: Of the 48 patients considered eligible, 32 had first branch thrombosis, and 16 had main trunk thrombosis. Pretreatment Child-Pugh classification was class A in 28 patients and class B in 20. Radiotherapy was performed using PBT in 28 patients and CIRT in 20. Median radiation dose was 76 Gy (RBE) (range, 66–80 Gy [RBE]), delivered at a median of 3.8 Gy (RBE) (range, 2.0–6.6 Gy [RBE]). The 1- and 2-year overall survival rates were 71.0% and 37.1% and progression-free survival rates were 30.0% and 7.5%, respectively. Local recurrence in 5 patients and as severe rate toxicity, grade 4 dermatitis in 1 patient were observed. Four patients died due to liver failure without any tumor recurrence.

Conclusions: PBT or CIRT showed preferable treatment outcomes.

Efficacy and Safety of Lenvatinib for Patients with Advanced Hepatocellular Carcinoma in Japan

¹Department of Gastroenterology, Nara Medical University ²Department of Gastroenterology, Tenri Hospital, Nara, Japan ³Department of Gastroenterology, Kindai University Nara Hospital, Nara, Japan ⁴Department of Gastroenterology, Nara Prefecture General Medical Center, Nara, Japan ⁵Gastroenterology, Bell Land General Hospital, Osaka, Japan ⁶Department of Gastroenterology, Nara Prefecture Seiwa Medical Center, Nara, Japan ⁷Department of Gastroenterology, Nara Prefecture Nanwa Medical Center, Nara, Japan ⁸Department of Gastroenterology, Saiseikai Chuwa Hospital, Nara, Japan ⁹Department of Internal Medicine, Kokuho Chuo Hospital, Nara, Japan ¹⁰Department of Gastroenterology, Ishinkai Yao General Hospital, Osaka, Japan

Tadashi Namisaki¹, Hiroaki Takaya¹, Masaya Ohana², Toshihiko Kawasaki³, Toshiya Nakatani⁴, Tatsuichi Ann⁵, Motoyuki Yoshida⁶, Masayoshi Sawai⁷, Shigehiko Ueda⁸, Masaaki Yoshikawa⁹, Takuya Tsuruzono¹⁰, Hitoshi Yoshiji¹

Aim: We aimed to study the efficacy and safety of lenvatinib therapy in a real-world and to find the factors associated with response and disease progression in patients with unresectable hepatocellular carcinoma (u-HCC).

Methods: We conducted a multicentre, retrospective study in which 10 tertiary referral centers in Japan. A total of 142 consecutive patients with unresectable HCC treated with lenvatinib between March 2018 and December 2020 were included. Efficacy was evaluated using the modified Response Evaluation Criteria in Solid Tumors (m-RECIST). The patients were grouped into two categories according to the compliance of a phase 3 trial comparing efficacy and safety of lenvatinib to sorafenib for the treatment of u-HCC (REFLECT) eligibility criteria for analysis of efficacy and safety.

Results: The objective response rate (ORR) at week 12 of therapy was 41.5% with a median progression-free survival (PFS) of 176 days. Child-Pugh score (CPS) of 5 points, the presence of extrahepatic metastasis and adverse effects (AEs) \leq Grade 2 (G2) were considered independent factors associated with both PFS and ORR. Patients who fulfilled the REFLECT eligibility criteria displayed a significantly higher ORR than those who did not. However, no significant differences in PFS were observed between the two groups. The incidence rate of AEs \geq G3 was 40.1%, which was similar between the two groups.

Conclusion: Lenvatinib is safe and effective for patients whether or not they satisfy REFLECT criteria. The result warrants replication in a larger study.

HCC Surveillance Remains Cost-effective Long after Hepatitis B Surface Antigen Loss: a 12-year Study

¹Department of Medicine and Therapeutics, The Chinese University of Hong Kong, Hong Kong ²Medical Data Analytics Centre (MDAC), The Chinese University of Hong Kong, Hong Kong ³Institute of Digestive Disease, The Chinese University of Hong Kong, Hong Kong ⁴Faculty of Medicine, The Chinese University of Hong Kong, Hong Kong ⁵Department of Internal Medicine, Union Hospital, Hong Kong

Terry Cheuk-Fung Yip^{1,2,3}, **Mandy Sze-Man Lai**^{1,2}, **Vincent Wai-Sun Wong**^{1,2,3}, **Yee-Kit Tse**^{1,2,3}, **Vicki Wing-Ki Hui**^{1,2,3}, **Lilian Yan Liang**^{1,2,3}, **Henry Lik-Yuen Chan**^{4,5}, **Grace Lai-Hung Wong**^{1,2,3}

Background: Data remains limited regarding the long-term trend of hepatocellular carcinoma (HCC) development in patients who achieved hepatitis B surface antigen (HBsAg) seroclearance. This study examined the change in HCC risk over time among different subgroups of chronic hepatitis B (CHB) patients with HBsAg loss and its implication on HCC surveillance.

Methods: All adult CHB-monoinfected patients who cleared HBsAg between January 2000 and June 2021 were identified via a territory-wide database in Hong Kong. Patients with liver transplantation and/or HCC before HBsAg loss or follow-up less than 6 months were excluded. Comparison of patients before and after year 7 of HBsAg loss was handled as clustered data in Fine-Gray model.

Results: We identified 9,769 CHB patients with HBsAg loss (mean age 57 years, 60.0% male, 3.7% cirrhosis); most had compensated liver function at HBsAg loss. At a mean follow-up of 5.7±4.4 years, 107 (1.1%) patients developed HCC. Patients who developed HCC were older, more likely to be male and cirrhotic, and had lower platelet counts than non-HCC patients. The cumulative incidence of HCC remained steady in 0-7 and 8-12 years after HBsAg seroclearance in all patients, and the subgroups based on age, gender, and cirrhosis status (Figures 1A-1D). HCC surveillance remains cost-effective after 7 years of HBsAg loss in male patients, patients aged over 50 years at HBsAg loss, and cirrhotic patients based on the threshold of 0.2% annual risk.

Conclusion: HCC surveillance remains cost-effective long after HBsAg loss due to advanced age, male gender, and the presence of cirrhosis.

Hepatocellular Carcinoma Emergence in Armenia: Outcome of Multiple Risk Factors, 2019-2020

¹National Centre for Infectious diseases (NCID) ²Institut Pasteur, Unite Organisation Nucleaire et Oncogenese, INSERM U9993, Paris, France

Hasmik Levon Ghazinyan¹, **Pineau Pascal**²

Background: According to the most recent estimates of GLOBOCAN, primary liver cancer (PLC) emerged as a major health threat in Armenia. We intend to provide the first detailed description of PLC risk factor and clinical presentation in Armenia.

Methods: A series of 69 patients were diagnosed with PLC. Demographic data, risk factors, histology, PLC work-up, symptoms and biological variables were collected at the time of diagnosis and patient survival was determined long-term.

Results: HCC was found in the majority of cases of PLC (95.6%) while tumors appeared in patients with cirrhosis in most cases (90.3%). The sex ratio of this series was (M:F=3.9) with the mean age of patients. HCV was the main risk factor (68.1% of cases) followed by heavy alcohol consumption (51.7%) followed by HBV (18.8%). Metabolic disorders were prevalent with 63.7% of the patients with obesity being the most common. The median overall survival time was 10 months (IQR:6-14). Younger patients were characterized by an even high proportion of male sex (94.1% vs 65.7% for patients over 57 years old, P 0.01), as were frequent tobacco consumption. We noticed that HBV-infected patients self-reported significantly higher rates of somatic cancers in their families.

Conclusions: The current problem of HCC in Armenia seems to be due to the presence of HCV spread with metabolic disorders and to the alcohol/tobacco use disorders. Further studies are warranted to characterize viral characteristics and molecular alterations that may promote liver tumorigenesis in Armenia.

Nucleic Acid Analog Therapy and Liver Carcinogenesis in Patients with Chronic Hepatitis B

¹The Department of Gastroenterology, School of Medicine, University of Tokyo, Tokyo, Japan

Makoto Moriyama¹, Ryosuke Tateishi¹, Mizuki Kinoshita (Nishibatake)¹, Tatsuya Minami¹, Masaya Satou¹, Takuma Nakatsuka¹, Taijiro Wake¹, Tomoharu Yamada¹, Tsuyoshi Fukumoto¹, Kazuhiko Koike¹

Background: The purpose of this study was to investigate the relationship between the administration of nucleic acid analogs (NAs) and hepatocarcinogenesis in patients with chronic hepatitis B (CHB).

Methods: A total of 1129 patients with CHB (M/F=704/425, median age=48) who visited the outpatient clinic at our hospital from 1994 to 2019, excluding patients with a history of hepatocellular carcinoma (HCC), were included. The use of NAs during the course of the disease was investigated. Cumulative HCC development was assessed by the Kaplan-Meier method. The risk for HCC development was analyzed using a multivariable time-dependent Cox proportional hazard model with the initiation of NAs as a time-dependent covariate. Age, sex, serum albumin level, platelet count, and HBV-DNA level at enrollment were used for risk adjustment.

Results: The median (interquartile range) values of serum albumin, total bilirubin, AST, ALT, and platelet count were 4.2 (3.9-4.4) g/dL, 0.7 (0.6-1.0) mg/dL, 30 (21-56) IU/L, 33 (19.8-73) IU/L, and 19.3 (15.3-23.3) x 10⁴ /μL, respectively. NAs were already initiated in 59 (5.2%) at enrolment and 360 (31.9%) thereafter. HCC was developed in 113 patients with 5-year and 10-year cumulative rates being 5.4% and 9.2%, respectively. Multivariable time-dependent Cox hazard analysis showed that NAs did not affect the risk of HCC (hazard ratio, 1.07; 95% confidence interval, 0.71-1.62; P = 0.75). Other significant risk factors for HCC were older age, higher AST, and lower platelet count.

Conclusion: The HCC-preventive effect of NAs in CHB was not clear.

Impact of Viral Eradication by DAA on Clinical Outcome after Treatment for HCV Associated HCC

¹Department of Gastroenterology and Metabolism, Graduate School of Biomedical and Health Science, Hiroshima University, Hiroshima, Japan

Yuko Nagaoki¹, Michio Imamura¹, Hiroshi Aikata¹

Aim: We analyzed the impact of hepatitis C virus eradication by interferon-free direct-acting antiviral (DAA) therapy for patients with hepatitis C virus (HCV) -associated hepatocellular carcinoma (HCC) who underwent curative treatment.

Methods: We retrospectively reviewed 109 consecutive patients with HCV-related who achieved SVR by DAA therapy after HCC treatment, analyzed HCC recurrence and overall survival.

Results: Among 109 patients, 64 patients were received DAA therapy after curative treatment for primary HCC, 45 patients after 2 or more treatments for HCC. The cumulative HCC recurrence rates at 1, 3 and 5 years were 23%, 47% and 56%. Multivariate analysis of the predictive value of each variable for suppression of HCC recurrence identified tumor number (HR 2.293 for multiple; P =0.006), number of HCC treatment before DAA therapy (HR 2.928 for 2 or more; P =0.001) as independent predictive factors. Furthermore, among 64 patients after curative treatment for primary HCC, first cumulative HCC recurrence rate at 1, 3 and 5 years were 12%, 34% and 44%, second HCC recurrence rate were 0.5%, 10% and 16%, and third recurrence rate were 0%, 3% and 7% and recurrence rate tended to be suppressed. The respective cumulative overall survival rates at 3 and 5 years were 87%, 75%. Multivariate analysis identified tumor number (HR 2.439 for single; P =0.027) as only independent predictor of overall survival.

Conclusion: DAA therapy after curative treatment for HCC tends to suppress HCC recurrence in the long term, but the recurrence rate was higher with HCC many treatments histories.

The Comprehensive Prognosis of Chronic Hepatitis C after DAA Therapy for Chronic Hepatitis C

¹Department of Gastroenterology and Hepatology, Gunma University Graduate School of Medicine, Gunma, Japan
²Department of Gastroenterology and Hepatology, Public Tomioka General Hospital, Tomioka, Gunma, Japan ³Department of Internal Medicine, Isesaki Municipal Hospital, Isesaki, Gunma, Japan ⁴Department of Gastroenterology, National Hospital Organization Takasaki General Medical Center, Takasaki, Gunma, Japan ⁵Department of Gastroenterology and Hepatology, Kusunoki Hospital, Fujioka, Gunma, Japan ⁶Department of Gastroenterology, National Hospital Organization Shibukawa Medical Center, Shibukawa, Gunma, Japan ⁷Department of Gastroenterology, Jobu Hospital for Respiratory Diseases, Maebashi, Gunma, Japan

Yuki Kanayama¹, Ken Sato¹, Shuichi Saito², Takashi Ueno³, Yasushi Shimada³, Tatsuya Kohga³, Mitsuhiro Shibasaki³, Atsushi Naganuma⁴, Satoshi Takakusagi⁵, Tamon Nagashima⁶, Hiroaki Nakajima⁷, Hitoshi Takagi⁵, Daisuke Uehara¹, Toshio Uraoka¹

Background: The comprehensive prognosis of chronic hepatitis C after direct-acting antivirals (DAA) therapy is still remained to be resolved. We evaluated the comprehensive prognosis including complications.

Methods: Our study was conducted between September 2014 and September 2018. The study subjects were 1461 patients with chronic hepatitis C who received DAA therapy in our university hospital and affiliated hospitals.

Results: Total and lung malignancies more developed in overall and female patients after DAA therapy than those had been expected in the general population. Besides, autoimmune diseases developed in eight (0.5%) cases after starting DAA therapy and five of them such as rheumatoid arthritis were assumed to be associated with DAA therapy based on the attending physicians' judgement. Malignancies including 25 hepatic malignancies, which occupied for 60.2% of all cause of death, were the most frequent primary cause of death. Cirrhosis was an only predictive risk factor associated with the occurrence of hepatic malignancies while the use of insulin/protein induced by vitamin K absence or antagonist-II level/albumin-bilirubin (ALBI) score were predictive risk factors associated with the recurrence of hepatic malignancies after DAA therapy in patients who achieved sustained virological response that means viral elimination.

Conclusion: DAA therapy for patients with chronic hepatitis C might increase the incidence of total and lung cancers and cause autoimmune diseases. We should keep in mind that not only liver cancers but also these unexpected diseases might be developed after DAA therapy. These findings should be confirmed in future large-scale worldwide studies.

Comparison of HBV Reactivation in HCC Patients Who Received TKI and TKI with PD-1 Inhibitor

¹Guizhou Medical University ²Comprehensive Liver Cancer Center, the 5th Medical Center of the PLA General Hospital, Beijing, China ³Department of Hepatobiliary Surgery, The Affiliated Hospital of Guizhou Medical University, Guiyang, China ⁴Peking University 302 Clinical Medical School, Beijing, China ⁵National Clinical Medical Research Center for Virus Hepatitis, the Fifth Medical Center of Chinese PLA General Hospital, Beijing, China.

Jin Lei¹, Tao Yan², Shi Zuo³, Bowen Chen⁴, Linzhi Zhang², Yinying Lu^{2,5}

Background: Studies have shown that the reactivation of hepatitis B virus (HBV) was observed in minority of patients with primary liver cancer during immunosuppressant treatment, but the correlation between HBV reactivation and immunotherapy remains unclear.

Methods: The retrospective analysis was performed on data collected at the 5th Medical Center of the PLA General Hospital from March 2017 to March 2021, gathered from inpatients who received either TKI or TKI combined with PD-1 inhibitor. All subjects were treated with standard antiviral therapy. The primary endpoint was the occurrence of HBV reactivation. HBV reactivation was defined as an increase of ≥ 1 log for HBV DNA from baseline, or as seropositive for HBV DNA but undetectable serum HBV DNA at baseline.

Results: A total of 499 eligible patients were included, among whom 296 patients received TKI monotherapy and 203 patients received TKI combined with PD-1 inhibitor. The median follow-up time was 4.7 (2.8,8.9) months. The 3months,6months,9months cumulative incidence of HBV reactivation in TKI and TKI combined with PD-1 inhibitor groups was 6.2%,20.4%,33.4% and 13%,30.8%,44.3%($P=0.01$), respectively. The Cox proportional hazard model indicated that combination therapy, ALT >40 U/L, and AFP >400 ug/ml were independent risk factors for HBV reactivation. 90 patients (59.2%) with HBV reactivation had tumor progression, and 102 patients (29.4%) without HBV reactivation had tumor progression during the follow-up period ($P=0.001$).

Conclusion: Patients who received TKI combined with PD-1 inhibitor had a greater risk for HBV reactivation, and patients with HBV reactivation had a higher rate of tumor progression.

Occult Hepatitis B Virus Infection in Patients with HCV-Related Hepatocellular Carcinoma

¹Department of Hepatology, Gastroenterology, and Infectious Diseases, Al-Azhar University, Assiut, Egypt ²Sohag Center of Cardiac and Digestive System, Ministry of Health, Sohag, Egypt

Muhammad Abdel-Gawad¹, Ahmed Alsayed Mohammedin², Khaled Abd El-Azeem¹

Background: Occult hepatitis B virus (HBV) infection (OBI) is the presence of HBV DNA in the liver tissue and/or peripheral blood in the absence of HBsAg with or without serologic evidence of previous HBV infection. HBV is an oncogenic virus that can lead to hepatocellular carcinoma (HCC) even on healthy non-cirrhotic liver. In Egypt, Hepatitis C virus (HCV) is the most common cause of cirrhosis and HCC. We aimed to assess the prevalence of OBI in patients with HCV-related HCC.

Methods: We prospectively enrolled 100 confirmed chronic HCV patients in a cross-sectional survey study for detection of OBI in HCV-related HCC. We classified patients into 2 groups: Group 1, included 50 patients with HCV without HCC, Group 2, included 50 patients with HCV plus HCC (based on CT and/or MRI of the liver). All patients were subjected to history taking, clinical examination, routine investigations, HBsAg and HBc antibodies assessment, and HBV PCR in serum. Patients with positive HBsAg were excluded.

Results: HBV DNA was detected in 12 patients in group 2 and 2 patients in group 1 ($p = 0.004$), while HBc antibodies were detected in 14 patients in group 2 versus 4 patients in group 1 ($p = 0.009$). OBI patients had higher bilirubin, ALT, INR, AFP, and creatinine levels than non-OBI patients.

Conclusions: OBI is present in 24% of HCV-related HCC patients and they tend to have a more advanced liver disease with higher bilirubin, ALT, and INR levels than non-OBI patients.

Bone Mineral Density in Patients with Non-Alcoholic Fatty Liver Disease

¹Department of Hepatology, Gastroenterology, and Infectious Diseases, Al-Azhar University, Assiut, Egypt ²Rheumatology and Rehabilitation, Al-Azhar University, Assiut, Egypt ³Clinical Pathology, Al-Azhar University, Assiut, Egypt ⁴Internal Medicine, Al-Azhar University, Assiut, Egypt ⁵Medical biochemistry, Suez University, Suez, Egypt ⁶Medical Biochemistry, Al-Azhar University, Assiut, Egypt ⁷Radiodiagnosis, Al-Azhar University, Assiut, Egypt

Muhammad Abdel-Gawad¹, Amro M. Hassan¹, Mohamed Z. Shoaier², Tarek M. Abdel Aziz², Tarek M. M. Mansour⁷, Eglal Kenawy⁴, Abdallah Salem Abdelazem⁵, Sameh Salah Eldin Elsayed⁶, Mustafa A. Haridy¹, Wael Esmat Ali³, Mona M. Abdelmeguid³

Background: The association between Non-Alcoholic Fatty Liver Disease (NAFLD) and decline of bone mineral density (BMD) is a matter of controversy. Aim: We aimed to assess the BMD in NAFLD patients.

Methods: Fifty adult patients (aged 18-78 years, 28 male and 22 female) with NAFLD (based on ultrasound and fatty liver index) and 50 healthy controls (cross-matched in age, sex, and BMI) were included in this cross-sectional study. They were subjected to liver ultrasonography, BMD measurement by dual-energy X-ray absorptiometry (D.E.X.A), fasting insulin, fasting blood sugar, HOMA-IR calculation, serum Ca, P, Vitamin D3, parathormone hormone (PTH), anthropometric measurements, and routine investigations.

Results: NAFLD patients showed significantly decreased BMD (-2.14 Vs -1.51), Vitamin D3 (28.44 Vs 61.5), and Ca (8.37 Vs 9.85) and significant increase in PTH (56.26 Vs 32.48) levels than the control group. There were no significant differences in serum P or HOMA-IR levels between cases and controls.

Conclusions: NAFLD is associated with significant decrease in BMD, Vitamin D3, and Ca levels and significant increase in PTH levels. This association could have a pathogenic role in the development of NAFLD.

Contribution of dMMR to Accumulation of Somatic Mutations at Different Stages of HCC Development

¹Department of Gastroenterology and Hepatology, Graduate School of Medicine, Kyoto University ²Department of Surgery, Graduate School of Medicine, Kyoto University, Japan

Masayuki Ueno¹, Haruhiko Takeda¹, Atsushi Takai¹, Yuji Eso¹, Shigeharu Nakano¹, Ken Takahashi¹, Kojiro Taura², Etsuro Hatano², Hiroshi Seno¹

Background: Several patterns of genetic mutations are associated with hepatocellular carcinoma (HCC). Here we investigated the contribution of mismatch repair deficiency (dMMR) to the accumulation of somatic mutations at different stages of HCC development.

Methods: We analyzed multi-regional whole-genome or whole-exome sequencing data of 14 patients with HCC (own cases, n=5; public data, n=9). Samples were obtained from multiple sites of every tumor; a total of 58 samples were evaluable. In each patient, trunk mutations and late mutations were defined as single nucleotide variants (SNVs) found in all samples and those found in only one sample, respectively. COSMIC mutational signatures were determined by using MutationalPatterns in R software. The proportions of dMMR-associated mutations among all detected mutations were compared between trunk and late mutations. As a control, whole-genome sequencing data of noncancerous liver tissues obtained from 14 patients (normal liver, n=5; cirrhosis, n=9; a total of 482 samples) were also analyzed.

Results: In the analysis of HCC cases, a total of 133,165 trunk mutations and 102,449 late mutations were identified. The proportion of dMMR-associated mutations was significantly higher in the late mutations (median 0% [range: 0-9.2%] vs. 8.3% [0-14.2%], p=0.001). In the analysis of noncancerous liver tissues, a total of 830,147 mutations were identified, none of which was dMMR-associated; the proportion was significantly lower than trunk mutations in HCC cases (p=0.018).

Conclusions: The mutational signature analysis revealed that defective mismatch repair is involved in the somatic mutation accumulation in HCC, especially at the later stage of progression.

Genetic Discrimination between Multicentric Occurrence and Intrahepatic Metastasis in multifocal HCC

¹Department of Surgery, Yamanashi Central Hospital, Yamanashi, Japan ²Genome Analysis Center, Yamanashi Central Hospital, Yamanashi, Japan ³Department of Medicine, Yamanashi Central Hospital, Yamanashi, Japan ⁴Department of Medicine, Teikyo University Chiba Medical Center, Chiba, Japan ⁵The University of Tokyo, Tokyo, Japan

Yuji Iimuro¹, Atsushi Takano¹, Kenji Amemiya², Yosuke Hirotsu², Hitoshi Mochizuki³, Shuntaro Obi⁴, Masao Omata^{3,5}

Background: Genetic differentiation of MO from IM in multifocal HCCs may be critically important. The AIM of present study was to analyze prognosis of multifocal HCCs after surgical resection on the basis of genetic differentiation; MO or IM.

Methods: We have genetically analyzed 163 HCC nodules from 90 patients who underwent surgical resection in our hospital. HCC samples were analyzed employing a next generation sequencer. We performed in-house targeted sequencing covering 72 SMGs associated with HCC, spanning 285,470 nucleotides. Among 90, we focused on 29 patients with multifocal nodules (2-4) at surgery analyzing post-surgical prognosis.

Results: Out of 29 patients with multifocal HCCs, 20 were MC harboring no common genetic mutation between the nodules. Meanwhile, 9 patients were IM possessing at least one common mutation. RFS in MC/IM at 1, 2, 3 year was 84%/56%, 55%/37%, and 33%/37%, respectively (p=0.050). OS in MC/IM at 1, 2, 3 year was 100%/89%, 94%/59%, 81%/59%, respectively (p=0.074). Intriguingly, recurrence was detected in 10 out of 20 MCs, while 6 out of 10 recurrences are HCC-free after second treatment. Meanwhile, 6 out of 9 IMs experienced recurrence, and none of 6 were tumor-free after recurrence.

Conclusion: Multifocal HCCs genetically classified as MC had better prognosis after surgery. In these patients, relatively long tumor-free survival can be expected even after recurrence by appropriate second treatments. Genetic differentiation in multifocal HCCs using our in-house panel has important clinical significance.

An Assistive Computational Tool for Defining the Segmental Anatomy of the Liver

Auckland Bioengineering Institute, The University of Auckland
Harvey Ho

Background: The segmental anatomy of the liver, which is based on the hepatic and portal vein anatomy, is crucial for liver resection and/or transplantation. The conventional Couinaud classification does not always capture patient-specific features of the segmental anatomy due to great inter-subject differences. We present in this work a novel computational tool for defining the segmental anatomy per different classifications.

Methods: The tool is based on the interaction of two sets of mathematically described parametric meshes. One set of the mesh is a “slave-mesh” representing the liver, while the other set of mesh is a “host-mesh” comprising of bounding boxes that imitate the classification of Couinaud or others. The host mesh is manipulated by users per the morphology of hepatic vessels. The overlapping of the two meshes yields the segmental anatomy.

Results: We demonstrate the use of this method in two case studies, i.e. the Visible Human liver and a subject-specific liver. The method is able to instantly enhance vessels within a liver segment, and also evaluate the segmental volume in real-time. We show that the Visible Human liver is better described by the Cho's classification, and the subject-specific case by the Couinaud classification.

Conclusion: We suggest such a methodology having good potential to be adopted in surgical planning and/or intra-operational navigation applications.

The Protective Role of DNA Methyltransferase 3B against Inflammatory Hepatocarcinogenesis

¹Department of Gastroenterology and Hepatology, Graduate School of Medicine, Kyoto University, Kyoto, Japan
Eriko Iguchi¹, Atsushi Takai¹, Ken Kumagai¹, Haruhiko Takeda¹, Yuji Eso¹, Takahiro Shimizu¹, Hiroshi Seno¹

The mechanism of epigenetic regulation in inflammatory hepatocarcinogenesis is not fully elucidated yet. DNMT3B, one of *de novo* DNA methyltransferases, has recently been reported to act specifically on actively transcribed genes, suggesting its possible role in the pathogenesis of cancer. This possibility is also supported by our finding that DNMT3B isoforms lacking its catalytic domain are highly expressed in hepatocellular carcinomas (HCCs) compared with non-tumorous liver tissue. To study the role of DNMT3B in hepatocarcinogenesis, we generated a genetically engineered mouse model with hepatocyte-specific *Dnmt3b* deletion. *Dnmt3b*-deficient liver, validated to have a lower CG methylation level than control liver, exhibited an exacerbation of thioacetamide-induced hepatitis and a higher incidence of HCC. Transcriptome analysis indicated decreased expression of genes related to oxidative phosphorylation in the *Dnmt3b*-deficient liver. Moreover, primary hepatocytes isolated from the *Dnmt3b*-deficient mice showed reduced mitochondrial respiratory capacity, leading to the enhancement of oxidative stress in the liver tissue. Our findings suggest the protective role of DNMT3B against chronic inflammation and HCC development via maintaining mitochondrial homeostasis. Next, we explore the effect of DNA methylation on genome mutagenesis. We previously revealed that aberrant expression of activation-induced cytidine deaminase (AID), which converts unmethylated C to T in genomic DNA, contributed to HCC development. We exploited a mouse model of hepatocyte-specific AID overexpression with or without *Dnmt3b* deletion. Surprisingly, although unmethylated C was enriched in *Dnmt3b*-deficient mice, less mutations were detected by whole-exome sequencing analysis. These data suggested the possible non-canonical role of DNMT3B in mutagenesis via the interaction with AID.

Utility of AFP, AFP-L3, and PIVKA-II for Hepatocellular Carcinoma Surveillance

¹Division of Gastroenterology, Department of Medicine, Siriraj Hospital, Mahidol University, Bangkok, Thailand

²Department of Surgery, Siriraj Hospital, Mahidol University, Bangkok, Thailand ³Department of Radiology, Siriraj Hospital, Mahidol University, Bangkok, Thailand

Supot Nimanong¹, Phunchai Charatcharoenwitthaya¹, Siwaporn Chainuvati¹, Watcharasak Chotiyaputta¹, Yongyut Sirivatanauksorn², Prawat Kositamongkol², Chutwichai Tovikkai², Trongtum Tongdee³, Piyaporn Apisarntharak³, Vitoon Chinswangwatanakul², Tawesak Tanwandee¹

Background: Combination of ultrasonography (US) and alpha-fetoprotein (AFP) is widely recommended as a surveillance tool for hepatocellular carcinoma (HCC). Lens culinaris-agglutinin-reactive fraction of AFP (AFP-L3) and protein induced by vitamin K absence or antagonist-II (PIVKA-II) are potential surveillance tests for HCC. The aim of this study was to determine performance of AFP, AFP-L3, PIVKA-II and their combinations with US for HCC surveillance.

Methods: This prospective study enrolled patients with cirrhosis or high risk non-cirrhotic chronic hepatitis B (HBV). US, AFP, AFP-L3 and PIVKA-II were measured. Cross-sectional imaging (CT or MRI) was performed in patients who had abnormal tests (cutoff: 20 ng/ml for AFP, 10% for AFP-L3, and 40 mAU/mL for PIVKA-II).

Results: Among 1003 enrolled patients, 71.7% had cirrhosis, 56.0% were men; the median age was 60.1 years. The major etiology of chronic liver disease were HBV (78.5%). HCC was diagnosed in 33 patients (3.3%); the median size was 1.85 cm and all of them were within Milan criteria. Among 3 biomarkers, PIVKA-II showed the highest sensitivity (51.5%) followed by AFP-L3 (24.2%) and AFP (9.1%). The sensitivity of US and combination of US with AFP were 51.5% and 54.5% respectively. Combining triple markers with US increased the sensitivity to 87.9%. The AUC of US, combined US with AFP and US with triple markers were 0.964, 0.961, and 0.944 respectively.

Conclusion: PIVKA-II was more sensitive than AFP and AFP-L3, and combination of triple markers with US markedly improved the sensitivity compared with US or US with AFP in early HCC detection.

Natural Killer Cells Putative Role in Patients with HCV-Related Hepatocellular Carcinoma

¹Department of Hepatology and Gastroenterology, National Liver Institute, Menoufia University, Shebin El-Kom, Egypt

²Clinical and Chemical Pathology, National Liver Institute, Menoufia University, Shebeen El-Kom, Egypt ³Clinical Pathology, National Cancer Institute, Cairo University, Cairo, Egypt ⁴Physiology, Faculty of Medicine, Cairo University, Cairo, Egypt. ⁵Clinical Pathology, Faculty of Medicine, Zagazig University, Egypt.

Mohamed Abdel-Samiee¹, Mona M Hassouna², Enas M Radwan³, Eman Abdelsameea¹, Suzanne Estaphan⁴, Heba E Abd Elrhman⁵, Mary Naguib²

Background: Natural Killer (NK) cells have crucial roles in immune responses against malignant transformation including hepatocellular carcinoma (HCC). The NKG2D receptor has a critical role in the NK recognition of target cells. Aim: We assessed NKG2D receptor expression as a diagnostic biomarker for HCC detection and progression in Egyptian patients with hepatitis C virus (HCV)-related HCC.

Methods: We classified 81 patients into three groups: chronic hepatitis (21), cirrhotic (30) and HCC (30) patients, with 36 individuals enrolled to the control group. We analyzed NK levels in peripheral blood and NKG2D receptor expression in NK cells using flow cytometry.

Results: We observed a significant decrease in NKG2D (CD314) expression on circulating NK cells and frequency of NK cells expressing NKG2D (CD314) in HCC patients. Also, in patients, larger foci lesions significantly correlated with decreased NK cell numbers. Multiple foci numbers and patients with a Child score C significantly correlated with decreased circulating NK cells expressing NKG2D and decreased NKG2D expression.

Conclusion: The percentage of NK cells in peripheral blood and NKG2D receptor expression could function as potential biomarkers for HCC detection and progression.

Let-7a and Let-7i as Biomarkers for CHC Patients with HCC Risk after Anti-viral Treatment

¹Hepatobiliary Division, Department of Internal Medicine and Hepatitis Center, Kaohsiung Medical University Hospital, Kaohsiung Medical University, Kaohsiung, Taiwan ²Faculty of Internal Medicine, College of Medicine, Graduate Institute of Clinical Medicine, Kaohsiung Medical University, Kaohsiung, Taiwan ³Health Management Center, Kaohsiung Medical University Hospital, Kaohsiung Medical University, Kaohsiung, Taiwan

Ming-Lung Yu^{1,2}, **Yishan Tsai**¹, **Ching-I Huang**¹, **Pei-Chien Tsai**¹, **Ming-Lun Yeh**^{1,2}, **Chung-Feng Huang**^{1,2}, **Meng-Hsuan Hsieh**^{1,2,3}, **Ta-Wei Liu**¹, **Yi-Hung Lin**¹, **Po-Cheng Liang**¹, **Zu-Yau Lin**¹, **Jee-Fu Huang**^{1,2}, **Wan-Long Chuang**^{1,2}, **Chia-Yen Dai**^{1,2}

Background: Hepatocellular carcinoma (HCC) is the leading cause of cancer-related mortality worldwide. Although antiviral therapy reduced the risk of HCC among chronic hepatitis C (CHC) patients, HCC risk remains highlighting the unmet need for continuous surveillance. Whether circulating microRNAs, could serve as noninvasive markers for HCC risk need to be evaluated.

Methods: We analyzed the sera Let-7 family from 236 patients with CHC (including development of HCC in 54 patients with CHC) using real-time quantitative PCR (qPCR) and univariate and multivariate regression models.

Results: The results of qPCR showed differences in Let-7 family serum levels between patients with CHC with and without HCC after antiviral treatment. We found that the Let-7 family (except for Let-7c) exhibited significant negative correlations with fibrosis score ($r = -0.13$ to -0.33 , $p = 0.0149$ to <0.0001). We further conducted multivariate analysis with Let-7 family, age, sex, HCV RNA levels, HCV genotype, SVR, and advanced hepatic fibrosis as covariables. The only independent factors for HCC were Let-7a and Let-7i sensitivity (0.8286 and 0.9143, respectively) with area under the curve (AUC) 0.825, odds ratio (OR) 0.41, 95% confidence interval (CI) 0.19~0.87, $p = 0.0211$ and AUC 0.831, OR 0.32, 95% CI 0.14~0.73, $p = 0.0070$, respectively.

Conclusion: Thus, circulating Let-7a and Let-7i can be used in early surveillance for CHC with HCC risk.

Post-treatment Cell-free DNA as a Predictive Biomarker in Systemic Therapy for HCC

¹Department of Gastroenterology, The University of Tokyo, Tokyo, Japan

Takuma Nakatsuka¹, **Hayato Nakagawa**¹, **Taijiro Wake**¹, **Tomoharu Yamada**¹, **Masaya Sato**¹, **Tatsuya Minami**¹, **Yotaro Kudo**¹, **Yasuo Tanaka**¹, **Motoyuki Otsuka**¹, **Ryosuke Tateishi**¹, **Kazuhiko Koike**¹

Background: Liquid biopsies, particularly those involving circulating tumor DNA (ctDNA), are rapidly emerging as a non-invasive alternative to tumor biopsies. However, clinical applications of ctDNA analysis in hepatocellular carcinoma (HCC) have not been fully elucidated.

Methods: We measured the amount of plasma-derived cell-free DNA (cfDNA) in 100 HCC patients before and a few days after treatment, including radiofrequency ablation, transarterial chemoembolization, and molecular-targeted agents (MTAs), and prospectively analyzed their associations with clinical parameters and prognosis. TERT promoter mutations in cfDNA were analyzed using droplet digital PCR. Furthermore, we performed a comprehensive mutational analysis of post-treatment cfDNA via targeted ultra-deep sequencing (22,000x coverage) in a panel of 275 cancer-related genes in selected patients.

Results: Plasma cfDNA levels increased significantly according to HCC clinical stage, and a high cfDNA level was independently associated with a poor prognosis. cfDNA levels increased significantly a few days after treatment, and a greater increase in post-treatment cfDNA levels was associated with a greater therapeutic response to MTAs. TERT promoter mutations were detected in 45% of all cases with pre-treatment cfDNA. However, the detection rate increased to 57% using post-treatment cfDNA, suggesting that ctDNA is enriched in plasma several days after treatment. Targeted ultra-deep sequencing using post-treatment cfDNA after administering lenvatinib successfully detected various gene mutations; AMER1, MLL3, and NOTCH2 were commonly mutated in lenvatinib-responsive cases. HCC cell lines carrying these mutations were susceptible to lenvatinib in vitro.

Conclusions: Post-treatment cfDNA analysis may facilitate the construction of biomarkers for predicting MTA treatment effects.

The Combination of ALBI and PT Predict Liver Dysfunction after TACE for HCC within up-to-7 Criteria

¹Department of Gastroenterology, Nara Medical University

Hiroaki Takaya¹, Tadashi Namisaki¹, Soichi Takeda¹, Kosuke Kaji¹, Hitoshi Yoshiji¹

Mortality and recurrence rates of hepatocellular carcinoma (HCC) are high. Recent studies show that for patients with HCC beyond up-to-seven criteria, treatment with molecular-targeted agents (MTAs) is recommended because the treatment efficiency of transcatheter arterial chemoembolization (TACE) is poor; further, TACE increases decline in liver function. However, the relationship between TACE and liver function decline in patients with HCC within up-to-seven criteria has not been clarified. Hence, we aimed to investigate this relationship. This retrospective observational study included 189 HCC tumors within up-to-seven criteria in 114 Child-Pugh class A patients. Twenty-four (12.7%) tumors were changed from Child-Pugh class A to B after TACE, and 116 (61.4%) tumors exhibited recurrence within 6 months after TACE. Prothrombin time (PT) and albumin-bilirubin (ALBI) score before TACE were significantly associated with liver dysfunction from Child-Pugh class A to B. The combination of PT and ALBI score before TACE had high predictive ability for liver dysfunction from Child-Pugh class A to B after TACE (specificity = 100%, sensitivity = 91.7%). The combined use of pre-TACE PT and ALBI score has a high predictive ability for liver dysfunction after TACE for Child-Pugh class A patients with HCC within up-to-seven criteria.

MicroRNA Gene Polymorphisms and Development of Hepatocellular Carcinoma in Egyptian Patients

¹Department of Hepatology and Gastroenterology, National Liver Institute, Menoufia University, Shebin El-Kom, Egypt.

²Clinical and Chemical Pathology, National Liver Institute, Menoufia University, Shebeen El-Kom, Egypt. ³Microbiology, National Liver Institute, Menoufia University, Shebeen El-Kom, Egypt. ⁴Biochemistry, National Liver Institute, Menoufia University, Shebeen El-Kom, Egypt

Mohamed Abdel-Samiee¹, Maha M. Allam², Karema A. Diab², Fatma O. Khalil³, Fatma A. Khalaf⁴, Nashwa Sheble¹, Mohamed A Eljaky¹, Mervat Abdelkereem¹, Warda Othman¹, Eman Abdelsameea¹

Background: Multiple risk factors are correlated with hepatocellular carcinoma (HCC). MicroRNA is differentially expressed in development of different types of malignancies, including hepatic malignancy. Single nucleotide polymorphisms (SNPs) are the most common sequence variation in human genome. SNPs in microRNAs may affect transcription, processing or target recognition and result in malignant diseases.

Aim: The aim was to determine the association between microRNA gene polymorphisms and development of HCC in the Egyptian Patients. **Patients and Methods** This study included 200 individual who were matched in age and sex. Tumor staging was done using BCLC staging system. Quantification and genotyping of microRNA were performed.

Results: Among the 200 patients, 2 groups were described: group I included 90 HCC patients with a male majority (72.2%) and 110 controls in group II. Diabetes and hypertension were detected as risk factors. Three microRNA SNPs were assayed. There was a significant association between rs10061133 miR-499b and the risk of HCC. The genotypes GG or G allele were associated significantly to an increased risk of HCC (GG: OR (95% CI) = 2.91 (1.23-4.22), p = 0.013; G allele: OR (95% CI) = 1.79 (1.12- 2.15), p = 0.026) compared with the genotype of AA or AG or A allele.

Conclusion: There is an association between the mi-RNA SNPs and the susceptibility to HCC, aiming to explore some roles and mechanisms of SNPs within microRNAs in the occurrence and the development of HCC.

Analysis of Sarcopenia in Patients with BCLC Stage B HCC Who Received Atezolizumab Plus Bevacizumab

¹Department of Gastroenterology and Hepatology, Musashino Red Cross Hospital

Hiroaki Matsumoto¹, Kaoru Tsuchiya¹, Yuka Hayakawa¹, Hiroyuki Nakanishi¹, Yuki Tanaka¹, Shun Isido¹, Kento Inada¹, Sakura Kirino¹, Koji Yamamashita¹, Tsubasa Nobusawa¹, Tatsuya Kakegawa¹, Mayu Higuchi¹, Kenta Takaura¹, Shouhei Tanaka¹, Shun Kaneko¹, Chiaki Maeyashiki¹, Yutaka Yasui¹, Masayuki Kurosaki¹, Namiki Izumi¹

Background: Previous studies reported that sarcopenia was associated with overall survival in hepatocellular carcinoma (HCC) patients. Atezolizumab plus bevacizumab (Ate+Bev) is recently recommended as first-line. We investigated the change of skeletal muscle mass during Ate+Bev in unresectable BCLC stage B HCC patients.

Methods: The patients with BCLC stage B HCC who received Ate+Bev as first-line at our institution were included. The skeletal muscle mass index (SMI) was calculated from the skeletal muscle area at the L3 level of the lumbar vertebrae using computed tomography. Sarcopenia was defined as an L3SMI value ≤ 42 cm²/m² for men and 38 cm²/m² for women. We compared the SMI between before and 8-12 weeks after the administration of the agents.

Results: Twenty-nine patients were included. There was no significant difference in time-to-progression (TTP) between the patients with (n=11) and without pre-sarcopenia (n=18), but there was a trend of short TTP in patients with pre-sarcopenia (median TTP not reached vs. 9 months, p=0.056). The median change of SMI between pretreatment and 8-12 weeks after administration was -0.55 (-2.38-6.79). The patients with a decrease of SMI (n=13) had shorter TTP than patients without a decrease (n=14) (median TTP 8 months vs. not reached, p=0.0004). Age (p=0.041), ALT (p=0.02), Cre (p=0.046), WBC (p=0.0132) were associated with decrease of SMI. In a multivariable analysis, age was an only significant factor associated with SMI decrease (HR 1.16, p=0.047).

Conclusion: The decrease of SMI during atezolizumab plus bevacizumab was significantly associated with TTP in HCC patients with BCLC stage B.

The Simple Product of Albumin and Platelets Indicates the Stage of Liver Fibrosis and Prognosis

¹Department of Gastroenterology and Neurology, Faculty of Medicine, Kagawa University, Japan ²National Hospital Organization Nagasaki Medical Center ³Department of Medical Technology, Kagawa Prefectural University of Health Sciences

Koji Fujita¹, Kazumi Yamasaki², Kei Takuma¹, Mai Nakahara¹, Kyoko Oura¹, Tomoko Tadokoro¹, Joji Tani¹, Asahiro Morishita¹, Takashi Himoto³, Masafumi Ono¹, Hiroshi Yatsuhashi², Tsutomu Masaki¹

The Fibrosis-4 index, a conventional biomarker of liver fibrosis stage, has been confounded with age and hepatitis activity grade. In this multicenter retrospective study, we aimed to create a new liver fibrosis index by mathematically combining items from peripheral blood tests and to evaluate its prognostic ability. After establishing the new index in the training cohort, the index was validated in the validation cohort. A total of 426 patients were enrolled in the training cohort. Among the blood tests, albumin and platelets correlated most strongly with fibrosis stage. Albumin platelet product (APP) = albumin × platelets/1000 was able to distinguish four stages of liver fibrosis (p < 0.05). APP indicated the stage of fibrosis independent of hepatitis activity. At the cutoff value = 4.349, cirrhosis was diagnosed when the area under ROC was 0.8 or more. Multivariate analysis revealed that smaller values of APP independently contributed to the prevalence of hepatocellular carcinoma and all-cause mortality. These results were also validated in another 707 patients infected with HCV. In conclusion, APP was found to be unaffected by age or hepatitis activity, in contrast to the Fibrosis-4 index. APP is so simple that a physician can calculate it with written calculations. This product is useful for physicians who manage patients with chronic liver disease.

APASL Oncology 2021 Tokyo

“Your Gateway to Oncology in Asia-Pacific Region”

Abstracts

Poster Free Papers



FBL is the Hub Gene of Pulmonary Metastasis in Hepatocellular Carcinoma

¹Department of Biliary-Pancreatic Surgery, Sun Yat-sen Memorial Hospital, Sun Yat-sen University, Guangzhou, China
Wen-Rui Wu¹, Wei-Xin Luo¹

Background: The genetic mechanism of pulmonary metastasis in hepatocellular carcinoma (HCC) remains unknown. Here, we aimed to identify the hub gene related to HCC with pulmonary metastasis by weighted gene co-expression network analysis (WGCNA).

Methods: Transcriptome data of HCC were obtained from TCGA dataset. The hub gene were selected by WGCNA. Kyoto Encyclopedia of Genes and Genomes (KEGG) pathway analysis, Gene Ontology (GO) term enrichment analysis, Protein-Protein Interaction (PPI) Network analysis, Gene Set Enrichment Analysis (GSEA) and a series of studies in vitro were also performed.

Results: 67 genes related to pulmonary metastasis of HCC were identified. They were mainly distributed in items related to ribosome/RNA transcription in cellular component and enriched in items related to ribosome synthesis/protein translation in biological process. Besides, 3 pathways related to ribosome/RNA polymerase were enriched as the most important pathways. In particular, the ribosome-related gene Fibrillarin (FBL) was identified as the hub gene. Clinical studies by TCGA (n=370) and GEO (n=347) datasets as well as our cohort (n=229) confirmed that HCC patients with high FBL expression showed poor overall and disease-free survival. Pathology studies revealed that high FBL expression was associated with elevated pulmonary metastasis, serum alpha-fetoprotein level, pathological grade, vascular invasion and TNM staging (our cohort, n=229). Silencing FBL significantly impaired the proliferation, migration, invasion ability and stemness property of HCC cell lines Huh7 and PLC/PRF/5 in vitro.

Conclusions: FBL was identified as the hub gene of HCC with pulmonary metastasis. Further research on FBL is clearly warranted.

Everolimus Protect IRI through the Effect of Treg

¹Changzhou First People's Hospital, Jiangsu, China
Li Zhu¹, Wei Ding¹, Yunfei Duan¹, Donglin Sun¹, Yunjie Lu¹

Objective: Ischemia-reperfusion injury (IRI) of the liver is a serious complication following hemorrhagic shock and liver surgery. The present study was designed to investigate the efficacy and mechanism of everolimus on Tregs for the treatment of IRI.

Methods: The effects of everolimus on liver IRI were investigated in warm ischemia liver model. The function of everolimus against ROS-induced injury was investigated by exposing hepatocytes to H₂O₂. The protective effect of everolimus against H/R-induced injury was investigated in hepatocytes exposed to anoxia followed by reoxygenation. To test whether Foxp3 expression is involved in the protective effect of everolimus in IRI, we examined the levels of Foxp3, Helios and CD45RB expression following treatment with everolimus. To determine whether Tregs are essential for the protection effect of everolimus during IRI development, we have administrated monoclonal Ab against CD25 (R&D) in experimental animals. Western blot analysis was used to examine the effect of everolimus on GSK, AKT and mTOR phosphorylation.

Results: Oral gavage of everolimus markedly attenuates liver IRI. Everolimus presents strong protective effects against H₂O₂ or H/R-induced damage in hepatocytes by reducing caspase-3 expression. Everolimus improved the percentage of Treg cells and converted cytokine expression in murine model. Everolimus protect IRI through the effect of Treg. Everolimus increased the levels of p-AKT, p-mTOR but not p-GSK in the following IRI.

Conclusions: our present study suggested that everolimus improved the efficacy of Tregs for liver IRI through the PI3K/AKT/mTOR pathway.

Sex-related Differences in Predictors of HCC Incidence after DAA Therapy in Patients with HCV

¹Department of Gastroenterology and Metabology, Ehime University Graduate School of Medicine, Ehime, Japan

Takao Watanabe¹, Yoshio Tokumoto¹, Atsushi Yukimoto¹, Yoshiko Nakamura¹, Yuki Okazaki¹, Kotaro Sunago¹, Yohei Koizumi¹, Osamu Yoshida¹, Masashi Hirooka¹, Masanori Abe¹, Yoichi Hiasa¹

Background: Hepatocellular carcinoma (HCC) has been shown to be a male-dominant cancer, irrespective of the etiology, with two to four times higher HCC rates in men. In this study, we evaluated sex-related differences in the predictors of development of HCC after direct-acting antiviral (DAA) therapy in patients with hepatitis C virus (HCV) infection.

Methods: DAA therapy was given to 1438 HCV patients (663 male, 775 female) without a history of HCC before DAA treatment. Sex differences in the HCC development rate and the factors contributing to HCC development after DAA therapy were investigated.

Results: Male patients had a significantly higher cumulative HCC incidence (log-rank test, $p=0.007$). On multivariate analysis, the FIB-4 index (HR=1.11; 95%CI 1.042-1.202, $p=0.002$) and post-treatment α -fetoprotein (AFP) levels (HR=1.11; 95%CI 1.046-1.197, $p=0.001$) were found to be independent factors that contributed to HCC development following DAA therapy in female patients, whereas only post-treatment AFP levels (HR=1.090; 95%CI 1.024-1.160, $p=0.007$) were an independent factor in male patients. The optimal post-treatment AFP cut-off value, which was set based on receiver operating characteristic curve analyses, was much higher in female (6.0 ng/mL) than in male (3.5 ng/mL) patients.

Conclusion: Post-treatment AFP levels are an independent predictor of HCC development after DAA therapy for HCV infection in both male and female patients. However, the cut-off values differ between the sexes. In male patients, HCC was seen in patients with relatively low post-treatment AFP levels, suggesting that more careful observation might be needed in such patients.

TACE with Cisplatin Versus Epirubicin for Hepatocellular Carcinoma, a Randomised Controlled Trial

¹Department of Digestive Surgery, Nihon University School of Medicine, Tokyo, Japan

Osamu Aramaki¹, Tadatoshi Takayama¹

Background: The optimum agent for Transarterial chemoembolisation (TACE) remains unclear. We compared the efficacy of TACE with cisplatin vs. epirubicin in patients with unresectable HCC.

Methods: This multicentre, randomised, phase 2/3 trial was performed. Patients with HCC, performance status 0 – 2, and Child – Pugh class A/B were randomised to receive TACE with cisplatin or epirubicin. The primary endpoint was overall survival. Tumour response was evaluated according to the RECIST criteria.

Results: Between 2008 and 2012, 455 patients were randomly assigned to undergo TACE with cisplatin ($n=228$) or epirubicin ($n=227$). Eleven were ineligible, and 444 were included in the full analysis. Twelve patients not receiving TACE were excluded, and 432 were included in the safety analysis set. In phase 2, disease control rates in cisplatin (91.7%) and epirubicin (91.8%) groups exceeded the predefined threshold of 70%, and the study proceeded to phase 3. After a median follow up of 32.7 months (IQR=15.3 – 49.3), median overall survival periods were 2.93 years (95% CI 2.60 – 3.79) and 2.74 years (95%CI 2.26 – 3.21), respectively (HR 0.90 [95% CI 0.71–1.15], $p=0.22$). Median times to treatment failure were 1.38 and 1.46 years (HR 1.09 [95% CI 0.88 – 1.35], $p=0.88$), response rates were 65.3% and 60.6% ($p=0.31$), and serious adverse event rates were 49.8% and 48.3% ($p=0.56$), respectively. No treatment-related deaths occurred in either group.

Conclusion: In our phase 2/3 randomised trial, cisplatin is not significantly superior to epirubicin in TACE for patients with HCC.

Real Impact of Tumor Marker AFP and PIVKA-II in Detecting Very Small Hepatocellular Carcinoma

¹Gastroenterological Center, Yokohama City University Medical Center, Yokohama, Japan ²Department of Gastroenterology, Tarao's Gastroenterological Clinic, Yokohama, Japan ³Department of Gastroenterology, Yokohama Municipal Citizen's Hospital, Yokohama, Japan ⁴Department of Clinical Research, National Hospital Organization Yokohama Medical Center, Yokohama, Japan ⁵Department of Gastroenterology, Yokohama City University Graduate School of Medicine, Yokohama, Japan

Akito Nozaki¹, Kazuo Tarao², Hirokazu Komatsu³, Tatsuji Komatsu⁴, Makoto Chuma¹, Kazuzhi Numata¹, Shin Maeda⁵

Background: In hepatocellular carcinoma (HCC), detection prior to growth beyond 2 cm are relevant as a larger tumor size is more frequently associated with microvascular invasion and/or satellites. To examine the impact of the tumor marker alpha-fetoprotein (AFP) or PIVKA-II in detecting very small HCC nodules (<2 cm in maximum diameter, Barcelona stage 0) in the large number of very small HCC. The difference in the behavior of these tumor markers in HCC development was also examined.

Methods: A total of 933 patients with single-nodule HCC were examined from 3 sites. They were subdivided into 394 patients with HCC nodules < 2 cm in maximum diameter and 539 patients whose nodules were > 2 cm. The rates of patients whose AFP and PIVKA-II showed normal values were examined.

Results: In the patients whose tumor was < 2 cm, 50.5% showed normal levels in AFP and 68.8% showed normal levels in PIVKA-II. In 36.4% of those patients, both AFP and PIVKA-II showed normal levels. The PIVKA-II-positive ratio was markedly increased with an increase in the tumor size. In contrast, the positivity in AFP was increased gradually and slowly.

Conclusion: More than one third of the patients with very small HCC nodule (< 2 cm in diameter, Barcelona stage 0) were dropped from the surveillance using the tumor markers AFP and PIVKA-II.

Bezafibrate Treatment is Associated with Reduced Risk for Development of HCC in Patients with PBC

¹Department of Medicine, Teikyo University School of Medicine, Tokyo, Japan ²The Third Department of Internal Medicine, Kansai Medical University, Osaka, Japan

Atsushi Tanaka¹, Kosuke Matsumoto¹, Toshinari Nakano², Junko Hirohara²

Background and Aims: Recently we demonstrated long-term efficacy of a combination treatment of ursodeoxycholic acid (UDCA) and bezafibrate (BZF) for patients with primary biliary cholangitis (PBC) in Japan. In the current study, we retrospectively investigated whether BZF treatment was associated with reduced risk for development of hepatocellular carcinoma (HCC) in patients with PBC.

Method: The Japanese PBC cohort was initiated in 1980 and updated almost every 3 years by the Intractable Hepato-Biliary Diseases Study Group. To date, 9,919 patients with PBC have been registered. In this study, we assessed development of HCC as an endpoint with multivariable Cox models. Baseline covariates adjusted for analyses included age, sex, diagnosis year (by 10 years), presence of symptom, bilirubin, alkaline phosphatase, albumin, and histological staging at diagnosis.

Results: After excluding 5,486 patients due to missing data, remaining 4,433 patients were enrolled. Mean age at diagnosis was 56.6, and 627 were male (14%). UDCA and BZF treatment was conducted in 4,124 (93%) and 648 (15%) patients, respectively. Follow-up period was 6.5 years, and development of HCC was observed in 92 patients (2.0%). After adjusting baseline covariates, Cox model demonstrated that BZF treatment was significantly associated with reduced risk for development of HCC (aHR 0.107, 95% CI 0.033-0.34, p<0.001). Other significant associations were observed in male gender, older years (by 10), elevated ALP, elevated bilirubin, decreased albumin, presence of any symptom, and advanced histology.

Conclusion: BZF treatment was significantly associated with reduced risk for development of HCC in patients with PBC.

Durability of SVR in GT3 and GT6 Patients Treated with SOF/VEL with/without RBV from China

¹Public Health Treatment of Guiyang, Guizhou Province, China

Huagang Xiong¹, Wang Mei¹, Yuedong Liang¹, Zhigang Yang¹, Jing Wang¹, Tan Li¹

Background: High SVR12 contributed to raise HCV elimination, however, it is essential to demonstrate persistence of the virologic response. SVR persistence in GT3 and GT6 who achieved SVR treated with SOF/VEL is scanty in China, especially GT3b patients because SOF/VEL was approved in China about 2 years

Objectives: To demonstrate persistence of SVR in GT3 and GT6 HCV patients who achieved SVR12 treated with SOF/VEL with/without RBV.

Methods: This is a retrospective observational study. Patients with or without cirrhosis who received SOF/VEL with/without RBV treatment for 12 weeks and achieved SVR following for 48 weeks. The SVR were analyzed at 12weeks,24weeks ,48weeks, respectively and incidence of HCC were evaluated at 48 weeks.

Results: 49 eligible participants were enrolled; All patients have intravenous drug addicts in the past years. Median age was 57 years, 40 (81.6%) were men, 21 (42.9%) patients were genotype 3, 18 (36.8%) of those were genotype 3b, 28 (57.1%) were genotype 6a. Baseline demographics are provided in the Table1. Overall, SVR was 93.8%, 3 patients have relapse (2 GT3 patients and 1GT 6a patients); 45 patients completed follow-up for 48 weeks. 97.7% (44/45) patients have sustained viral response at 48 weeks; none were treatment related or resulted in serious AE and death. No patients with or without cirrhosis developed HCC for 48 weeks of follow- up.

Conclusion: SOF/VEL with/without RBV has high persistence of SVR in HCV patients with GT3 and GT6 infection, even GT3b patients and incidence of HCC is rare following for 48 weeks.

Impact of Postoperative Complications on Survival of Hepatocellular Carcinoma Patients

¹Department of Digestive Surgery, Nihon University School of Medicine, Tokyo, Japan

Hisashi Nakayama¹, Tadatoshi Takayama¹

Background: The effect of postoperative complications including red blood transfusion (BT) on long-term survival for hepatocellular carcinoma (HCC) is unknown. The purpose of this study was to define the relationship between postoperative complications and long-term survival in patients with HCC.

Methods: Postoperative complications of 1010 patients who underwent curative liver resection for HCC were classified, and their recurrence-free survival (RFS) and cumulative overall survival (OS) were investigated.

Results: Any complications occurred in 404 patients (40%). Five-year RFS and 5-year OS in the complication group were 20% and 55%, respectively, significantly lower than the respective values of 30% ($p < 0.001$) and 65% ($p < 0.001$) in the no-complication group ($n=606$). Complications related to RFS were postoperative BT [Hazard ratio (HR): 1.726, 95% confidence interval (CI): 1.338-2.228, $p < 0.001$], pleural effusion [HR: 1.434, 95% CI: 1.200-1.713, $p < 0.001$] using Cox-proportional hazard model. Complications related to OS were postoperative BT [HR: 1.843, 95%CI: 1.380-2.462, $p < 0.001$], ascites [HR: 1.562, 95% CI: 1.066-2.290 $p = 0.022$], and pleural effusion [HR: 1.421, 95% CI: 1.150-1.755, $p = 0.001$].

Conclusions: Postoperative complications including BT and pleural effusion were factors associated with poor long-term survival.

Clinical Characteristics and Survival Analysis of Patients with HCC after HBV Negative

¹Shunde Hospital of Southern Medical University, Guangdong, China ²Shanxi Medical University ³Shanxi Cardiovascular Research Institute
⁴Ditan Hospital of Capital Medical University

Hong Li¹, Wenmin Guo², Qian Xie³, Xiu Sun⁴, Yanteng Wang²

Objective: To analyze the clinical characteristics and survival time of hepatocellular carcinoma (HCC) occurrence in patients with hepatitis B virus (HBV) infection after virus negative transformation.

Methods: The Kaplan-Meier and Log-rank survival analysis were performed to compare the overall survival of the patients with HCC in different groups.

Results: The 1-, 3- and 5-year OS rates of the 104 investigated patients were 76.4%, 54.4% and 20.5%, respectively. Their median survival was 37 months. The median survival time of HBV-DNA negative group was longer than that of positive group (negative vs. positive: 42 vs. 36, $P=0.003$). The 5-year OS rate of patients received antiviral therapy before HCC diagnosis in HBV-DNA negative group than that in positive group (negative vs. positive: 53.0% vs. 0%, $P=0.022$). There was no significant difference in the 5-year OS rate for patients who had no antiviral therapy before diagnosis of HCC between HBV-DNA negative and positive group ($P=0.195$).

Conclusion: Among HBV-infected patients, a significant proportion of virus-negative patients develop liver cancer and require long-term continuous monitoring. Long-term effective antiviral therapy can improve the long-term survival rate of patients with liver cancer. This study revealed important clinical characteristics of HCC patients and provided useful information for their clinical management and monitoring.

Keywords: Hepatitis B virus (HBV); HBV-DNA; Hepatocellular carcinoma (HCC); Survival rate

Immune Checkpoint Inhibitor as a Therapeutic Choice for Double Cancer: A Case Series

¹Division of Gastroenterology and Hepatology, Department of Medicine, Nihon University School of Medicine

Naoki Matsumoto¹, Hiroshi Aoki¹, Hiroshi Takahashi¹, Masayuki Honda¹, Tomohiro Kaneko¹, Shuhei Arima¹, Tomotaka Ishii¹, Taku Mizutani¹, Ryota Masuzaki¹, Kazushige Nirei¹, Hiroaki Yamagami¹, Masahiro Ogawa¹, Tatsuo Kanda¹, Mitsuhiko Moriyama¹

Background: Hepatocellular carcinoma (HCC) occasionally presents with simultaneous or metachronous primary malignancies of other organs. Despite the limited scope of cytotoxic anticancer drugs or molecular targeted agents, immune checkpoint inhibitors (ICIs) can still be used for various malignancies. Here, we present cases of double cancers including HCC treated with ICIs.

Case Reports: Case 1: A 70-year-old man with lung cancer and 80-mm HCC underwent nivolumab therapy. The sizes of both cancers remained constant for nine months. Case 2: A 58-year-old man with pharyngeal cancer and HCC. Nivolumab was administered, but was withdrawn after one session because of progressive disease. Case 3: A 71-year-old man with a 5 cm HCC invading the inferior vena cava, and early esophageal cancer. HCC showed a significant volume reduction and esophageal cancer demonstrated slight improvement by atezolizumab and bevacizumab therapy.

Conclusion: A combination therapy including ICI is a promising treatment option for HCC with concurrent malignancies.

Characteristics of Genomic Profile of Hepatocellular Carcinoma after Sustained Virologic Response

¹Department of Gastroenterology, Chiba University Hospital ²Department of Gastroenterology, Teikyo University Chiba Medical Center
³Genome Analysis Center, Yamanashi Central Hospital ⁴Department of Surgery, Yamanashi Central Hospital ⁵University of Tokyo, Japan
Hiroshi Ohyama¹, Shuntaro Obi², Yoshihiko Ooka¹, Yosuke Hirotsu³, Kenji Amemiya³, Yuji Jimuro⁴, Hitoshi Mochizuki³, Naoya Kato¹, Masao Omata^{3,5}

Objectives: With the advent of direct acting antivirals (DAAs), many cases of chronic hepatitis C have achieved sustained virologic response (SVR), and hepatocellular carcinoma (HCC) has been decreasing. However, HCC after SVR has been reported. In this study, we analyzed the genomic profiles of synchronous and metachronous HCC occurred before and after DAA treatment to clarify the carcinogenesis patterns.

Materials and Methods: We prospectively followed up 612 consecutive patients who achieved SVR after DAA treatment from July 2013 to June 2020. DNA was extracted from HCC, and genomic analysis was performed using an in-house 72-gene panel of 285,470 nucleotides related to HCC. Mutations were annotated by OncoKB to identify oncogenic and actionable mutations. Carcinogenesis patterns were diagnosed by comparing the genomic profiles.

Results: Of the 612 patients, 48 (8%) had HCC. Among these, we studied 8 nodules in 3 patients who had HCC before DAA treatment and 16 nodules in 7 patients who did not have HCC before DAA treatment. Of 24 nodules in 10 cases, 454 mutations were detected. Of these, 51 were oncogenic. In addition, 7 actionable mutations were detected. Only 2 nodules in 1 patient which occurred before DAA treatment were intrahepatic metastasis, but the remaining 22 nodules in 9 patients which occurred after DAA treatment were multicentric origin.

Conclusion: Analysis of carcinogenesis patterns by genomic profiling showed that all HCC after DAA treatment was multicentric origin. In addition, actionable mutations can be detected, suggesting the possibility of a therapeutic strategy based on genomic profiles.

Impact of Hepatectomy for Advanced Hepatocellular Carcinoma with Major Portal Vein Tumor Thrombus

¹Department of Surgery, Division of Hepato-Biliary-Pancreatic Surgery, Kobe University Graduate School of Medicine, Japan
Shohei Komatsu¹, Masahiro Kido¹, Takumi Fukumoto¹

Background: The present study aimed to assess the impact and prognostic factors of hepatectomy for hepatocellular carcinoma (HCC) with macroscopic portal vein tumor thrombus (PVTT).

Methods: One hundred patients with PVTT extending to the first portal branch (Vp3), main portal trunk, or opposite side portal branch (Vp4) confirmed with intraoperative findings were included. Postoperative outcomes and prognostic factors for survival were evaluated.

Results: The median survival time (MST) of all patients with Vp3/4 PVTT was 14.5 months, and 1- and 3- year overall survival rates were 59.6% and 16.8%, respectively. The MSTs of patients with Vp3 and Vp4 were 16.1 and 14.3 months, respectively ($P = 0.7098$). The MST of patients who underwent curative and reductive hepatectomy were 14.3 and 14.9 months, respectively ($P = 0.3831$). Any tumor factor, including Vp status, the type of resection (curative or reductive), intrahepatic maximal tumor size, intrahepatic tumor number, and the existence of extrahepatic metastasis, did not influence survival.

Conclusions: Hepatectomy for HCC with Vp3/4 PVTT can be an effective treatment option. Any tumor factor has a small impact on survival under the powerful tumor factor of Vp3/4 PVTT, indicating that surgical indication can be considered irrespective of the tumor factors.

Major Signaling Pathway in Hepatocellular Carcinoma and Drug-matched Variants

¹Genome Analysis Center, Yamanashi Central Hospital, Yamanashi, Japan ²Department of Gastroenterology, Yamanashi Central Hospital
³Department of Gastroenterology, The University of Tokyo, Japan

Kenji Amemiya¹, Yosuke Hirotsu¹, Masao Omata^{2,3}

Aim: Genetic analysis has revealed abnormalities in intracellular signaling pathways in hepatocellular carcinoma (HCC), and signaling pathway-oriented therapies are getting important. We performed targeted sequencing to identify gene alterations and dysregulated pathways in HCC. And we searched for drug-matched alterations.

Methods: 90 patients, 163 nodules and 195 samples were collected. DNA was extracted from tumor FFPE (Formalin-fixed paraffin embedded) tissues by laser capture microdissection (LCM). Next generation sequencing was performed using the HCC Comprehensive Panel (72SMGs: 59016 aa), which contains genes involved in the Wnt/beta catenin pathway, TP53/cell cycle pathway, PIK3CA/RAS pathway, Chromatin Remodeling pathway, and Oxidative Stress pathway, which are major pathways in hepatocarcinogenesis. Oncogenicity and drug-matched alternation were confirmed using the OncoKB database (<https://www.oncokb.org/>).

Results: Oncogenic variants were found in 36 nodes (28%) of the Wnt/beta catenin pathway, 54 nodules (42%) of the TP53/cell cycle pathway, 9 nodules (7%) of the PIK3CA/RAS pathway, 24 nodules (19%) of the Chromatin Remodeling pathway, and 5 nodules (4%) of the Oxidative Stress pathway. Drug-matched variants were found in 8 genes in 21 patients (23%) and 26 nodes in 28 samples. 11 patients with multiple HCC did not share the drug matched alternation, as each tumor had a different genetic profile.

Conclusions: The TP53/cell cycle pathway and Wnt/beta catenin pathway were the major pathways in HCC. Drug-matched variants are different for each tumor in multiple HCC cases, and genetic analysis for each tumor is necessary for precision therapy.

Clinical Trend of Japanese Patients with HCC in Progression of Aging Society: Clinical Role of RFA

¹Gastroenterology Center, Ehime Prefectural Central Hospital, Matsuyama, Japan ²Ehime University Graduate School of Medicine, Department of Gastroenterology and Metabology, Toon, Japan

Shota Izumi¹, Atsushi Hiraoka¹, Takaaki Tanaka¹, Takeaki Yoshino¹, Hidetaro Ueki¹, Shogo Kitahata¹, Tomonari Okudaira¹, Toshihiko Aibiki¹, Tomoe Kawamura¹, Taira Kuroda¹, Hiroka Yamago¹, Yoshihumi Suga¹, Tomoyuki Ninomiya¹, Yoichi Hiasa²

Background: Progression of aging society has become a great clinical issue worldwide. We investigated the clinical feature of Japanese hepatocellular carcinoma (HCC) patients and efficacy and safety of radio frequency ablation (RFA) as a low invasive treatment.

Methods: From January 2000 to September 2021, 1945 HCC patients were diagnosed and treated in our hospital. Patients were divided into 4 groups according to age (Group A:B:C:D = <65 years, 65-74 years, 75-79 years, >80 years). Of the 1945, 601 patients who treated with RFA as initial treatment were analyzed to evaluate survival after RFA and clinical characteristics, retrospectively.

Results: Frequency of Group D has become larger and larger, recently (7% to 22%), and frequency of non-viral HCC has been increased (9% to 30%). In the 601 patients treated with RFA (size 1.9 ± 0.7 cm, number 1.3 ± 0.6), Child-Pugh classification, TNM stage, and AFP elevation (>100 ng/ml) were not significantly different among the 4 groups. The median survival time (MST) was 95, 92, 82, and 50 months in groups A, B, C, and D ($P < 0.001$). After exclusion of patients with performance status 2 or more, the MST results for each group were similar (A:B:C:D=74:78:69:46 months, $P < 0.001$). Although MST of Group D was shorter, complication rates were no significant difference among the 4 groups and liver related death rate was smaller than the others in the group D ($P < 0.001$).

Conclusion: Rapid progression of aging society is observed in Japanese HCC patients. RFA can play a role for avoiding liver related death in elderly patients.

Clinical Features of Systemic Treatment in Japan

¹Gastroenterology Center, Ehime Prefectural Central Hospital, Matsuyama, Japan ²Department of Gastroenterology and Metabolism, Ehime University Graduate School of Medicine, Ehime, Japan

Takaaki Tanaka¹, Atsushi Hiraoka¹, Syota Izumi¹, Masaya Kato¹, Hirohumi Izumoto¹, Hidetaro Ueki¹, Takeaki Yoshino¹, Syogo Kitahata¹, Toshihiko Aibiki¹, Tomonari Okudaira¹, Tomoe Kawamura¹, Taira Kuroda¹, Hiroka Yamago¹, Yoshifumi Suga¹, Tomoyuki Ninomiya¹, Masashi Hirooka², Yoichi Hiasa²

Background/Aim: After development of sorafenib for unresectable hepatocellular carcinoma (uHCC), 6 regimens have become to be available in Japan and it has been well known that better hepatic function is requirements for use multi-line treatment. This study aimed to elucidate the changes of outcomes according to period of introducing initial systemic treatment.

Materials/Methods: From 2009 to 2021, 192 uHCC patients treated with systemic treatment were enrolled (70.2±1.5 years old, HBV/HCV/Alcohol/Others=22/113/2/16/39, mALBI grade 1:2a:2b:3=88:52:49:3, Initial treatment: Sorafenib/Lenvatinib/tezolizumab&Bevacizumab/Other immune-checkpoint inhibitor=140/30/12/10). Patients were divided into 1st as single regimen era (~2016: N=97), 2nd as multiple regimens era within 3 regimens (2017-2018: N=38), and 3rd period as 4 or more regimens era (2019~: N=57). The overall survival (OS) and clinical features were examined retrospectively.

Results: Median OS have become better and better with increasing regimens [Period 1st vs. 2nd vs. 3rd=14.9 vs. 16.1 vs. 21.4 months (P<0.05)], while those according to mALBI grade have become worse with mALBI grade decline [grade 1 vs. 2a vs. 2b vs. 3=24.1 vs. 16.1 vs. 11.1 vs. 8.6 months (P<0.05)]. After 2nd period (multiple regimen available era), patients treated with larger number of lines showed better prognosis (median OS: single vs. 2 vs. 3 or more lines=9.1 vs. 13.6 vs. 23.0 months, P<0.05).

Conclusions: In comparison with the 1st period, prognoses have become better and better with increasing regimens. For prolonging prognosis, introducing initial systemic treatments in uHCC patients with good liver reserve, as possible, should be kept in mind to use multiple lines.

Hepatoma-derived Growth Factor as a Potential Therapeutic Target for Hepatocellular Carcinoma

¹Division of Hepatobiliary and Pancreatic Medicine, Department of Internal Medicine, Hyogo College of Medicine, Hyogo, Japan

Hirayuki Enomoto¹, Hideji Nakamura¹, Tomoyuki Takashima¹, Nobuhiro Aizawa¹, Naoto Ikeda¹, Yukihisa Yuri¹, Aoi Fujiwara¹, Kohei Yoshihara¹, Ryota Yoshioka¹, Shoki Kawata¹, Shogo Ota¹, Ryota Nakano¹, Hideyuki Shiomi¹, Takashi Nishimura¹, Shuhei Nishiguchi¹, Hiroko Iijima¹

Background: HDGF (Hepatoma-derived growth factor) is a growth factor which is involved in the progression of HCC. We have reported that HDGF is highly expressed in the HCC tissues, and the expression level of HDGF is an independent prognostic factor for the disease-free and overall survival in patients with HCC. The purpose of this study is to examine whether HDGF can be a potential target molecule for the treatment of HCC.

Methods: (1) We generated the stably HDGF-overexpressed or HDGF-silenced hepatoma cell lines by the introduction of HDGF cDNA or sh-RNA, and examined the effects of the increased or reduced HDGF expression on the proliferation of hepatoma cells. (2) We investigated the effects of the exogenous and endogenous overexpression of HDGF on the proliferation and tubular formation of HUVEC (human umbilical vein endothelial cells) in vitro. (3) We examined whether the introduction of HDGF cDNA can induce the VEGF expression.

Results: (1) Introduction of HDGF cDNA stimulated the proliferation of hepatoma cells, whereas reduction of HDGF by sh-RNA suppressed the growth of the hepatoma cells. (2) Administration of recombinant HDGF significantly increased the cellular number of HUVEC in vitro, and HDGF-treated HUVEC formed longer vessel-like tubes in vitro than those formed by PBS-treated control cells. (3) HDGF induced VEGF expression through the activation of the VEGF promoter.

Conclusions: HDGF functions as a growth stimulating factor on hepatoma cells and the other as an angiogenic factor. HDGF is therefore considered to be a possible target molecule for the treatment of HCC.

Surgical Resection for Hepatocellular Carcinoma with Major Vascular Invasion

¹Department of Digestive Surgery, Nihon University School of Medicine, Japan
Shintaro Yamazaki¹, Yukiyasu Okamura¹, Tokio Higaki¹, Tadatoshi Takayama¹

Aim: Major portal vein invasion (MVI) of hepatocellular carcinoma (HCC) is known as a poorest prognostic factor. Our aim is to clarify the indication of hepatic resection for presence of major portal vein invasion of HCC.

Methods: Between 2001 and 2015, the 1,306 patients (866 hepatic resection and 440 transarterial therapy) undergoing primary treatment for HCC were analyzed. The significant prognostic factor was identified by analyzing the tumor status, liver functional and treatment. The overall survival were compared on the basis of the degree of vascular invasion and treatment.

Results: The 5-year survival rates according to the degree of vascular invasion (Vp) were Vp0; 59.3%, [95%CI: 0.56-0.63], Vp1; 43.2% [0.36-0.51], Vp2; 19.0%, [0.01-0.34], Vp3; 12.5%, [0.13-0.35] and Vp4; 0% respectively. In major vascular invasion in patients with Vp3 and Vp4 the overall survival (OS) did not differ significantly ($p=0.153$). The median survival of the Vp3 is significantly better than that in the Vp4 in hepatic resection (1,913 days vs. 258, $p=0.001$) while did not differ significantly in transarterial therapy (164 days vs. 254, $p=0.137$). The multivariate analysis revealed performing hepatic resection (Odds: 2.335 [95%CI: 1.236-4.718], $p=0.008$) and multiple tumor (1.698 [1.029-2.826], $p=0.038$) were the independent predictors for survival.

Conclusions: The indication for radical hepatic resection of MVI in HCC is less than Vp3 comparing to transarterial therapy.

The Cancer Risk in PSC and Ulcerative Colitis from 26 Years Retrospective Cohort Study in Japan

¹Department of Gastroenterology, Graduate School of Medicine, Chiba University, Chiba, Japan ²Department of Gastroenterology, Kimitsu Chuo Hospital ³Department of Gastroenterology, Chiba Prefectural Sawara Hospital, Japan

Takashi Taida¹, Junichiro Kumagai², Sadahisa Ogasawara¹, Tatsuya Kaneko¹, Hiroki Nagashima¹, Kengo Kanayama¹, Naoki Akizue¹, Koji Takahashi¹, Yuki Ohta¹, Kenichiro Okimoto¹, Hiroshi Ohyama¹, Keiko Saito¹, Yuko Kusakabe¹, Tomoaki Matsumura¹, Harutoshi Sugiyama¹, Izumi Ohno¹, Rintaro Mikata¹, Toshio Tsuyuguchi³, Jun Kato¹, Naoya Kato¹

Background: Primary sclerosing cholangitis (PSC) is well-known as the risk of cholangiocarcinoma. In Western countries, most patients with PSC have concurrent ulcerative colitis (UC). The incidence of UC in East Asia has been increased markedly over the past two decades. However, current clinical features of PSC and of PSC associated with UC (PSC-UC) have not yet been clarified in East Asia. We aimed to reveal the clinical trends of PSC complication in UC and associations with cholangiocarcinoma in Japanese patients.

Methods: We retrospectively analyzed 69 patients with PSC and 1242 UC who were diagnosed at Chiba University Hospital between June 1991 and August 2017.

Results: In the present cohort, 37 patients had PSC-UC; the cumulative risks of PSC in UC and of UC in PSC were 3.0% and 53.6%, respectively. We confirmed that the number of patients with young-onset PSC-UC was increasing similar to an increase in patients with UC. Among 69 PSC patients, eleven (15.9%) patients had cholangiocarcinoma. Meanwhile, there were 4 (10.8%) patients with cholangiocarcinoma in PSC-UC. In UC cohorts, the risk of cholangiocarcinoma was significantly increased with PSC complication.

Conclusions: In our cohort, the comorbidity rate of PSC-UC was higher than that obtained in previous reports. In the rapidly increasing number of UC cases in Asian countries, attention should be paid to the risk of PSC complications and the subsequent development of cholangiocarcinoma.

Safety of Atezolizumab plus Bevacizumab in Hepatocellular Carcinoma

¹Department of Gastroenterology, Aomori Prefectural Central Hospital, Aomori, Japan ²Department of Gastroenterology, Hirosaki University School of Medicine, Hirosaki, Japan

Hiroshi Numao¹, Koji Shimaya², Syo Suto², Kaede Miyashiro², Syohei Igarashi², Miwa Satake², Norihiro Hanabata^{1,2}, Kosuke Kanazawa¹, Masaki Munakata¹

Background: Atezolizumab-Bevacizumab (Atezo-Beva) are newly introduced chemotherapy drugs for unresectable hepatocellular carcinoma (HCC). In this study, we aimed to study the adverse events of Atezo-Beva in a real-world setting.

Methods: All the patients who initiated Atezo-Beva therapy in our hospital between November 2020 and September 2021 were included. Safety was evaluated by vital signs, and clinical laboratory test results, and assessment of the incidence and severity of adverse events according to CTCAE.

Results: Of the 29 patients included in this study, 25 (86%) were males with a median age of 72 years, and the median observation period was 12 weeks. Fourteen patients (48%) were classified as BCLC stage B, and 15 patients (52%) as BCLC stage C. Only four patients (14%) were administered Atezo-Beva as first-line therapy and the other patients had been treated previously mainly by transarterial chemoembolization (59%) and/or tyrosine kinase inhibitors (TKIs, 52%). The most common adverse events were fatigue (55%), anorexia (31%), and proteinuria (31%); grade ≥ 2 adverse events occurred in 24 patients (83%), with the most frequently being proteinuria (24%), and hypertension (21%). Four patients discontinued Atezo-Beva due to adverse events, specifically, exacerbation of psoriasis, ALT level elevation, epistaxis, and fatigue. In seven patients (24%), dose modification or discontinuation of Beva was required due to proteinuria and four of them were previously administered TKIs. No treatment-related deaths occurred.

Conclusions: In a real-world Atezo-Beva therapy for HCC, proteinuria was the most frequent grade ≥ 2 adverse event and was a determinant factor for Beva administration.

Impact of Patient Age on Outcome after Resection for Hepatocellular Carcinoma

¹Department of Digestive Surgery, Nihon University School of Medicine, Japan

Masaharu Harada¹, Osamu Aramaki¹, Tadatoshi Takayama¹

Background: There is little information on the impact of aging on liver resection of hepatocellular carcinoma (HCC). The aim of study was to evaluate the prognostic impact of the patient's age on the long-term survival after resection of HCC caused mainly by HCV.

Methods: The postoperative outcomes of the 291 elderly (≥ 70 years) and 340 younger (< 70 years) patients underwent curative liver resection for HCC were analyzed using multivariate and propensity-score matching.

Results: There was no significant difference in recurrence free survival between the two groups ($p = 0.24$). The overall survival rate was significantly lower in the elderly group than that in the younger group ($p = 0.01$). Propensity score matching analysis yielded 234 pairs of patients. After matching, there were no significant differences were found in recurrence free survival ($p = 0.42$) or overall survival ($p = 0.23$) between the two groups.

Conclusion: Advanced age does not have a significant impact on the outcomes of patients after resection of HCC.

Iron Chelator Deferasirox Alters Sorafenib-induced Programmed Cell Deaths of Hepatoma Cells

¹Department of Clinical Medical Sciences, International University of Health and Welfare Graduate School of Medicine, Tokyo, Japan
²Department of Gastroenterology, International University of Health and Welfare School of Medicine, Narita, Japan ³Department of Gastroenterology and Hepatology, International University of Health and Welfare Hospital, Nasushiobara, Japan
Wataru Jomen¹, Takaaki Ohtake^{2,3}, Takayuki Akita^{1,3}, Daisuke Suto^{2,3}, Yosuke Osawa^{1,2,3}, Yutaka Kohgo^{1,2,3}

Background: The improvements of antitumor effects and tolerability on chemotherapy for advanced HCC are warranted. The aim of this research is to elucidate the mechanism of the combination effect of TKI Sorafenib (SOR) and iron chelator Deferasirox (DFX), by investigating the type of programmed cell deaths (PCDs) and NF- κ B signaling using human hepatoma cell lines.

Methods: HepG2 and Huh-7 were used to evaluate inhibitory effects of SOR and/or DFX. The expression of NF- κ B was quantified by Western blot. Human cleaved caspase-3 was analyzed by ELISA for apoptosis, GSH assay was used for ferroptosis. PCDs inhibition was analyzed by adding apoptosis inhibitor Z-VAD-FMK, ferroptosis inhibitor ferrostatin-1, necroptosis inhibitor necrosulfonamide.

Results: SOR+DFX combination showed additive antitumor effects. In each monotherapy, and SOR+DFX combination, the expression of NF- κ B was suppressed. In SOR monotherapy, cleaved caspase-3 expression was increased up to 5 μ M, but it was decreased at 10 μ M. In SOR monotherapy, GSH/GSSG ratio was increased on concentration-dependent, showing SOR induced ferroptosis. In DFX monotherapy, it was decreased. In Fluorescence Microscopy of SOR, apoptosis was induced at a constant rate on low concentration, while necroptosis and ferroptosis were increased on high concentration. Lipid Peroxidation caused by SOR, corresponding to ferroptosis, was suppressed by DFX. In SOR+DFX combination, antitumor effects were not suppressed by ferrostatin-1, but suppressed by Z-VAD-FMK and necrosulfonamide.

Conclusion: Promising results about the additive effect of DFX on SOR therapy were obtained. Regarding PCD by SOR+DFX combination, ferroptosis was suppressed and both apoptosis and necroptosis became dominant. Suppression of NF- κ B expression is possibly involved about the effect of DFX.

Levocarnitine Suppresses Lenvatinib-related Sarcopenia in Hepatocellular Carcinoma Patients

¹Department of Gastroenterology, Juntendo University Nerima Hospital, Tokyo, Japan ²Department of Cellular and Molecular Function Analysis, Kanazawa University Graduate School of Medical Sciences, Ishikawa, Japan ³Department of Gastroenterology, Juntendo University School of Medicine, Tokyo, Japan

Hironao Okubo¹, Hitoshi Ando², Eisuke Nakadera¹, Kenichi Ikejima³, Shuichiro Shiina³, Akihito Nagahara³

This retrospective study aimed to investigate the inhibitory effect of levocarnitine supplementation on sarcopenia progression and the serum carnitine homeostasis in patients with hepatocellular carcinoma (HCC) using lenvatinib. Consecutive 77 patients with HCC treated with lenvatinib were enrolled. We evaluated skeletal muscle index (SMI) using computed tomography. The decision for sarcopenia were taken from the Japan Society of Hepatology. Cases and controls were propensity matched for age, sex, modified albumin-bilirubin grade, the presence of sarcopenia at baseline, and with or without branched-chain amino acids administration. In total, 34 patients were identified; 17 patients received levocarnitine supplementation (1500mg per day) after the start of treatment and 17 propensity score matched patients did not receive. Sarcopenia was present in 76% of patients at the baseline. Changes in SMI at baseline to six weeks and three months were significantly suppressed in the group with levocarnitine supplementation compared with those without ($P=0.009$, $P=0.018$, respectively). While there were no significant differences in serum free carnitine (FC) of cases without levocarnitine supplementation between baseline and six weeks ($P=0.193$), serum FC of cases with levocarnitine supplementation on six weeks was significantly higher compared with the baseline FC ($P<0.001$). The baseline SMI was significantly correlated with baseline serum FC ($r=0.359$, $P=0.037$) and the change in SMI from baseline to six weeks was significantly correlated with changes in serum FC ($r=0.345$, $P=0.045$). Serum FC level might be correlated with skeletal muscle volume and levocarnitine supplementation could suppress sarcopenia progression during the lenvatinib therapy for HCC.

Two Cases of RFA for HCC in the Caudate Lobe; An Emerging Technique with Using Guided Needle under CT

¹Department of Gastroenterology, Graduate School of Medicine, Chiba University, Japan

Sae Yumita¹, Naoya Kanogawa¹, Takafumi Sakuma¹, Naoto Fujita¹, Ryuta Kojima¹, Hiroaki Kanzaki¹, Keisuke Kojima¹, Kazufumi Kobayashi¹, Masato Nakamura¹, Soichiro Kiyono¹, Takayuki Kondo¹, Tomoko Saito¹, Ryo Nakagawa¹, Sadahisa Ogasawara¹, Shingo Nakamoto¹, Ryosuke Muroyama¹, Tetsuhiro Chiba¹, Naoya Kato¹

Background: In radiofrequency ablation (RFA) of hepatocellular carcinoma, lesions in the caudate lobe are known to be one of the most difficult to treat. We report two cases of complete ablation of lesions in the caudate lobe by RFA using a metal external cylinder needle. Case1: A patient was 64-year-old male with alcoholic cirrhosis. A lesion in the caudate lobe (32x27mm) was treated with CT-guided RFA (right intercostal approach). But the ablation was insufficient, so CT-guided RFA with a metal external cylinder needle was performed. The procedure is as follows. (1) A 14G metal external cylinder needle is inserted into the abdominal cavity under ultrasonography guidance from the cardiac fossa. (2) Remove the internal needle and guide it to the caudate lobe. (3) CT scan is performed to confirm the needle tip. (4) Insert the 17G electrode needle into the outer tube needle and puncture the tumor under CT guidance. (5) ablation. Case2: A patient was 83-year-old male with hepatitis C virus. A lesion in the caudate lobe (16x15mm), we performed RFA with this technique. But the safety margin was insufficient on CT after ablation, the position of a metal external cylinder needle was adjusted and additional cauterization was performed by re-puncture. Both Case1 and 2 have been under follow-up for more than one year without local recurrence.

Conclusion: Puncture of lesions in the caudate lobe using a metal external cylinder needle is a useful and safety method.

Incidence of HCC is Quite Different Depending on the History of HCC; A Prospective Study by 600 SVRs

¹Department of Gastroenterology, Yamanashi Central Hospital ²Internal medicine, Teikyo University Chiba Medical Center, Chiba, Japan ³Gastroenterology, Chiba University, Chiba, Japan ⁴Genome Analysis Center, Yamanashi Central Hospital, Yamanashi, Japan ⁵University of Tokyo, Tokyo, Japan

Shuntaro Obi^{1,2}, Miho Kanda¹, Hiroshi Ohyama^{1,3,4}, Hitoshi Mochizuki^{1,4}, Yuichiro Kojima¹, Yoji Suzuki¹, Kazuhiko Hosoda¹, Sumio Hirose¹, Yukiko Asakawa¹, Hiroyuki Amano¹, Kyoko Nakajima¹, Akinori Abe¹, Masao Omata^{1,4,5}

Aim: Oral preparation of anti HCV drug completely changed the paradigm of Hepatology. We prospectively observed HCC carcinogenesis after SVR in a single center.

Methods: We enrolled 611 patients who achieved SVR after DAA (Direct Acting Antiviral) between 2013 and 2020. Of the 611 patients, 34 (6%) had a history of HCC prior to DAA treatment. The remaining 578 patients had no history of HCC. These patients were prospectively observed for development of HCC.

Results: SVR was achieved in all 611 patients. The items of DAA were Sofosbuvir n=180, Sofosbuvir + Ledipasvir n=401, Glecaprevir + Pibrentasvir n=19, Elbasvir + Grazoprevir n=7, Daclatasvir + Asunaprevir n=3, Sofosbuvir + Velpatasvir n=1. The mean observation period for all 611 patients was 3.6 years, and HCC development was observed in 47 patients (8%) during follow-up, the rate was 2.1 per 100 person-years. By history of HCC, 21 of 34 patients with history positive had HCC development (62%), the rate was 43.9 per 100 person-years. On the other hand, 26 of 577 patients with no history of HCC showed HCC carcinogenesis (5%), the rate was 1.2 per 100 person-years. A history of HCC was associated with a significantly higher rate of HCC carcinogenesis.

Conclusion: A prospective study showed an overall incidence of 2.1 cancers per 100 person-years. The rate was 43.9 per 100 person-years of carcinogenesis, especially in the patients with a history of HCC. Patients with a history of HCC need to be followed up with close attention to HCC carcinogenesis.

Beware of Carcinogenesis Other Than HCC; A Prospective Study by 600 SVRs

¹Department of Gastroenterology, Yamanashi Central Hospital ²Internal medicine, Teikyo University Chiba Medical Center, Chiba, Japan. ³Gastroenterology, Chiba University, Chiba, Japan. ⁴Genome Analysis Center, Yamanashi Central Hospital, Yamanashi, Japan. ⁵University of Tokyo, Tokyo, Japan.

Shuntaro Obi¹, Miho Kanda¹, Hiroshi Ohyama^{1,3,4}, Hitoshi Mochizuki^{1,4}, Yuichiro Kojima¹, Yoji Suzuki¹, Kazuhiko Hosoda¹, Sumio Hirose¹, Yukiko Asakawa¹, Hiroyuki Amano¹, Kyoko Nakajima¹, Akinori Abe¹, Masao Omata^{1,4,5}

Aim: Oral preparation of anti HCV drug completely changed the paradigm of Hepatology. We prospectively observed ALL CANCER carcinogenesis after SVR.

Methods: We enrolled 611 patients who achieved SVR after DAA between 2013 and 2020. Of the 611 patients, 34 (6%) had a history of HCC prior to DAA treatment. The remaining 578 patients had no history of HCC. The patient was prospectively observed for develop of ALL Malignant Tumor.

Results: The mean observation period for all 611 patients was 3.6 years. The incidence of all malignancies was 80 (13%), and the rate was 3.6 per 100 person-years. Of these, HCC development was observed in 47 patients (8%) during follow-up, the rate was 2.1 per 100 person-years. On the other hand, the incidence of malignancies other than HCC was 32 cases (5%), or 1.4 per 100 person-years. By age (<75 years vs. 75 years and older), the overall cancer rate was 3.0 vs. 5.6 per 100 person-years. HCC carcinogenesis was 1.9 vs. 3.0, and malignancies other than HCC was 1.1 vs. 2.6.

Conclusion: A prospective study showed an overall incidence of 3.6 all malignant tumors per 100 person-years. It turns out that malignant tumors other than HCC also occur. In particular, the incidence of carcinogenesis was 2.5 times higher in patients over 75 years of age compared to those under 75 years of age. In the follow-up after SVR in the elderly, one should also be aware of carcinogenesis other than HCC.

Risk Factors for Occurrence of HCC after DAA Therapy; A Prospective Study by 600 SVRs

¹Department of Gastroenterology, Yamanashi Prefectural Central Hospital ²Internal medicine, Teikyo University Chiba Medical Center, Chiba, Japan ³Gastroenterology, Chiba University, Chiba, Japan ⁴Genome Analysis Center, Yamanashi Central Hospital, Yamanashi, Japan ⁵University of Tokyo, Tokyo, Japan

Shuntaro Obi¹, Miho Kanda¹, Hiroshi Ohyama^{1,3,4}, Hitoshi Mochizuki^{1,4}, Yuichiro Kojima¹, Yoji Suzuki¹, Kazuhiko Hosoda¹, Sumio Hirose¹, Yukiko Asakawa¹, Hiroyuki Amano¹, Kyoko Nakajima¹, Akinori Abe¹, Masao Omata^{1,4,5}

Aim: Oral preparation of anti HCV drug completely changed the paradigm of Hepatology. We prospectively observed HCC carcinogenesis after SVR. The aim of this study was to identify the risk factors for liver carcinogenesis based on the clinical background of patients who achieved SVR after DAA treatment.

Methods: We enrolled 611 patients who achieved SVR after DAA between 2013 and 2020. Of the 611 patients, 34 (6%) had a history of HCC prior to DAA treatment. The remaining 578 patients had no history of HCC. These patients were prospectively observed for development of HCC. The various clinical backgrounds were compared between HCC and non-HCC cases.

Results: The mean observation period for all 611 patients was 3.6 years. The incidence of HCC development was observed in 47 patients (8%) during follow-up. When comparing HCC carcinoma cases with non-carcinoma cases, age (71 vs. 65 p=0.001), HCV genotype 1 (39/48 vs. 351/562 p=0.009), previous liver cancer (21/48 vs. 13/563 p<0.001), Fibro-scan value at initial diagnosis (21.2KPa vs. 10.6KPa p<0.001) were statistically significant. In multivariate analysis, previous hepatocellular carcinoma (OR 23.5, 95%CI 9.2-60.3, p<0.001), Fibro-scan >11.8KPa at first visit (OR 13.9 95%CI 5.4-35.5, p<0.001), HCV genotype 1 (OR 2.6, 95%CI 1.0-6.9, (OR 2.6, 95%CI 1.0-6.9, p=0.045) were significant risk factors for carcinogenesis.

Conclusion: In SVR patients treated with DAA, a history of hepatocellular carcinoma, high Fibro-scan at initial diagnosis, and HCV genotype 1 were found to be high risk factors for hepatocarcinogenesis.

Laparoscopic Surgery could be Most Frequently Employ as a Treatment for HCC in SVR Era

¹Department of Gastroenterology, Yamanashi Central Hospital ²Internal medicine, Teikyo University Chiba Medical Center, Chiba, Japan
³Surgery, Yamanashi Central Hospital, Yamanashi, Japan ⁴Gastroenterology, Chiba University, Chiba, Japan ⁵Genome Analysis Center,
Yamanashi Central Hospital, Yamanashi, Japan ⁶University of Tokyo, Tokyo, Japan

Shuntaro Obi^{1,2}, Yuji Iimuro³, Miho Kanda¹, Hiroshi Ohyama^{1,4,5}, Hitoshi Mochizuki^{1,5}, Yuihiro Kojima¹, Yoji Suzuki¹, Kazuhiko Hosoda¹, Sumio Hirose¹, Yukiko Asakawa¹, Hiroyuki Amano¹, Kyoko Nakajima¹, Akinori Abe¹, Masao Omata^{1,5,6}

Aim: Oral preparation of anti HCV drug completely changed the paradigm of Hepatology. In this communication, we addressed the issue whether any drastic change be needed for the treatment of HCC in SVR era.

Methods: We enrolled 611 patients who achieved SVR after DAA (Direct Acting Antiviral) between 2013 and 2020. The patient was prospectively observed for develop of HCC. In this communication we assessed the utility of 3 major interventions; open, laparoscopic (LAP) surgeries, and radiofrequency ablation (RFA) in real world settings.

Results: HCC developed in 48 of 611 (7.8%) patients. The treatment options included 7, 15, and 16 of open, LAP, and RFA, respectively. The other 10 patients received various treatments. The 1-, 3-, and 5-year recurrence-free survival rates were 60%, 30%, and 30% for open, 93%, 93%, and 93% for LAP, and 63%, 47%, and 28% for RFA, respectively, which were significantly better in the LAP group ($p < 0.05$). The overall survival rates at 1, 3 and 5 years were 100%, 80% and 80% for open and 93%, 93% and 93% for LAP, and 93%, 83%, and 80% for RFA, respectively. The most important result was that liver function improved after SVR was achieved, which was advantageous for both treatments.

Conclusion: Recently, pivotal prospective study of randomized control study (open surgery vs. RFA) completed. In real world setting, especially in SVR era, laparoscopic surgery be the third but could be the most preferred of golden of treatment.

A case of Primary Biliary Cholangitis Undergoing RFA for Liver Metastasis of Cervical Cancer

¹Department of Gastroenterology, University of Yamagata, Japan

Ken Nogami¹, Kazuo Okumoto¹, Keita Maki¹, Taketo Nishina¹, Tomohiro Katsumi¹, Kyoko Hoshikawa¹, Hiroaki Haga¹, Yoshiyuki Ueno¹

We report a 57-year-old woman who had undergone total hysterectomy and radiation therapy for cervical cancer at the age of 51. Primary biliary cholangitis (PBC) was diagnosed at the age of 55, for which UDCA 600 mg was administered and the patient was followed up. During follow-up, abdominal ultrasonography demonstrated a 15-mm liver tumor in S5. Contrast-enhanced CT demonstrated a 15-mm tumor with weak dark staining in the early phase and low contrast in the late phase. EOB-MRI demonstrated a single 15-mm tumor in S5. Tumor biopsy revealed poorly differentiated squamous cell carcinoma, which was diagnosed as metastasis from the cervical cancer. Radiofrequency ablation (RFA) was performed because the metastasis was a 15-mm single tumor located near the right branch of the portal vein. The ablation range was sufficient and no recurrence was observed thereafter. However, 6 months later, intraperitoneal lymph node metastasis from the cervical cancer was observed and chemotherapy was performed.

Discussion: Cancers metastatic to the liver are encountered frequently and are usually not good candidates for RFA. Although the therapeutic indications for this case were difficult, RFA was selected based on the size, number, and location of the metastatic tumor. Although it is difficult to treat metastatic liver cancer, RFA may be feasible if only a single tumor is present. **Conclusion:** We have described the use of RFA for cervical cancer liver metastasis.

Is Liver Carcinogenesis after SVR IM or MC? By Analysis of Gene Profiles

¹Department of Gastroenterology, Yamanashi Central Hospital ²Internal medicine, Teikyo University Chiba Medical Center, Chiba, Japan
³Genome Analysis Center, Yamanashi Central Hospital, Yamanashi, Japan ⁴Gastroenterology, Chiba University, Chiba, Japan ⁵The University of Tokyo, Tokyo, Japan

Shuntaro Obi¹, Kenji Amemiya³, Yosuke Hirotsu³, Hitoshi Mochizuki^{1,3}, Yuichiro Kojima¹, Yoji Suzuki¹, Kazuhiko Hosoda¹, Hiroshi Ohyama^{1,4}, Sumio Hirose¹, Yukiko Asakawa¹, Hiroyuki Amano¹, Kyoko Nakajima¹, Akinoro Abe¹, Miho Kanda¹, Masao Omata^{1,3,5}

Aim: Oral preparation of anti HCV drug completely changed the paradigm of Hepatology. We prospectively observed HCC carcinogenesis after SVR. In this study, we performed genomic analysis of synchronous and metachronous hepatocellular carcinomas observed before and after DAA treatment, and aimed to clarify the carcinogenic mode by comparing the genetic profiles.

Methods: We enrolled 611 patients who achieved SVR after DAA between 2013 and 2020. These patients were prospectively observed for development of HCC. Genomic analysis was performed using a 72-gene panel of hepatocellular carcinoma-related genes spanning 285,470 bases generated by In house. Genetic mutations were annotated by OncoKB and oncogenic mutations were determined. The mode of carcinogenesis was diagnosed by comparing the obtained gene profiles.

Results: The mean observation period for all 611 patients was 3.6 years, and HCC development was observed in 47 patients (8%) during follow-up. Genomic analysis was performed on 24 nodules in 10 patients, including 8 nodules in 3 patients with previous hepatocarcinoma before DAA treatment (comparable before and after DAA treatment). As a result, 454 mutations were detected. Of these, 51 were oncogenic mutations, with the highest number of 20 in TP53. The mode of carcinogenesis was IM only in one case and two nodules that developed before DAA treatment, but the remaining nine cases and 22 nodules were diagnosed as MC, whether simultaneous or atypical.

Conclusion: Analysis of carcinogenesis patterns by gene profiles showed that all liver carcinogenesis after DAA treatment was multicentric in origin.

ATZ+BEV Therapy Can Control Disease Activity in Patients Who Do Not Respond to Lenvatinib

¹Internal medicine, Teikyo University Chiba Medical Center, Chiba, Japan ²Gastroenterology, Yamanashi Central Hospital, Yamanashi, Japan
³Gastroenterology, Mitsui Memorial Hospital, Tokyo, Japan ⁴Gastroenterology and Hepatology, Kyoundo Hospital of Sasaki Institution, Tokyo, Japan
⁵Gastroenterology, JR Tokyo Hospital, Tokyo, Japan ⁶Gastroenterology, Japanese Red Cross Medical Center, Tokyo, Japan

Shuntaro Obi^{1,2}, Takamasa Ohki³, Shinpei Sato^{1,4}, Masatoshi Akamatsu⁵, Hiroyoshi Taniguchi⁶, Yuji Kondo⁴, Takahisa Sato¹, Kouji Uchino⁶, Toshihiro Kawai⁴, Myuko Kondo³, Hideo Yoshida⁶

Aim: Atezolizumab (ATZ) plus bevacizumab (BEV) therapy was approved in Japan for the treatment of advanced hepatocellular carcinoma. We evaluated the safety and efficacy of ATZ plus BEV therapy as second-line therapy in patients with PD on lenvatinib.

Method: Of the 26 patients who received ATZ+BEV therapy between September 2020 and January 2021, 20 patients who received ATZ+BEV after lenvatinib PD were included in this analysis. The primary endpoint was the response rate by m-RESIST on the first imaging study. Secondary endpoints were disease control rate and adverse events. Dosing criteria and adverse event managements for ATZ plus BEV treatment had followed the guidelines for proper use. Adverse events were evaluated according to CTCAE ver. 5.0.

Result: The median age was 71 years, and 18 patients (90%) were male. There were 19 cases (95%) of more than Up-to-7. Five patients (25%) had portal vein tumor invasion, and eight patients (40%) had distant metastasis. The median observation period was 3 months. Of the 17 patients with evaluable images, 4 patients had a response, with a response rate of 24%. Disease control was achieved in 15 of 17 patients (88%). Some adverse events were observed in 18 of 20 patients (90%). CTCAE Grade 1-2 adverse events accounted for the majority (78%). One patient had grade 5 liver damage.

Conclusion: As a second-line treatment option after lenvatinib therapy, ATZ plus BEV therapy appears to be a disease controllable therapy. However, care must be taken to avoid liver damage.

Development of Novel Therapeutic Agents for HCC by Suppressing Soluble MICA through ADAM9 Inhibition

¹Department of Gastroenterology, Graduate School of Medicine, Chiba University, Chiba, Japan ²Department of Gastroenterology and Hepatology, Nihon University School of Medicine, Japan ³Department of Gastroenterology, Juntendo University, Japan

Keita Ogawa¹, Ryo Nakagawa¹, Junjie Ao¹, Na Qiang¹, Yaojia Ma¹, Jiaqi Zhang¹, Terunao Iwanaga¹, Takafumi Sakuma¹, Hiroaki Kanzaki¹, Kazufumi Kobayashi¹, Masato Nakamura¹, Naoya Kanogawa¹, Takayuki Kondo¹, Sadahisa Ogasawara¹, Ryosuke Muroyama¹, Shingo Nakamoto¹, Tetsuhiro Chiba¹, Tatsuo Kanda², Hitoshi Maruyama³, Naoya Kato¹

Background: Our group has previously reported that single nucleotide polymorphisms in the MHC-class I-related chain A (MICA) were associated with the risk of hepatocarcinogenesis based on genome-wide association study. MICA is a protein that is induced on the cell surface due to stress, and it binds to the NKG2D receptor on NK cells and activates them. On the other hand, HCC produces a protein called A disintegrin and metalloprotease (ADAM) 9, which cleaves MICA and releases it as soluble MICA, thus evading immunity. These findings implicate that ADAM9 inhibitors could potentially activate cancer immunity through a decrease in soluble MICA levels.

Methods: Screening of inhibitors of ADAM9-mediated MICA cleavage was performed by using fluorescence resonance energy transfer assay with Chiba Chemical Library (CCL), which consists of approximately 1,300 novel compounds. The level of soluble MICA was analyzed by ELISA of supernatants derived from HCC cell lines (HepG2 and PLC/PRF/5 cells). Cell viability assays were also performed to examine cytotoxicity of the compounds.

Results: As a result of the screening method described above, polycyclic compound, Compound X significantly suppressed the fluorescent signal strength, indicating a strong inhibitor of ADAM9 candidate. Cell viability assays demonstrated that there was less observational cytotoxicity with Compound X. The results of ELISA revealed that the supernatant derived from Compound X-treated HCC cells dramatically decreased of soluble MICA with low compound concentration.

Conclusion: Compound X might be a potential therapeutic agent for HCC through the inhibition of ADAM9-mediated soluble MICA production.

Impacts of EZH2 Inhibitor UNC1999 on Tumor and Tumor Microenvironment in Hepatocellular Carcinoma

¹Department of Gastroenterology, Graduate School of Medicine, Chiba University ²Division of Gastroenterology and Hepatology, Department of Medicine, Nihon University School of Medicine, Japan

Junjie Ao¹, Tetsuhiro Chiba¹, Tatsuya Kaneko¹, Na Qiang¹, Jiaqi Zhang¹, Yaojia Ma¹, Keita Ogawa¹, Takafumi Sakuma¹, Ryuta Kojima¹, Terunao Iwanaga¹, Motoyasu Kan¹, Hiroaki Kanzaki¹, Kengo Kanayama¹, Yuko Kusakabe¹, Masato Nakamura¹, Ryo Nakagawa¹, Shingo Nakamoto¹, Tatsuo Kanda², Ryosuke Muroyama¹, Naoya Kato¹

Background: Although the past studies exhibited that Enhancer of Zeste Homolog 2 (EZH2), a polycomb group protein, is over-expressed in a variety of cancers including hepatocellular carcinoma (HCC) and is recognized as a therapeutic target molecule, the therapeutic effect on HCC and the impacts on tumor microenvironment are still unclear. We conducted experiments to investigate the anti-tumor effects from the perspective of their tumor microenvironment.

Methods: H22 cells, with BALB/c background, was treated with UNC1999 in vitro. Cell growth and apoptosis were assessed by MTT assay and flowcytometric analyses, respectively. 5x10⁶ H22 cells were implanted into NOD/SCID and BALB/c mice. UNC1999 (15 mg/Kg) was administered intraperitoneally 3 days a week for 2 weeks. Subsequently, subcutaneous tumor tissues were subjected to flowcytometry to analyse the profiles of tumor-infiltrating lymphocytes (TILs), myeloid-derived suppressor cells (MDSCs), macrophages.

Results: In vitro experiments demonstrated that UNC1999 treatment resulted in cell growth inhibition and apoptosis induction through decreasing H3K27me3 levels in a dose-dependent manner. Although H22 cells-derived tumor growth was significantly suppressed by the UNC1999 treatment in NOD/SCID mice, the anti-tumor effect was diminished in BALB/c mice. Flowcytometric analyses demonstrated a significant decrease in the number of CD8⁺ T cells and a significant increase in the number of MDSCs.

Conclusions: Our results revealed that EZH2 inhibition is associated with attenuation of tumor immunity caused by a decrease in TILs and an increase in MDSCs. These findings implicate that combinations which can reverse these alterations may be important in the treatment of HCC with EZH2 inhibitor.

Efficacy of Sorafenib and Radiotherapy vs Sorafenib/Radiotherapy Monotherapy: A Systematic Review

¹Faculty of Medicine, Pelita Harapan University, Tangerang, Indonesia ²Department of Internal Medicine, Faculty of Medicine, Pelita Harapan University, Tangerang, Indonesia ³Department of Radiotherapy, Dr. Cipto Mangunkusumo Hospital, Faculty of Medicine, Universitas Indonesia
Rivaldo S Heriyanto¹, Celine Chrystelle¹, Fenia Tandy¹, Marlyn Suciningtias¹, Audrey Hadisurya¹, Andree Kurniawan², Angela Giselvania³

Background/Aim: The use of Radiotherapy (RT) or Sorafenib as monotherapy in advanced Hepatocellular Carcinoma (HCC) has shown to be beneficial towards patients' Overall Survival (OS). However, the efficacy between combination therapy of Sorafenib and RT versus Sorafenib/RT monotherapy is still controversial. Therefore, this systematic review aims to compare the OS between these two regimens.
Methods: We systematically searched PubMed, PMC, Science Direct, Google Scholar, and Europe PMC, on October 30th, 2021 using a combination of keywords associated with HCC, Sorafenib combined with RT, Sorafenib, or RT monotherapy in relation to their safety and efficacy. Publications included are limited to English manuscripts that were published in the past 10 years. Patients pathologically confirmed with HCC and have no distant metastasis were included. All studies are reviewed and evaluated by all 6 authors. The quality of each included study was assessed using either the Newcastle-Ottawa Scale (NOS) or Jadad Scale.

Results: We identified a total of six cohorts and one clinical trial study involving 6304 patients. Based on NOS, all studies were of good quality. Based on JADAD, one study showed good quality. All studies found a difference between combined therapy or monotherapy regarding its efficacy in treating HCC patients. Five studies showed that combination therapy increased patients' OS. Meanwhile, two other studies showed that sorafenib monotherapy showed greater survival benefit and slows down progression.

Conclusion: Current studies show the use of combination therapy is well tolerated and significantly improved OS. However, further reliable clinical trials should be conducted to confirm the result.

Combination Therapy with Lenvatinib and RFA for CPA Patients with HCC Exceeding up-to-7 Criteria

¹Gastroenterological Center, Yokohama City University Medical Center, Yokohama, Japan ²Department of Gastroenterology, Yokohama City University Graduate School of Medicine, Japan

Kazushi Numata¹, Satoshi Komiyama¹, Kazuya Sugimori¹, Katsuaki Ogushi¹, Satoshi Moriya¹, Akito Nozaki¹, Makoto Chuma¹, Shin Maeda²

Background: Systemic therapy with lenvatinib has a potential to decrease tumor vascularity of hepatocellular carcinoma (HCC). The combination of lenvatinib and RFA was given as the first-line systemic therapy in patients with intermediate-stage HCC exceeding up-to-7 score. We evaluated the efficacy of this combination therapy using objective response rate (ORR) and progression free survival (PFS) by modified Response Evaluation Criteria in Solid Tumors (mRECIST).

Methods: Inclusion criteria of combination therapy were 1) intermediate-stage HCC with up-to-seven score out; 2) unresectable HCC without vascular invasion; 3) Child Pugh A; 4) lesion with smooth surface; 5) locations are suitable for RFA; and 6) agreement of RFA. Nine patients were treated by this combination therapy, while 28 patients having only 1-3) inclusion criteria were treated by lenvatinib monotherapy. Drug discontinuation period before and after RFA were 4 and 10 days, respectively. Regarding baseline characteristics such as age, liver function, tumor size, AFP, et al, no significant differences were observed.

Results: In monotherapy group, ORR of lenvatinib was 46%. In combination group, ORR of lenvatinib was 79% and additional RFA increased ORR from 79 to 100%. Median RFS: combination 19.8 m (95% CI 8.3-NA) versus monotherapy 4.8m (3.5-6.5) (p<0.05). No severe adverse events were observed during RFA.

Conclusion: Although the number of patients is limited, the combination therapy with lenvatinib and RFA may be effective and safe for intermediate-stage HCC, which exceeds up-to-seven criteria. An increase in the number of cases and a long continuous follow-up period are recommended.

Stereotactic Body Radiotherapy for Early-stage Hepatocellular Carcinoma: A Single-center Experience

¹Department of Gastroenterology and Hepatology, Kurashiki Central Hospital, Okayama, Japan ²Department of Gastroenterology and Hepatology, Graduate School of Medicine, Kyoto University, Japan

Shunsuke Okuyama¹, Masayuki Ueno^{1,2}, Mai Matsumoto¹, Takahisa Kayahara¹, Hiroyuki Takabatake¹, Youichi Morimoto¹, Motowo Mizuno¹

Background: Stereotactic body radiotherapy (SBRT) is an emerging treatment option for early-stage hepatocellular carcinoma (HCC) patients who are not suitable for other locoregional therapies. In our previous study, SBRT had negative impact on liver function, which was not found in radiofrequency ablation. Here we present our most updated data.

Methods: We retrospectively reviewed 59 patients with HCC who underwent SBRT between February 2015 and October 2021 at Kurashiki Central Hospital. Four patients underwent multiple sessions of SBRT for different lesions; a total of 66 sessions were evaluable. One-year local control rate, overall survival, and longitudinal changes of ALBI score were analyzed.

Results: The median age was 78 years [range, 53–91] and 35 patients (59.3%) were male. Among 66 sessions of treatment, 51 (77.3%) were performed for recurrent tumors (local recurrence or multicentric recurrence). The Child-Pugh class at baseline was A in 53 sessions (80.3%), and B in 12 sessions (18.2%). Overall, 1-year local disease control rate was 98.1%. During the median follow-up period of 26.2 months, 22 patients (33.3%) died; the median survival time was 61.0 months. The ALBI scores at 1 year after SBRT were significantly worse than the baseline values (-2.27 ± 0.49 vs. -2.19 ± 0.68 , $p = 0.018$).

Conclusion: SBRT showed excellent local control rate and overall survival. However, attention should be paid to its negative impact on liver function.

Circulating IGFBP-1 Provides Resistance to Molecular Targeted Agent in Hepatocellular Carcinoma

¹Division of Gastroenterology, Department of Medicine, Kurume University School of Medicine, Fukuoka, Japan ²Iwamoto Internal Medicine Clinic, Fukuoka, Japan

Hiroyuki Suzuki¹, Hideki Iwamoto^{1,2}, Takashi Niizeki¹, Shusuke Okamura¹, Shigeo Shimose¹, Tomotake Shirono¹, Yu Noda¹, Naoki Kamachi¹, Taizo Yamaguchi², Toru Nakamura¹, Atsutaka Masuda¹, Toshimitsu Tanaka¹, Ryoko Kuromatsu¹, Hironori Koga¹, Takuji Torimura¹

Background: Molecular targeted agents (MTAs) benefit patients' survival in advanced hepatocellular carcinoma (HCC). However, little is known about the prognostic biomarkers and acquired resistance mechanisms in the clinical use of MTAs. We aimed to explore potential biomarkers in MTA treatment and clarify the mechanism of acquired resistance to MTAs.

Methods: We evaluated 91 patients with advanced HCC treated with MTA. Angiogenic proteins in serum from MTA resistant patients were analyzed by protein array. Based on the array results, retrospective clinical study and preclinical IGF-binding protein (IGFBP)-1 mouse HCC tumor models were conducted. In vitro hypoxic assessment, genetic and pharmacological gain-of- and loss-of-function were performed in preclinical models.

Results: MTAs indirectly increased IGFBP-1 levels via hypoxia in the tumor microenvironment, and tumor-secreted IGFBP-1 activated the integrin $\alpha 5\beta 1$ /FAK/ERK cascade in endothelial cells, resulting in the promotion of cell proliferation and angiogenesis. Moreover, these effects were well-preserved under MTA exposure. Genetic and pharmacological loss-of-function of IGFBP-1 sensitized HCC xenograft mouse models to MTAs.

Conclusions: Our study provides a strong rationale for the underlying mechanisms contributing to MTA resistance in hepatoma cells. Elevated serum IGFBP-1 level with MTA treatments could be a potential biomarker for poor prognosis in patients with advanced HCC. Moreover, the combination of MTAs and IGFBP-1 signal inhibitors might be a promising therapy for patients with advanced HCC.

The Effect of Glucosylceramide Synthase Inhibitor on Liver Fibrosis Regression

¹Department of Gastroenterology, Graduate School of Medicine, Chiba University, Chiba, Japan ²Department of Gastroenterology and Hepatology, Nihon University School of Medicine, Tokyo, Japan ³Department of Gastroenterology, Juntendo University School of Medicine, Tokyo, Japan ⁴Graduate School of Pharmaceutical Sciences, Chiba University, Chiba, Japan

Terunao Iwanaga¹, Tetsuhiro Chiba¹, Jiaqi Zhang¹, Junjie Ao¹, Na Qiang¹, Yaojia Ma¹, Keita Ogawa¹, Takafumi Sakuma¹, Hiroaki Kanzaki¹, Masato Nakamura¹, Takayuki Kondo¹, Ryo Nakagawa¹, Sadahisa Ogasawara¹, Shingo Nakamoto¹, Jun Kato¹, Tatsuo Kanda², Hitoshi Maruyama³, Hiroyuki Nakamura⁴, Toshihiko Murayama⁴, Naoya Kato¹

Background: TGF β /Smad pathway is known to be the most important mechanism in pathogenesis of liver fibrosis. It has been reported that ceramide regulates collagen production through the activation of TGF β /Smad pathway. In this study, we examined whether miglustat, a glucosylceramide synthase inhibitor, has anti-fibrotic effect via inhibition of TGF β /Smad pathway.

Methods: Human hepatic stellate cell (HHStEC) was treated with a various concentration of miglustat in the presence of TGF β in culture. The expression of collagens was examined by quantitative RT-PCR. The phosphorylation of Smad3 and nuclear translocation of Smads (Smad2, 3 and 4) were evaluated by Western Blotting and immunocytochemistry, respectively. After C57BL/6 mice were treated with carbon tetrachloride (CCl₄) for 4 weeks, miglustat in combination with CCl₄ was administrated for further 2 weeks. All mice were then sacrificed to assess the extent of liver fibrosis.

Results: mRNA expression of ECMs and α smooth muscle actin in TGF β -treated HHStEC was significantly suppressed by miglustat in a dose-dependent manner. Western blotting revealed phosphorylation of Smad3 induced by TGF β was inhibited by miglustat. The nuclear translocation of Smad2, Smad3 and Smad4 was inhibited by miglustat. Sirius red staining revealed that collagen was significantly reduced in miglustat-treated group than in control group. qPCR assays demonstrated that mRNA expression of collagen was also suppressed by miglustat treatment compared with controls.

Conclusion: Our findings suggest that miglustat might have an effect on liver fibrosis regression through the inhibition of phosphorylation and nuclear translocation of Smads.

Transient High Transaminase Elevation Does Not Affect on Short Term Outcomes after Liver Resection

¹Department of Digestive Surgery, Nihon University School of Medicine, Japan

Yusuke Mitsuka¹, Shintaro Yamazaki¹, Yukiyasu Okamura¹, Tokio Higaki¹, Tadatoshi Takayama¹

To clarify whether high transient elevation of serum transaminase predicts severe complications and is related to the ischemic area on CT. Postoperative laboratory data and ischemia area on CT were analyzed on the basis of the presence of high transaminase elevation (aspartate aminotransferase (AST) more than 1000 IU/L within postoperative day (POD) 2 after liver resection. In the high elevation group, recovery of ischemic areas was assessed by CT volumetry on POD2. The 538 patients were divided into a high transaminase group (n=51) and a control group (n=487). Median operation time (527 min vs. 360 min, p=0.001) and liver ischemia time (121 min vs. 70 min, p=0.001) were significantly longer, and intraoperative blood loss (478 mL [85-1572 mL] vs. 269 mL [5-4491 mL], p=0.001) was significantly greater in the high transaminase group. No significant differences in frequency of severe complications (Clavien-Dindo classification Grade III or more) or postoperative hospitalization were seen. Operation time (more than 500 min; odds ratio (OR), 4.86; 95% confidence interval (CI), 2.40-9.89; p=0.001) and liver ischemia time (more than 120 min; OR, 3.47; 95%CI, 1.67-7.17; p=0.001) were independent predictors of high transaminase elevation. No relationship was observed between degree of transaminase elevation and ischemic area (correlation coefficients: AST, R²=0.001; alanine aminotransferase, R²=0.005) CT volumetry on POD2. In conclusions, high transaminase elevations do not predict severe complications or reflect remnant ischemic area.

Stereotactic Body Radiation Therapy for Early-stage Hepatocellular Carcinoma

¹Department of Gastroenterology and Metabolism, Hiroshima University, Hiroshima, Japan ²Department of Radiation Oncology, Hiroshima University, Hiroshima, Japan

Shigeki Yano¹, Tomokazu Kawaoka¹, Takashi Nakahara¹, Eisuke Murakami¹, Michio Imamura¹, Katsumaro Kubo², Yasushi Nagata², Hiroshi Aikata¹

Background: We retrospectively evaluated the local tumor control, survival and safety of stereotactic body radiation therapy (SBRT) combined with transcatheter arterial chemoembolization (TACE) for early-stage hepatocellular carcinoma (HCC).

Methods: Patients with early-stage HCC unsuitable for surgical resection or radiofrequency ablation treated with SBRT from December 2008 to July 2021 were retrospectively evaluated. Eligible criteria were as followed: i) less than 3 HCC nodules, each up to 50 mm in diameter; ii) no metastasis; iii) Child-Pugh grades were up to grade B.

Results: 282 HCC patients were enrolled in this study. The median age of patients was 76-year-old. 242 patients were classified as Child-Pugh A. Almost all SBRT were performed until 2 months after TACE. 234 patients had previous history of HCC treatment. The local tumor recurrence rate was 2.1% in 5 years. However, 179 patients had out-of-field relapse. The median of overall survival was 30 months and that of disease-free survival was 12 months. Only 6 patients developed grade 3 toxicities by SBRT during follow-up periods.

Conclusions: SBRT combined with TACE is an effective modality for early-stage HCC with low rates of significant toxicity. However, out-of-field relapse remains common, providing a suggestion to follow up carefully and investigate SBRT in combination with other therapies.

Combination Therapy for Multiple HCC with Tyrosine Kinase Inhibitor and Radiofrequency Ablation

¹Yamagata University Hospital Second Internal Medicine, Japan

Keita Maki¹, Kazuo Okumoto¹, Yoshiyuki Ueno¹

Radiofrequency ablation (RFA) for HCC is indicated for patients who have three or fewer tumors 3 cm or less in diameter. Here we report the use of TKI in combination with RFA for two patients, each of whom had four hepatocellular carcinoma nodules. Case 1: An 85-year-old male with alcoholic liver cirrhosis underwent hepatectomy and TACE for HCC. Subsequently, the patient suffered recurrence, and four nodules were detected. After administration of sorafenib 800 mg, Contrast CT demonstrated reduction of three of the HCC nodules, but one increased in size to 27 mm. The latter was ablated with a 3-cm cool tip needle. Regorafenib 40 mg was then administered. Case 2: A 69-year-old male with alcoholic liver cirrhosis developed four HCC nodules, one measuring 25 mm with weak staining, and three measuring 10 mm with deep staining. The 25-mm nodule was ablated with a 3-cm cool tip needle. Subsequently, oral administration of lenvatinib 8 mg was started, but was discontinued one month later due to side effects.

Discussion: TKI can exert significant antitumor effects, and in some cases can be as effective as surgery or TACE. Combination with TKI can be considered for patients in whom nodules are increasing or the case is expected to be difficult with TKI alone and complete ablation is possible with RFA. Conclusion: We have described two cases of multiple HCC for which RFA was used in combination with TKI. Treatments that combine chemotherapy with RFA are worth considering.

Phenotypic and Genetic Features of Multiple Nodules in HCC Based on Tumor Evolutionary Trait

¹Genome Analysis Center, Yamanashi Central Hospital ²Department of Hepatobiliary Surgery, Yamanashi Central Hospital ³Division of Genetics and Clinical Laboratory, Yamanashi Central Hospital ⁴Department of Gastroenterology, Yamanashi Central Hospital ⁵University of Tokyo, Japan
Yosuke Hirotsu¹, Yuji Jimuro², Kenji Amemiya³, Hitoshi Mochizuki^{1,4}, Masao Omata^{4,5}

Background: Comprehensive genomic analysis of hepatocellular carcinoma (HCC) identified driver mutations in TERT, TP53, CTNNB1, chromatin remodeling and oxidative stress genes. Macroscopic and microscopic examination revealed the formation of fibrous capsules and septa in HCC. However, it remains unknown the genetic features in different phenotypic compartments in a nodule.

Methods: We performed laser-capture microdissection and obtained a total of 126 lesions from 55 patients with HCC. Of 126 lesions, 68 nodules from 26 patients were examined based on macroscopic and microscopic examination and subjected to multi-regional sequencing. We used in house panel targeting the whole exons of 70 significantly mutated genes associated with HCC and TERT promoter, spanning 285,500 nucleotides. To infer the tumor evolution, neighbor-joining and PyClone methods estimated tumor phylogeny and cellular prevalence using mutational profiles and copy number status.

Results: We found trunk mutations in all HCC. The variant allele fraction of trunk mutations is higher than that of branched mutations. TERT and TP53 were mainly classified as trunk mutations in most tumors. Surprisingly, CTNNB1, NFE2L2 and chromatin remodeling component (ARID1A and ARID1B) were mainly observed as branch mutations. Phylogenetic analysis showed NFE2L2, ARID1B and PIK3CA mutated clones evolved as linear model; whereas CTNNB1 mutated clones followed with parallel evolution. These results suggested the ancestor tumor clones differentiated and transformed different phenotypic compartment.

Conclusion: Multi-regional genetic analysis revealed the features of tumor evolution of intratumor nodules in HCC. The phylogeny discriminated the trunked and branched driver genes in HCC. The trunk mutations will be hopeful therapeutic targets.

Macrotrabecular Massive Feature in Tumor is Associated with a Higher Risk of the Recurrence of HCC

¹Department of Internal Medicine, Yonsei University College of Medicine, Seoul, Korea
Hyun Woong Lee¹, Sunghwan Yoo¹, Jung Il Lee¹, Kwan Sik Lee¹

Background/Aim: Hepatocellular carcinoma (HCC) with a macrotrabecular-massive feature (MTM) have been reported to be associated with frequent recurrence and poor disease-specific survival in resected HCCs. We aim to investigate the clinical significance of MTM feature to predict the recurrence of HCC.

Method: Data and samples from 171 patients with HCC treated by surgical resection between Jan 2007 and Dec. 2017 were retrospectively analyzed. By pathological review, the prognostic significance of MTM feature was evaluated in a series of 171 patients with HCC treated by surgical resection in Gangnam Severance Hospital.

Results: Among the 171 patients (136 males, mean age 63.1±10.0 years) who underwent surgical resection, the median clinical follow-up was 6.2 (2.5-13.5) years. The median duration of the recurrence of HCC was 4.1 (1.0-12.9) years. Among them, 74 patients (43.3%) experienced HCC recurrence. The MTM feature was identified in 32.7% of the whole cohort (n=35, 47.3% in recurrence group vs. n=21, 21.6% in no-recurrence group, P<0.001). The recurrence of HCC after curative resection was associated with age, maximal tumor size, and MTM feature (HR, 1.036, P=0.028, HR, 1.132, P=0.032, and HR, 3.248, P=0.001, respectively) in univariate analysis. Multivariate analysis showed that the independent predictor of HCC recurrence was only MTM feature (hazard ratio, 1.881; 95% confidence interval, 1.143-3.095; P=0.013).

Conclusion: We have shown that MTM feature in tumor tissues is associated with a higher risk of the recurrence of HCC in retrospective cohorts of patients with HCC treated by surgical resection.

Examination of the Effect of Embolization of Corona Enhancement Area on Local Tumor Recurrence

¹Nihon University School of Medicine, Division of Gastroenterology and Hepatology, Department of Medicine, Japan

Yukinobu Watanabe¹, Masahiro Ogawa¹, Masahiro Kaneko¹, Mariko Kumagawa¹, Midori Hirayama¹, Naoki Matsumoto¹, Toshiki Yamamoto¹, Tatsuo Kanda¹, Mitsuhiro Moriyama¹

Background: Safety margin in the treatment of transcatheter arterial chemoembolization (TACE) for hepatocellular carcinoma (HCC) has been reported as an important issue for a long time. Local tumor recurrence (LTR) of HCC often occurs in blood drainage areas. Corona enhancement is determined by computed tomography during hepatic arteriography (CTHA) and is considered to represent the blood drainage area. We aimed to investigate the association between embolization of corona enhancement area and LTR rates in HCC-patients who underwent TACE.

Methods: Patients with HCC nodules were included in this retrospective study. These nodules showed corona enhancement area on late-phase CTHA and homogenous accumulation of iodized oil throughout the nodule on non-contrast-enhanced CT, which were performed immediately after TACE. We divided the nodules into two groups, according to whether the accumulation of iodized oil covered the entire corona enhancement area (group A) or not (group B). Local tumor recurrence rates were compared between the two groups.

Results: Cumulative LTR rates at 3, 6 and 12 months of group A or those of group B, respectively, were 3%, 3% and 8% or 21%, 46% and 75%. Cumulative LTR rates of group A were significantly lower than those for group B ($p < 0.001$).

Conclusion: Corona enhancement area may be an accurate safety margin in TACE. TACE should be performed until the embolic area covers the entire corona enhancement area.

Acidic Microenvironment Aggravates HIRI by Modulating M1-Polarization by PPAR-gama Signal

¹The Third Affiliated Hospital of Soochow University, Changzhou, Jiangsu, China

Wei Ding¹, Yunfei Duan¹, Donglin Sun¹, Yunjie Lu¹

Hepatic injury induced by ischemia and reperfusion (HIRI) is a major clinical problem after liver resection or transplantation. Recent evidence had indicated that the ischemia induces an acidic microenvironment by causing increased anaerobic glycolysis and accumulation of lactic acid. We hypothesize that the acidic microenvironment might cause the imbalance of intrahepatic immunity which aggravated HIRI. The hepatic ischemia/reperfusion injury model was established to investigate the effect of the acidic microenvironment to liver injury. Liposomes were used to deplete macrophages in vivo. Macrophages were cultured under low pH conditions to analyze the polarization of macrophages in vitro. Activation of the PPAR-gama signal was determined by Western Blot. PPAR-gama agonist GW1929 was administrated to functionally test the role of PPAR-gama in regulating macrophage-mediated effects in the acidic microenvironment during HIRI. We demonstrate that acidic microenvironment aggravated HIRI while NaHCO₃ reduced liver injury through neutralizing the acid, besides, liposome abolished the protective ability of NaHCO₃ through depleting the macrophages. In vivo and vitro experiment showed that acidic microenvironment markedly promoted M1 polarization but inhibited M2 polarization of macrophage. Furthermore, the mechanistic study proved that the PPAR-gama signal was suppressed during the polarization of macrophages under pH=6.5 culture media. The addition of GW1929 inhibited M1 polarization under acidic environment and reduced HIRI. Our results indicate that acidic microenvironment is a key regulator in HIRI which promoted M1 polarization of macrophages through regulating PPAR-gama. Conversely, PPAR-gama activation reduced liver injury, which provides a novel therapeutic concept to prevent HIRI.

Protection Mechanism of DDIT4 S-Nitrosylation in ROS

¹The Department of Hepatobiliary and Pancreatic surgery, The Third Affiliated Hospital of Soochow University, Changzhou, China ²Key Laboratory of Targeted Intervention of Cardiovascular Disease Collaborative Innovation Center for Cardiovascular Translational Medicine, Nanjing Medical University, Nanjing, China ³Institute of Biomedical Research, Liaocheng University, Liaocheng, China ⁴State Key Laboratory of Natural Medicines Department of Pharmacology, China Pharmaceutical University, Nanjing, China
Yunfei Duan¹, Zidong Li^{1,2,3,4}, Qianwen Zhao⁴, Yunjie Lu¹, Yangxi Zhang², Luyang Li², Min Li², Xuemin Chen¹, Donglin Sun¹, Yong Xu⁴

Mitogen-activated protein kinase (MAPK) signaling plays a significant role in reactive oxygen species (ROS) production. The authors have previously shown that Brahma-related gene 1 (BRG1), a chromatin remodeling protein, contributes to hepatic ROS accumulation in multiple animal and cellular models of liver injury. Here it is reported that DNA damage-induced transcript 4 (DDIT4) is identified as a direct transcriptional target for BRG1. DDIT4 overexpression overcomes BRG1 deficiency to restore ROS production whereas DDIT4 knockdown phenocopies BRG1 deficiency in suppressing ROS production in vitro and in vivo. Mechanistically, DDIT4 coordinates the assembly of the p38-MAPK signaling complex to drive ROS production in an S-nitrosylation dependent manner. Molecular docking identifies several bioactive DDIT4-interacting compounds including imatinib, nilotinib, and nateglinide, all of which are confirmed to attenuate hepatic ROS production, dampen p38-MAPK signaling, and ameliorate liver injury by influencing DDIT4 S-nitrosylation. Importantly, positive correlation between ROS levels and BRG1/DDIT4/S-nitrosylated DDIT4 levels is detected in human liver biopsy specimens. In conclusion, the data reveal a transcription-based signaling cascade that contributes to ROS production in liver injury.

Molecular Mechanism of CCL7 by BRG1 in Liver Injury

¹The Department of Hepatobiliary and Pancreatic surgery, The Third Affiliated Hospital of Soochow University, Changzhou, China ²Key Laboratory of Targeted Intervention of Cardiovascular Disease, Department of Pathophysiology, Nanjing Medical University, Nanjing, China ³Department of Pathology, Affiliated Nanjing Drum Tower Hospital of Nanjing University School of Medicine, Nanjing, China ⁴College of Life Sciences and Institute of Biomedical Research, Liaocheng University, China ⁵State Key Laboratory of Natural Medicines, Department of Pharmacology, China Pharmaceutical University, Nanjing, China
Yunjie Lu¹, Ming Kong², Wenhui Dong², Yuwen Zhu², Zhiwen Fan³, Xiulian Miao⁴, Yan Guo⁴, Chengping Li⁴, Yunfei Duan¹, Zilong Li⁵, Yong Xu^{1,4}

Liver injuries induced by various stimuli share in common an acute inflammatory response, in which circulating macrophages home to the liver parenchyma to participate in the regulation of repair, regeneration, and fibrosis. In the present study we investigated the role of CCL7 in macrophage migration during liver injury focusing on its transcriptional regulation. We report that CCL7 expression was upregulated in the liver by lipopolysaccharide (LPS) injection (acute liver injury) or methionine-and-choline-deficient (MCD) diet feeding (chronic liver injury) paralleling increased macrophage infiltration. CCL7 expression was also inducible in hepatocytes, but not in hepatic stellate cells or in Kupffer cells, by LPS treatment or exposure to palmitate in vitro. Hepatocyte-specific deletion of Brahma-related gene 1 (BRG1), a chromatin remodeling protein, resulted in a concomitant loss of CCL7 induction and macrophage infiltration in the murine livers. Of interest, BRG1-induced CCL7 transcription and macrophage migration was completely blocked by the antioxidant N-acetylcysteine. Further analyses revealed that BRG1 interacted with activator protein 1 (AP-1) to regulate CCL7 transcription in hepatocytes in a redox-sensitive manner mediated in part by casein kinase 2 (CK2)-catalyzed phosphorylation of BRG1. Importantly, a positive correlation between BRG1/CCL7 expression and macrophage infiltration was identified in human liver biopsy specimens. In conclusion, our data unveil a novel role for BRG1 as a redox-sensitive activator of CCL7 transcription.

Dynamic Gut Microbiome Affects the Efficacy of PD-1-based Immunotherapy in Hepatocellular Carcinoma

¹Department of Infectious Diseases, the Third Affiliated Hospital of Sun Yat-sen University, Guangzhou, Guangdong Province, China

²Department of Interventional Radiology, the Third Affiliated Hospital of Sun Yat-sen University, Guangzhou, Guangdong Province, China
Chan Xie¹, Hewei Wu¹, Xingrong Zheng¹, Tao Pan², Xiaolan Yang¹, Xiyao Chen¹, Boxiang Zhang¹, Liang Peng¹

Background: Hepatocellular carcinoma (HCC) is a severe disease with high mortality and global incidence. The gut microbiome affecting the responses to immune checkpoint inhibitors has been investigated in some types of tumors. However, the interaction between the gut microbiome and combined immunotherapy for HCC is yet unclear.

Methods: Patients with unresectable HCC who had not received systemic treatment previously were recruited in this prospective clinical study. Fecal and serum samples were collected at the starting point and before the specified subsequent administration. The primary endpoint was the ratio of objective response rate to tumor response rate.

Results: Between October 20, 2019 and February 2, 2021, valid data from 35 HCC patients were included in this study. Among them, two (5.7%) patients had a complete response and 14 (40.0%) had partial responses; thus, 16/35 (45.7%) patients achieved an objective response. No immune-related adverse events of death were observed in the current cohort. Prominent alpha-diversity and beta-diversity between responders (R) and non-responders (NR) tended to be similar at the second and third doses. R-enriched Ruminococcus and Klebsiella genera were found to be associated with differential metabolites in the serum via galactaric acid metabolism and bacteriophage antigen activation.

Conclusions: Combined immunotherapy is well-tolerated and presents a therapeutic option for advanced HCC patients. Interventions for the gut microbiota are recommended to begin at 6 weeks or earlier. Thus, identifying potentially beneficial populations based on microbiome and metabolomics is desirable in HCC.

An Autopsy Case of Ruptured Hepatocellular Carcinoma following Administration of Lenvatinib

¹Department of Gastroenterology and Hepatology, Saitama Medical Center, Saitama Medical University ²Department of Pathology, Kurume University School of Medicine, Japan

Kumichika Uchida¹, Toru Aoyama¹, Sachiko Ogasawara², Hirohisa Yano², Sumiko Nagoshi¹

Background: Lenvatinib was approved in Japan for first-line treatment of unresectable hepatocellular carcinoma in 2018. Although tumor lysis syndrome or liver tumor rupture after starting lenvatinib has been reported, no cases have been analyzed pathologically.

Case Presentation: Lenvatinib was introduced in a 71-year-old man with hepatocellular carcinoma with a maximum size of 210 mm and portal vein tumor thrombosis. However, 8 days later, the treatment was discontinued due to the elevation of AST and LDH levels, and prolongation of prothrombin time. Rupture of hepatocellular carcinoma occurred 4 days after the discontinuance and the patient died. Autopsy findings showed moderately differentiated hepatocellular carcinoma with diffuse hemorrhagic necrosis. FGF19 protein expression by immunohistochemistry was diffusely seen in the nuclei of tumor cells, while some of the nuclei and cytoplasm of the hepatocytes in non-tumor samples were slightly stained. The number of CD34-positive endothelial cells decreased in tumor samples, especially in the degenerated tissue.

Discussion: FGF19 is considered to be a tumor biomarker of lenvatinib-susceptible hepatocellular carcinoma. The relation between the increased expression of FGF19 in the nuclei of tumor cells and diffuse hemorrhagic necrosis resulting in rupture should be investigated.

Relationship between Serum Kynurenine Level and Prognosis of Patients with Hepatocellular Carcinoma

¹Department of Hepatology, National Hospital Organization Nagasaki Medical Center, Japan

Shigemune Bekki¹, Takahito Nishihara¹, Yuki Kugiyama¹, Tomoyuki Suehiro¹, Yasuhide Motoyoshi¹, Akira Saeki¹, Shinya Nagaoka¹, Seigo Abiru¹, Kazumi Yamasaki¹, Atsumasa Komori¹, Hiroshi Yatsuhashi¹

Background: We have previously reported that high serum kynurenine level is a poor prognosis factor in hepatitis C patients with hepatocellular carcinoma (HCC). In this study, we investigated the usefulness of serum kynurenine levels at the onset of HCC according to background liver disease.

Methods: We investigated 1055 patients with HCC between 1999 and 2015. Of these, HBsAg-positive cases were defined as B-HCC (233 cases), HCV antibody-positive cases were defined as C-HCC (604 cases), and HBsAg-negative and HCV antibody-negative cases were defined as nonBC-HCC (206 cases).

Results: The median serum kynurenine of B-HCC, C-HCC, nonBC-HCC was 448.9 ng/mL, 557.1 ng/mL, 565 ng/mL, respectively, and significantly lower in B-HCC ($P < 0.001$, Mann-Whitney, Bonferroni correction). The cut-off values for serum kynurenine for 5-year survival prediction of B-HCC, C-HCC, nonBC-HCC were 453 ng/mL (AUROC 0.57), 551 ng/mL (AUROC 0.56), and 564 ng/mL (AUROC 0.55), respectively. The prognosis was significantly poor in the group with high serum kynurenine level; 5-year survival rates of B-HCC with serum kynurenine < 450 and ≥ 450 ng/mL were 60.5% and 42.6% ($p = 0.005$, Log rank). Those of C-HCC with serum kynurenine < 600 and ≥ 600 ng/mL were 61.4% and 43.9% ($p < 0.001$, Log rank), and those of nonBC-HCC with serum kynurenine < 600 and ≥ 600 ng/mL were 62.7% and 36.9% ($p = 0.031$, Log rank).

Conclusions: When examining the effect of serum kynurenine levels on HCC, it is necessary to consider that the values vary depending on the background liver disease.

Measurement of Renal Vein and IVC in Patients with Cirrhotic Ascites and Congestive Liver

¹Division of Gastroenterology and Hepatology, Department of Medicine, Nihon University School of Medicine, Tokyo, Japan

Masahiro Kaneko¹, Masahiro Ogawa¹, Mariko Kumagawa¹, Yukinobu Watanabe¹, Midori Hirayama¹, Naoki Matsumoto¹, Hiroshi Nakagawara¹, Toshiki Yamamoto¹, Mitsuhiro Moriyama¹

Aim: Hepatic ascites causes the acceleration of renal venous pressure due to the oppression of inferior vena cava (IVC) by ascites, and develops renal venous hypertension. Congestive liver associated with right heart failure is recognized to cause blood flow congestion of IVC and develops renal venous hypertension as well. Our presentation is to report the result of measuring the diameter and the velocity of renal vein and IVC using ultrasonography for the evaluation of renal venous hypertension.

Methods: Patients who underwent treatment in our hospital from April 2015 to March 2017. The diameter and velocity of IVC, left renal vein were measured using ultrasonography in supine position. All cases are divided into 4 groups; normal liver, liver cirrhosis (LC), LC with ascites, and congestive liver.

Results: In the congestive liver group, the diameter of the IVC was larger compared to the normal liver, LC, and LC with ascites groups. In the normal liver group, the diameter of the IVC was larger compared to the LC with ascites group. In the normal liver group, the IVC flow velocity was greater compared to the LC with ascites group. The left renal vein diameter increased in the following order: normal liver, LC, LC with ascites, and congestive liver groups.

Conclusion: The left renal vein and IVC can be measured using ultrasonography. In patients with LC, IVC compression due to ascites might cause blood stagnation and renal congestion. It might help in furthering our understanding of the pathophysiology of renal congestion in these patients.

A Case of Mortality from an Incidental Intrahepatic Cholangiocarcinoma with Severe Cholecystitis

¹Tokyo Saiseikai Central Hospital ²Nippon Koukan Hospital, Japan

Yoshie Kadota^{1,2}, Yu Aoki¹, Ayaka Yu¹, Haruka Yagishita¹, Masanori Odaira¹, Yosuke Kobayashi¹, Ayumi Yokoyama¹, Shinsuke Funakoshi¹, Atsushi Nakazawa¹, Takashi Endo¹, Hirohisa Harada¹

Primary intrahepatic cholangiocarcinoma (ICC) is an aggressive carcinoma with a poor prognosis. A man in his early 70's with moderate obesity and type 2 diabetes mellitus presented to our hospital for a severe cholecystitis with a large hepatic abscess in the liver bed. He underwent cholecystectomy 2.5 months after the initial treatment with antibiotics and drainage. Postoperative course was uneventful except for re-elevation of white blood cell count and C-reactive protein. Computed tomography revealed a non-homogenous low-density lesion in the right liver, which rapidly increased in its size to 4.3 cm. Magnetic resonance imaging showed high intensity in diffusion-weighted imaging, with questionable smaller lesions. The lesions were sought to be remnants of the liver abscess. However, the biopsy revealed an incidental ICC. He underwent chemotherapy with Gemcitabine and Cisplatin because of low estimated remnant liver volume (< 35 %), and a rapid growth pattern with an elevated CA19-9 (726.4 U/l). The chemotherapy was terminated after 4 courses because of worsening renal failure. Six months after the initial diagnosis of ICC with minimal response to chemotherapy, a salvage right-posterior-hepatic sectionectomy was unsuccessfully attempted, because of peritoneal dissemination and revelation of another tumor on the lateral side of the liver, which was undetected in the preoperative imaging. The patient subsequently expired 3 months after the surgery due to tumor progression. This patient whose clinical presentation indicated abscess associated with severe cholecystitis, but was incidentally diagnosed with ICC, highlights how rapidly and aggressively ICC progresses.

Conversion Surgery for Advanced Hepatocellular Carcinoma after Lenvatinib, A Case Report

¹Funabashi Central Hospital, Japan ²Chiba Rosai Hospital ³Matsudo City General Hospital, Japan

Kazuki Kato¹, Tadashi Sekimoto², Yoshihiro Takahara¹, Taro Shimada¹, Shin Tsuchiya¹, Kousho Asano¹, Tosimasa Shimizu¹, Midori Sawada¹, Takahiro Nishida¹, Hidehiko Uno¹, Mari Aminaka¹, Keiko Korenaga^{1,3}, Teisuke Komatsu¹, Fukuo Kondo¹, Taketo Yamaguchi¹, Osamu Yokosuka³

Lenvatinib is a novel potent multi-tyrosine kinase inhibitor. We report a case of a patient who underwent partial hepatic resection after treatment with lenvatinib. The patient was a 65-year-old man. Two years before, he had received SOF/LDV treatment for chronic hepatitis C at another hospital and had achieved SVR. Abdominal ultrasound at our hospital showed a 9 cm liver tumor in the right lobe of the liver. Dynamic CT showed a 9.5cm tumor in the posterior lobe. Involvement of hepatic vein and portal vein was also suspected. PIVKA2 was high at 13889mAU/ml. An ultrasound-guided biopsy was performed, the diagnosis of hepatocellular carcinoma was obtained, and the patient was started on lenvatinib. Dynamic CT at 2 months after the administration showed that the mass shrunk to 8 cm and blood flow decreased. At 3 months later, PIVKA2 was reduced to 2031mAU/ml. However, at 4 months, the patient discontinued lenvatinib due to generalized pain. One month after discontinuation, the liver mass enlarged, and PIVKA2 increased to 13889mAU/ml. In the same month, extended right posterior segmentectomy was performed. In the resected specimen, the tumor was 6.5x6.0cm, and there were both viable tumor cells area and coagulative necrotic area. Moderately differentiated hepatocellular carcinoma, (macrotrabecular pattern, vp1 and vvo) was existed. Wall thickening and stenosis of the nearby interlobular hepatic artery was observed. The patient is alive and recurrence free at 2 years after resection. Lenvatinib may cause degeneration of interlobular hepatic arteries, and the hepatocellular carcinoma may have undergone ischemia and coagulation necrosis.

Experience of Antiviral Therapy in Patients Co-infected with HIV and Hepatitis Virus

¹The Department of Gastroenterology, National Hospital Organization Chiba Medical Center, Chiba, Japan

Yuki Haga¹, Yoshiki Oogane¹, Tomomi Ozaki¹, Ayako Shingyoji¹, Koji Nishimura¹, Tatsuo Miyamura¹, Kenji Ito¹, Asami Abe¹, Satoru Kaneda¹, Minoru Tada¹, Masaaki Saito¹, Nobuyuki Sugiura¹

Co-infection with human immunodeficiency virus (HIV) and hepatitis B virus (HBV), and hepatitis C virus (HCV) is common because both viruses are transmitted mainly by blood. We report our experience with antiviral therapy for hepatitis C and B viruses in HIV-infected patients at our hospital, which is a national hospital in a regional city located in the metropolitan area of Japan. In our hospital, we have treated 4 cases of hepatitis C and 4 cases of hepatitis B among patients with HIV. The median age of patients with hepatitis C was 42 years (30-54). One patient received PEG-interferon (IFN) α 2a, and three patients received direct-acting antivirals (DAAs). IFN-treated patients did not receive highly active antiretroviral therapy (HAART) at the time of IFN administration. All DAAs-treated patients were on HAART, and HIV-RNA was undetectable at the start of treatment. All of these HCV-infected patients with complicated HIV infection achieved SVR. The median age of hepatitis B patients was 41 years (31-61). All patients were started on hepatitis B antivirals as one of the drugs included in HAART. The starting antivirals were lamivudine in one patient and tenofovir in three patients. In patients complicated with HBV infection, it was possible to keep HBV-DNA levels below detection by continuing HAART. One case of hepatocellular carcinoma was seen in a patient with HIV and HCV, and curative treatment was possible with radiofrequency ablation.

Regorafenib for Taiwanese Patients with Unresectable HCC after Sorafenib Failure

¹Hepatobiliary Division, Department of Internal Medicine, Kaohsiung Medical University Hospital, Kaohsiung Medical University, Kaohsiung, Taiwan ²Graduate Institute of Clinical Medicine, College of Medicine, Kaohsiung Medical University, Kaohsiung, Taiwan ³School of Medicine and Hepatitis Research Center, College of Medicine, and Center for Liquid Biopsy and Cohort Research, Kaohsiung Medical University, Kaohsiung, Taiwan

Ming-Lung Yu^{1,3}, Po-Yao Hsu^{1,2}, Tzu-Sheng Cheng¹, Po-Cheng Liang¹, Tyng-Yuan Jang¹, Ming-Lun Yeh^{1,3}, Ching-I Huang^{1,3}, Zu-Yau Lin^{1,3}, Shinn-Chern Chen^{1,3}, Jee-Fu Huang^{1,3}, Wan-Long Chuang^{1,3}, Chia-Yen Dai^{1,3}, Chung-Feng Huang^{1,3}

Background and Aims: Regorafenib has demonstrated its survival benefit for unresectable hepatocellular carcinoma (uHCC) patients in a phase III clinical trial. We aimed to assess the efficacy and tolerability of regorafenib in Taiwanese patients.

Methods: We analyzed the survival, best overall response, predictors of treatment outcomes, and safety for uHCC patients who had tumor progression on sorafenib therapy and received regorafenib as salvage therapy between March 2018 and November 2020.

Results: Eighty-six patients with uHCC were enrolled (median age, 66.5 years; 76.7% male). No unpredictable toxicity was observed during treatment. The median overall survival (OS) with regorafenib was 12.4 months (95% CI, 7.8-17.0), and the median progression-free survival (PFS) was 4.2 months (95% CI, 3.7-4.7). Of 82 patients with regorafenib responses assessable, 4 patients (4.9%) achieved a partial response, and 33 (40.2%) had stable disease, leading to a disease control rate (DCR) of 45.1% (n=37). Patients possessing baseline AFP<400 ng/mL exhibited a markedly longer median OS, PFS, and higher DCR compared with their counterparts (15.7 vs. 8.1 months, 4.6 vs. 3.7 months, 60.9% vs. 27.5%, respectively). Despite possessing high baseline AFP levels, patients with early AFP response (>10% reduction at 4 weeks or >20% reduction at 8 weeks after regorafenib administration) exhibited comparable treatment outcomes to those with baseline AFP \geq 400 ng/mL.

Conclusions: The results of this study verified the tolerability and efficacy of regorafenib treatment for uHCC patients who failed prior sorafenib therapy, especially for those with lower baseline AFP levels or with early AFP response.

Education and Information Sharing Method for the Coming Era in Ablation

¹Department of Diagnostic Imaging and Interventional oncology, Juntendo University ²Department of Gastroenterology and Hepatology, Masuko Memorial Hospital ³Department of Gastroenterology, Yamanashi University ⁴Liver Center, Cathay General Hospital Medical Center, Taipei, Taiwan

Maki Tobari¹, Yuko Hijioka¹, Amina Bolatkan¹, Shigeto Ishii¹, Hiroaki Nagamatsu¹, Hitoshi Maruyama¹, Naoki Hotta^{1,2}, Yasuyuki Komiyama^{1,3}, Hsin-yi Chen^{1,4}, Shuichiro Shiina¹

Ablation is highly operator-dependent. Education and sharing information are important to acquire skills and knowledge for successful ablation. Before the pandemic of COVID-19, we held 14 domestic and 7 international training programs, with 237 and 111 participants, respectively. We also held hands-on workshops for young doctors. These activities were to share knowledge and experience to standardize the procedure. However, COVID-19 pandemic has made it difficult for us to get together. Since August 2020, we have conducted Japan Ablation Webinar 8 times with 1,556 participants. We have also held International Ablation Webinar 4 times with 1,271 doctors from 40 countries. The webinars consist of lectures on ablations skills and case studies of difficult to ablate. Although we started the webinars out of necessity, we have found that conducting the webinars have some benefits. Doctors in other cities or countries can easily participate in the webinars without travelling. Moreover, we can spread information to many attendees simultaneously. In addition, even young doctors can attend without mental obstacles. On the other hand, there are some limitations of webinars, for example, it is difficult to measure the understanding of the participants. To overcome that problem, we have introduced voting tools during the webinar.

Even after the COVID-19 pandemic has subsided, the webinars will continue to be an effective communication and educational method. We believe that the webinars would be a useful guide to encourage doctors to join on-site training programs in which they can get skills and knowledge more intensively.

Examination of the Detectability of Spoke Wheel Pattern by Contrast Ultrasonography in FNH

¹Division of Gastroenterology and Hepatology, Department of Medicine, Nihon University School of Medicine

Masahiro Ogawa¹, Toshiki Yamamoto¹, Masahiro Kaneko¹, Yukinobu Watanabe¹, Mildori Hirayama¹, Naoki Matsumoto¹, Tatsuo Kanda¹, Ryota Masuzaki¹, Mitsuhiro Moriyama¹

In diagnosing liver cancer, accurate diagnosis of benign lesions is important to reduce over diagnosis. Focal nodular hyperplasia is the second most common benign hepatic tumor after hepatic hemangiomas, however, distinguishing focal nodular hyperplasia from hepatocellular carcinoma is difficult due to the abundant vascularity of the former. Therefore, detailed examination is occasionally required to achieve accurate diagnosis.

Focal nodular hyperplasia is characterized by a mass lesion with a central scar and abnormal blood vessels, giving rise to a peculiar spoke-wheel pattern. These findings are useful for differentiating focal nodular hyperplasia from hepatocellular carcinoma. Therefore, to determine an appropriate secondary examination method for this disease, we evaluated the presence or absence of the findings of a central scar, tumor stain, and spoke-wheel pattern on ultrasonography and on contrast-enhanced computed tomography (CT) and magnetic resonance imaging (MRI). The detection rates for central scar among ultrasonography and contrast-enhanced CT and MRI and tumor stain among contrast-enhanced ultrasonography and contrast-enhanced CT and MRI were not significantly different. High-sensitivity Doppler imaging was more sensitive compared to contrast-enhanced CT and MRI for detecting the spoke-wheel pattern; furthermore, contrast-enhanced ultrasonography showed the spoke-wheel pattern in all nodules.

In conclusion, contrast-enhanced ultrasonography is useful for a final diagnostic examination of focal nodular hyperplasia lesions.

MWA vs. RFA in Intermediate Stage Hepatocellular Carcinoma: A Retro-prospective Study

¹Cardinal Santos Medical Center, Philippines

Diana Alcantara Babaran¹, Kathryn Louise A Babaran¹, Marco Tongo¹

Local ablative techniques such as Radiofrequency Ablation Therapy (RFA) and Percutaneous Microwave Ablation Therapy (MWA) are accepted techniques in treating patients with Hepatocellular Carcinoma as an alternative to surgery. A retro-prospective review of the outcome of patients who underwent RFA and MWA in treating intermediate (>3 cm) hepatocellular carcinoma (HCC) was done.

23 patients underwent ablation therapy. Complication rate was 2.4% in the RFA group and 2.7% in the MWA group. There were no patient deaths due to treatment.

Improvement in AFP levels were statistically significant in the 1-year follow-up for patients who underwent MWA ($p<0.05$). In addition, there was a statistically significant difference in the bilirubin of patients in the MWA group ($p=0.08$), as well as INR ($p=0.03$).

The statistically significant improvement in the INR and bilirubin, as well as decline in AFP in the MWA group at one-year follow-up indicate benefit among patients with Intermediate-stage Hepatocellular Carcinoma undergoing this treatment. Complication in patients treated with MWA was negligible. Further studies with a larger population are highly recommended for further investigation on the treatment effect of this modality.